

8. Samuel MA, Wang H, Siddharthan V, Morrey JD, Diamond MS. Axonal transport mediates West Nile virus entry into the central nervous system and induces acute flaccid paralysis. *Proc Natl Acad Sci USA*. 2007;104:17140–5.

E. Palacios^{a,b}, C. Clavijo-Prado^{a,*}, A. Ruiz^a,
A. Arias Antun^a, E. Julián Duran^a

^a Grupo de Neurología, Fundación Universitaria de Ciencias de la Salud, Hospital de San José, Bogotá, DC, Colombia

^b Programa de Neurología, Hospital de San José, Bogotá, DC, Colombia

* Corresponding author.

E-mail address: caclavijo@fucsalud.edu.co

(C. Clavijo-Prado).

2173-5808/

© 2016 Sociedad Española de Neurología. Published by Elsevier España, S.L.U. This is an open access article under the CC BY-NC-ND license (<http://creativecommons.org/licenses/by-nc-nd/4.0/>).

Early and recurrent macular oedema in a patient treated with fingolimod[☆]



Edema macular precoz y recurrente en paciente en tratamiento con fingolimod

Dear Editor:

Multiple sclerosis (MS) is a chronic autoimmune disease predominantly affecting young women.¹ Fingolimod is a sphingosine-1-phosphate receptor modulator used to treat

very aggressive or relapsing-remitting forms of MS that are refractory to other types of treatment.²

We present the case of a 56-year-old woman with a 20-year history of MS and no other systemic or ocular diseases. Due to poor control of relapses and the rapid progression of the disease, treatment was started with oral fingolimod (0.5 mg/day). The patient was referred for evaluation at the neuro-ophthalmology department one week later due to blurred vision. The examination determined visual acuity (VA) of 0.6 in the right eye and 0.7 in the left. No alterations were observed in the anterior segment of the eye. Fundus examination revealed mild cystoid macular oedema bilaterally. Optical coherence tomography determined central macular thickness at 480 μm in

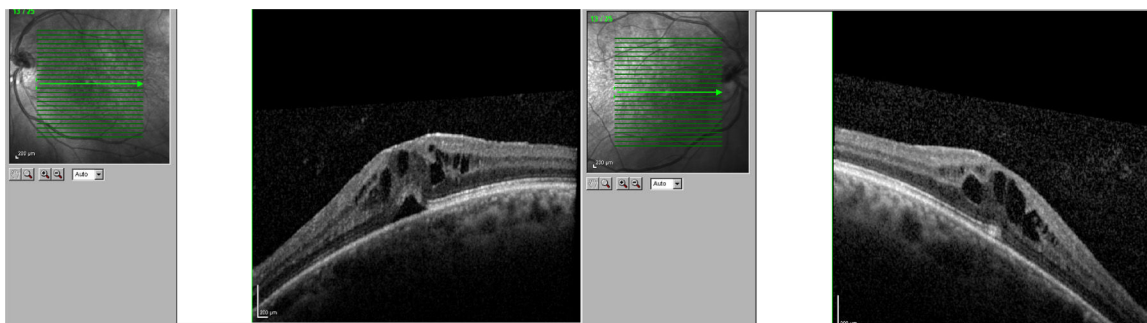


Figure 1 Cystoid macular oedema in the right and the left eyes, one week after onset of treatment with fingolimod.

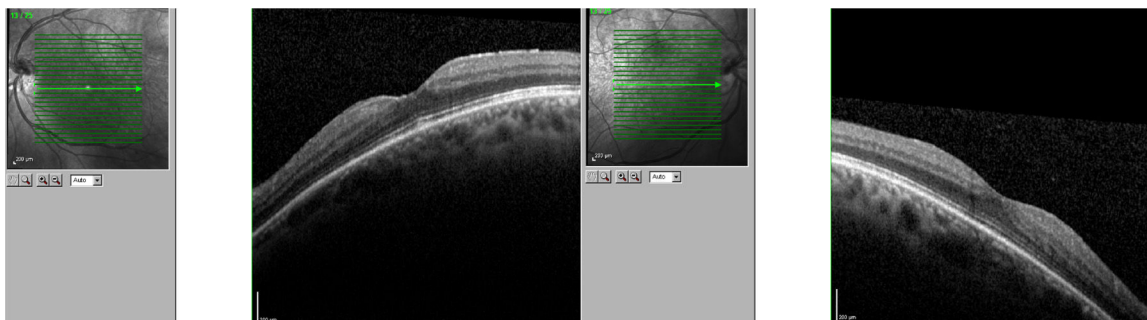


Figure 2 Complete resolution of macular oedema, 20 days after fingolimod was withdrawn.

[☆] Please cite this article as: Cifuentes-Canorea P, Nieves-Moreno M, Sáenz-Francis F, Santos-Bueso E. Edema macular precoz y recurrente en paciente en tratamiento con fingolimod. *Neurología*. 2019;34:206–207.

the right eye and 490 μm in the left (Fig. 1). The patient was transferred to the neurology department, and treatment with fingolimod was withdrawn. At a follow-up visit to the neuro-ophthalmology department 20 days later, the macular oedema had fully resolved in both eyes (Fig. 2), and VA was restored bilaterally. Two months later, fingolimod was reintroduced to control MS. The patient was referred to the neuro-ophthalmology department 10 days later due to reduced VA (right eye: 0.7, left eye: 0.8). Cystoid macular oedema was present in both eyes; central macular thickness was 395 μm in the right eye and 420 μm in the left. Fingolimod was withdrawn once more, and neuro-ophthalmological and optical coherence tomography alterations resolved after a month. The macular oedema was not treated on either occasion; rather, it spontaneously and completely resolved following withdrawal of the drug.

In clinical trials, 0.5% of patients receiving fingolimod displayed macular oedema.³ The summary of product characteristics recommends that patients be evaluated before treatment is started, with an ophthalmological evaluation to be performed at 3-4 months.⁴ Fingolimod can cause vision loss due to macular oedema; this adverse reaction usually resolves following withdrawal of the drug, although cases have been described of visual impairment persisting months after withdrawal. Macular oedema is known to present more frequently in patients with diabetes mellitus and/or a history of uveitis. Our patient had no associated comorbidities; oedema developed less than 7 days after treatment onset. The literature includes other reports of macular oedema developing within 3-4 months of treatment onset,⁵ although not as early as in our patient. We consider it important to begin performing ophthalmological reviews after treatment is started, and to expedite referral of patients at greater risk of macular oedema (patients with diabetes mellitus or history of uveitis) or who report reduced VA or blurred vision.

References

1. Crespo C, Izquierdo G, García-Ruiz A, Granell M, Brosa M. Cost minimisation analysis of fingolimod vs natalizumab as a second line of treatment for relapsing-remitting multiple sclerosis. *Neurologia*. 2014;29:210–7.
2. García-Merino A, Fernández O, Montalbán X, de Andrés C, Oreja-Guevara C, Rodríguez-Antigüedad A, et al., Grupo de Consenso de la Sociedad Española de Neurología. Consensus Statement on medication use in multiple sclerosis by the Spanish Society of Neurology's study group for demyelinating diseases. *Neurologia*. 2013;28:375–8.
3. Jain N, Bhatti MT. Fingolimod-associated macular edema: incidence, detection, and management. *Neurology*. 2012;78:672–80.
4. European Medicines Agency SmPC for Gilenya: EPAR Product Information - Gilenya -EMA/H/C/002202 –PSUV/0023 – Section 44. March 2011. Available from: http://www.ema.europa.eu/docs/en_GB/document_library/EPAR_-_Product_Information/human/002202/WC500104528.pdf [accessed 01.06.16].
5. Asensio-Sánchez VM, Trujillo-Guzmán L, Ramoa-Osorio R. Cystoid macular edema after fingolimod treatment in multiple sclerosis. *Arch Soc Esp Ophthalmol*. 2014;89:104–6.

P. Cifuentes-Canorea*, M. Nieves-Moreno,
F. Sáenz-Francés, E. Santos-Bueso

Unidad de Neurooftalmología, Servicio de Oftalmología, Instituto de Investigación Sanitaria del Hospital Clínico San Carlos (IdISSC), Madrid, Spain

*Corresponding author.

E-mail address: pilarcifuca@gmail.com

(P. Cifuentes-Canorea).

2173-5808/

© 2016 Sociedad Española de Neurología. Published by Elsevier España, S.L.U. This is an open access article under the CC BY-NC-ND license (<http://creativecommons.org/licenses/by-nc-nd/4.0/>).

Atypical paraneoplastic syndrome with no onconeural antibodies: A case report[☆]



Síndrome paraneoplásico atípico sin anticuerpos onconeuronales detectables: a propósito de un caso

Dear Editor:

Paraneoplastic neurological syndromes (PNS) constitute a heterogeneous group of immunopathogenic disorders caused by tumours located outside the nervous system. Before

the diagnosis is established, we must rule out neurological complications resulting directly from the tumour or its treatment.¹ From a pathophysiological perspective, PNS are explained by the presence of common antigens in tumour cells and in some structures of the nervous system, with the result that the antitumour immune response also affects healthy cells.^{2,3} According to the PNS diagnostic criteria, detection of both the onconeural antibodies and the primary tumour are 2 of the most useful factors when establishing diagnosis. However, not all patients present circulating antibodies⁴: these may go undetected in up to 50% of patients,⁵ as in our case.

Our patient is a 68-year-old woman who presented progressive dyspnoea associated with pulmonary thromboembolism and deep vein thrombosis, as well as confusional syndrome and secondarily generalised partial seizures. After a 2-month improvement period, she once again presented confusional syndrome, gait ataxia, and recurrent seizures leading to status epilepticus.

The blood analysis displayed normal results (including thyroid and parathyroid hormone levels, vitamins, folic acid, CEA, and Ca 15.3); results for angiotensin-converting

[☆] Please cite this article as: Casas Peña E, Martín Santidrián MA, González Fernández J, Castrillo Fraile MV. Síndrome paraneoplásico atípico sin anticuerpos onconeuronales detectables: a propósito de un caso. *Neurología*. 2019;34:207–209.