

## New variant associated with Niemann-Pick disease type C: neurological manifestations and biochemical, molecular, and cellular characterisation<sup>☆</sup>



### Nueva variante asociada a enfermedad de Niemann-Pick tipo C: manifestaciones neurológicas y caracterización bioquímica, molecular y celular

Dear Editor:

Niemann-Pick disease type C (NPC; MIM #257220 and MIM #607625) is caused by an inborn error of metabolism and follows an autosomal recessive inheritance pattern. The disease is characterised by an alteration to intracellular cholesterol transport, causing lysosomal and/or late endosomal accumulation of several metabolites.<sup>1,2</sup> The causal genes are *NPC1* (MIM \*607623) and *NPC2* (MIM \*607625). *NPC1* accounts for 95% of published cases, with *NPC2* covering 4%.<sup>3</sup>

Diagnosis is challenging due to the great clinical heterogeneity of the condition and the difficulty of laboratory testing. Symptoms are generally classified into 3 broad groups: visceral, neurological, and psychiatric. The most frequent symptoms are splenomegaly, vertical gaze palsy, and cataplexy.<sup>3</sup> A screening tool based on clinical manifestations (the NPC Suspicion Index) has been created to guide diagnosis; the tool assigns a score reflecting the risk of NPC and the suitability of additional studies to clarify the diagnosis.<sup>4,5</sup>

We present the case of a 26-year-old woman of Berber origin; she had history of intellectual disability and

psychotic disorder, for which she was receiving olanzapine 5 mg. She was referred to our centre due to abnormal movement and gait alterations of less than one year's progression. The neurological examination revealed dysarthria, hypomimia, vertical gaze palsy, global bradykinesia with isolated distal myoclonus, and mild ataxic gait without arm swing. Brain MRI and DaTSCAN<sup>®</sup> revealed no relevant abnormalities. The ophthalmic examination revealed cherry-red spots on both maculae. Abdominal ultrasound detected splenomegaly (13.8 cm). The patient scored 104 on the NPC suspicion index (64th percentile).

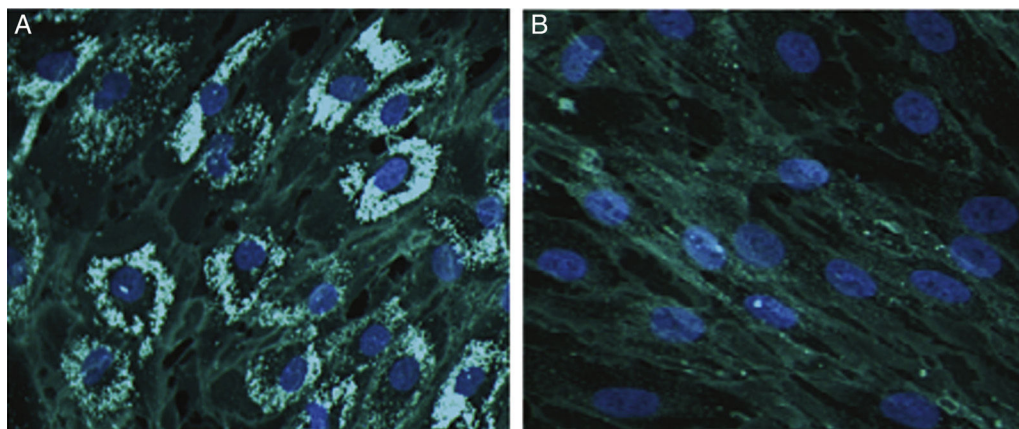
To confirm the diagnosis, we tested plasma chitotriosidase activity<sup>6</sup> and concentrations of the chemokine CCL18 (PARC)<sup>7</sup> and 7-ketocholesterol (7-CC)<sup>8–10</sup> using methods described elsewhere. All 3 biomarkers were above the intra-laboratory reference limit.

Sequencing of *NPC1* and *NPC2* was performed according to the Sanger method with small modifications to the protocol published by Zech's study group, identifying 2 variants in *NPC1*: p.Ile1061Thr (previously described by Yamamoto et al.<sup>11</sup>) and p.Val856Ala (not previously described).

Cholesterol accumulation in fibroblasts was analysed with cytochemical staining using Filipin III (Sigma-Aldrich; Spain)<sup>12</sup>; 70% of fibroblasts were positive for cholesterol accumulation (Fig. 1).

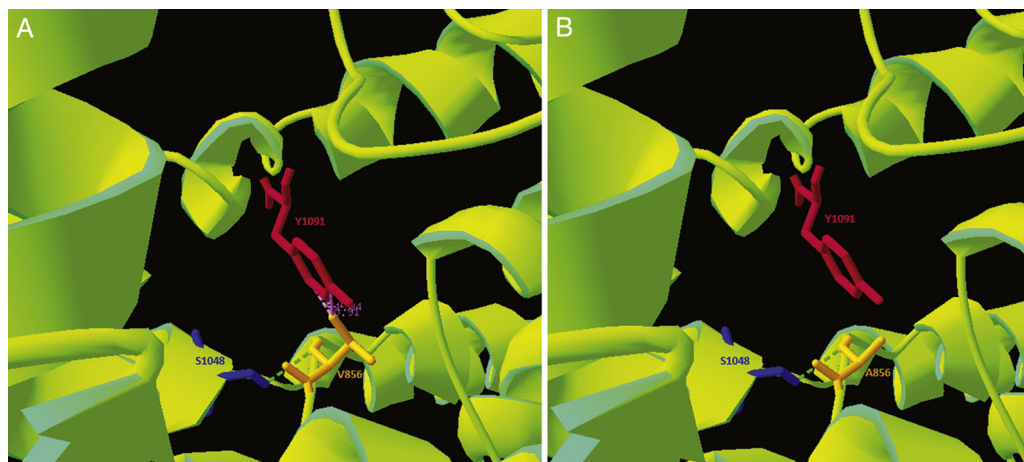
To rule out other lysosomal conditions of the same metabolic pathway, we studied lysosomal acid lipase<sup>13</sup> and sphingomyelinase<sup>14</sup> activity in lysate from leukocytes; results were within the intra-laboratory reference limits.

As the p.Val856Ala variant had not previously been described, and given its location in a cysteine-rich loop that accounts for approximately one-third of the described pathogenic variants,<sup>1</sup> we performed an in silico analysis of the mutation. Clustal Omega was used to run a sequence conservation analysis, with comparison against 30 species, revealing that the region is highly conserved. Simultane-



**Figure 1** Representative images from Filipin III cholesterol staining of fibroblasts from our patient (A) and a control (B). Cells were cultured for 72 hours on a coverslip in lipoprotein-free medium and then for 24 hours in a medium rich in low-density lipoproteins. They were subsequently fixed and stained with Filipin III. 200 $\times$  magnification.

<sup>☆</sup> Please cite this article as: López de Frutos L, Romero-Imbroda J, Rodríguez-Sureda V, Giraldo P. Nueva variante asociada a enfermedad de Niemann-Pick tipo C: manifestaciones neurológicas y caracterización bioquímica, molecular y celular. *Neurología*. 2020;35:50–52.



**Figure 2** Structural alterations in the NPC1 protein. Interactions between the Ser1048, Tyr1091, and Val856 (A) or Ala856 (B) amino acids. Images generated using the 3JD8 sequence (PDB) on the Swiss-PdbViewer software.

ously, we used the NPC1 structure published on Protein Data Bank by Gong and colleagues in 2016 (Cryo-EM structure of the full-length human NPC1 at 4.4 angstrom; PDB access number: 3JD8) and modelled the pathogenic variant with the free software application Swiss-PdbViewer, revealing reduced electrostatic interactions in the variant form (Fig. 2). The DUET stability predictor detected reduced stability in the protein containing the p.Val856Ala variant ( $\Delta\Delta G$ :  $-1.457$  vs  $\Delta\Delta G$ :  $0$  kcal/mol). According to the guidelines of the American College of Medical Genetics,<sup>15</sup> this variant would be catalogued as “likely pathogenic.”

The clinical, biochemical, molecular, and cellular findings from our patient suggest that she has NPC due to compound heterozygosity of the p.Ile1061Thr variant and the previously undescribed p.Val856Ala variant.

## Acknowledgements

The authors are grateful to María Teresa Sagrario Fustero, Clementina del Canto Pérez, and Adolfo Mínguez-Castellanos for their help in the clinical diagnosis of the patient, and to Jorge J. Cebolla, Pilar Irún, and Carmen Domínguez for their invaluable contribution in laboratory testing.

## References

1. Vanier MT, Gissen P, Bauer P, Coll MJ, Burlina A, Hendriksz CJ, et al. Diagnostic tests for Niemann-Pick disease type C (NP-C): a critical review. *Mol Genet Metab.* 2016;118:244–5254, <http://dx.doi.org/10.1016/j.ymgme.2016.06.004>.
2. Lloyd-Evans E, Platt FM. Lipids on trial: the search for the offending metabolite in Niemann-Pick type C disease. *Traffic.* 2010;2:419–28, <http://dx.doi.org/10.1111/j.1600-0854.2010.01032.x>.
3. Vanier MT. Niemann-Pick disease type C. *Orphanet J Rare Dis.* 2010;5:16.
4. Hendriksz CJ, Pineda M, Fahey M, Walterfang M, Stampfer M, Runz H, et al. The Niemann-Pick disease type C suspicion index: development of a new tool to aid diagnosis. *J Rare Disord Diagnosis Ther.* 2015;1:1.
5. Pineda M, Mengel E, Jahnová H, Héron B, Imrie J, Lourenço CM, et al. A Suspicion Index to aid screening of early-onset Niemann-Pick disease Type C (NP-C). *BMC Pediatr.* 2016;16:107, <http://dx.doi.org/10.1186/s12887-016-0641-7>.
6. Hollak CEM, van Weely S, van Oers MHJ, Aerts JMFG. Marked elevation of plasma chitotriosidase activity. A novel hallmark of Gaucher disease. *J Clin Invest.* 1994;93:1288–92.
7. Boot RG, Verhoek M, De Fost M, Hollak CEM, Maas M, Bleijlevens B, et al. Marked elevation of the chemokine CCL18/PARC in Gaucher disease: a novel surrogate marker for assessing therapeutic intervention. *Blood.* 2004;103:33–40, <http://dx.doi.org/10.1182/blood-2003-05-1612> [reprints].
8. Lin N, Zhang H, Qiu W, Ye J, Han L, Wang Y, et al. Determination of 7-ketocholesterol in plasma by LC–MS for rapid diagnosis of acid SMase-deficient Niemann-Pick disease. *J Lipid Res.* 2014;55:338–43, <http://dx.doi.org/10.1194/jlr.D044024>.
9. Baila-Rueda L, Cenarro A, Barcelo-Batllori S, Pocoví M, Ros E, Civeira F, et al. Simultaneous determination of oxysterols, phytosterols and cholesterol precursors by high performance liquid chromatography tandem mass spectrometry in human serum. *Anal Methods.* 2013;5:2249–57, <http://dx.doi.org/10.1039/C3AY26395A>.
10. Cebolla J, de Castro-Orós I, Irún P, Alfonso P, López de Frutos L, Andrade-Campos M, et al. Experience with 7-ketocholesterol and ccl18/parc as surrogated biomarkers in a series of Spanish Niemann-Pick disease type C patients. *Mol Genet Metab.* 2015;114:S29.
11. Yamamoto T, Ninomiya H, Matsumoto M, Ohta Y, Nanba E, Tsutsumi Y, et al. Genotype–phenotype relationship of NPC: a possible correlation between clinical onset and levels of NPC1 protein in isolated skin fibroblasts. *J Med Genet.* 2000;37:707–11.
12. Vanier MT, Latour P. Laboratory diagnosis of Niemann-Pick disease type C: the filipin staining test. *Methods Cell Biol.* 2015;126:357–75.
13. Hamilton J, Jones I, Srivastava R, Galloway P. A new method for the measurement of lysosomal acid lipase in dried blood spots using the inhibitor Lalistat 2. *Clin Chim Acta.* 2012;413:1207–10, <http://dx.doi.org/10.1016/j.cca.2012.03.019>.
14. Van Diggelen OP, Voznyi YV, Keulemans JLM, Schoonderwoerd K, Ledvinova J, Mengel E, et al. A new fluorimetric enzyme assay for the diagnosis of Niemann-Pick A/B, with specificity of natural sphingomyelinase substrate. *J Inher Metab Dis.* 2005;28:733–41, <http://dx.doi.org/10.1007/s10545-005-0105-y>.

15. Richards S, Aziz N, Bale S, Bick D, Das S, Gastier-Foster J, et al. Standards and guidelines for the interpretation of sequence variants: a joint consensus recommendation of the American College of Medical Genetics and Genomics and the Association for Molecular Pathology. *Genet Med.* 2015;17:405–24. <http://dx.doi.org/10.1038/gim.2015.30>.

L. López de Frutos<sup>a,\*</sup>, J. Romero-Imbroda<sup>b</sup>,  
V. Rodríguez-Sureda<sup>c</sup>, P. Giraldo<sup>d</sup>

<sup>a</sup> Instituto de Investigación Sanitaria Aragón (IIS Aragón),  
Unidad de Investigación Traslacional, Hospital  
Universitario Miguel Servet, Zaragoza, Spain

<sup>b</sup> Servicio de Neurología, Hospital Comarcal de Melilla,  
Melilla, Spain

<sup>c</sup> Centro de Investigación Biomédica en Red en  
Enfermedades Raras (CIBERER), Centro de Investigaciones

en Bioquímica y Biología Molecular-Nanomedicina, Institut  
de Recerca Hospital Vall d'Hebrón, Barcelona, Spain  
<sup>d</sup> Centro de Investigación Biomédica en Red en  
Enfermedades Raras (CIBERER), Unidad de Investigación  
Traslacional, Hospital Universitario Miguel Servet,  
Zaragoza, Spain

\* Corresponding author.

E-mail address: [llopezdefrutos.uit@gmail.com](mailto:llopezdefrutos.uit@gmail.com)

(L. López de Frutos).

<https://doi.org/10.1016/j.nrleng.2017.07.002>

2173-5808/

© 2017 Sociedad Española de Neurología. Published by Elsevier  
España, S.L.U. This is an open access article under the CC  
BY-NC-ND license (<http://creativecommons.org/licenses/by-nc-nd/4.0/>).

## Endovascular treatment of arterial ischaemic stroke in paediatric patients: a case report<sup>☆,☆☆</sup>



## Tratamiento endovascular del ictus isquémico arterial en edad pediátrica: a propósito de un caso

Dear Editor:

Arterial ischaemic stroke is rare in paediatric patients.<sup>1</sup> Nonetheless, it is considered an important cause of disability and mortality in this age group.<sup>2</sup> Stroke aetiology in children is generally different from that observed in adult patients.<sup>3</sup> Acquired and congenital heart defects are one of the main risk factors for paediatric ischaemic stroke.<sup>4</sup>

For a number of reasons, paediatric stroke is associated with a considerable diagnostic delay,<sup>5</sup> which together with its low prevalence represents an obstacle to performing randomised trials with patients in the acute phase.

We present the case of a 13-year-old patient diagnosed at birth with complete atrioventricular canal, for which she had undergone several surgical interventions during childhood. Due to a prosthetic mitral valve implanted in one of these procedures, she was receiving anticoagulation therapy with acenocoumarol; she had recently been included in an INR self-monitoring programme.

The patient attended our centre due to right hemisphere deficit syndrome of 45 minutes' progression. In the initial examination at the emergency department, she scored 18 on the NIHSS, with electrocardiography displaying sinus

rhythm, and an INR (measured with a CoaguChek<sup>®</sup> system) of 1.3.

A baseline head CT scan performed 15 minutes after arrival scored 9 on the ASPECTS scale; CT angiography revealed tandem occlusion of the proximal right internal carotid artery and the M1 segment of the right middle cerebral artery.

Given the patient's age and the evidence of large-artery occlusion of short progression, we opted for primary endovascular treatment. Primary thrombectomy was performed with a door-to-groin puncture time of 97 minutes. Revascularisation was achieved with 2 passes with a stent retriever, with a final score of 2b on the TICI scale (Fig. 1).

Four hours after the intervention, a head CT scan showed mild contrast enhancement in the basal ganglia and the right Sylvian fissure. Three months after the ischaemic event, the patient presented mild paresis of the left hand, scoring 1 on the modified Rankin Scale.

The treatment of acute stroke in paediatric patients has been subject to discussion in recent years.

The Thrombolysis in Paediatric Stroke study was closed in 2015 due to lack of recruitment, denying us indicative results on the efficacy and safety of this treatment.<sup>6</sup>

The revised American Heart Association/American Stroke Association guidelines on the early management of acute ischaemic stroke with endovascular treatment,<sup>7</sup> published the same year, deem this treatment a reasonable course of action in patients younger than 18 provided that they present symptoms of less than 6 hours' progression and evidence of large-vessel occlusion (grade of recommendation 2b, level of evidence C).

Until recently, the only evidence supporting endovascular treatment in paediatric patients was based on case reports and literature reviews, with the considerable publication bias this entails.<sup>8</sup> However, the journal *Paediatric Neurology* recently published the first retrospective population study performed in the United States, with a cohort of 3184 paediatric patients with arterial ischaemic stroke. Only 1% of the sample received endovascular treatment; while these were the patients with the most severe symptoms, they did not present poorer prognosis than did patients not receiving this treatment.<sup>9</sup>

<sup>☆</sup> Please cite this article as: Serra Martínez M, Avellaneda-Gómez C, Cayuela Caudevilla N, Rodríguez Campello A. Tratamiento endovascular del ictus isquémico arterial en edad pediátrica: a propósito de un caso. *Neurología.* 2020;35:52–54.

<sup>☆☆</sup> This study was presented in poster format at the 21st Annual Meeting of the Catalan Society of Neurology.