

Congenital left ventricular outpouching and patent foramen ovale: a potentially emboligenic combination[☆]



Evaginación ventricular izquierda congénita y foramen oval permeable: una combinación potencialmente embolígena

Dear Editor:

Congenital left ventricular aneurysm or diverticulum, recently brought together with the term left ventricular outpouchings (LVO), are infrequent heart defects that can cause embolic phenomena. Although they usually present in isolation, LVOs are sometimes associated with such other defects as patent foramen ovale (PFO).

We present the case of a 39-year-old woman, a former smoker previously diagnosed with migraine with visual aura, who attended our emergency department due to difficulty speaking of sudden onset, with no other associated symptom. Physical examination revealed motor aphasia, with normal results in the neurological examination. An electrocardiogram showed sinus rhythm at 72 bpm with no alterations; a CT angiography of the brain and aortic trunks revealed millimetric hypointense foci in the cerebellum, compatible with older strokes; no other anomalies were detected. The patient was admitted to the stroke unit, and clinical symptoms completely resolved approximately 2 hours after onset. A Doppler ultrasonography of the supra-aortic trunks showed normal findings, and a brain MRI scan confirmed the presence of older small cerebellar infarcts, with no alterations on diffusion sequences. A transthoracic echocardiogram revealed a protrusion of the inferobasal wall of the left ventricle (Fig. 1A) and the presence of PFO after injection of agitated saline solution

(Fig. 1B). We also performed a CT angiography of the coronary arteries, which ruled out atherosclerotic disease; a cardiac MRI scan confirmed the presence of the anomaly observed in the transthoracic echocardiogram, connected to the ventricular cavity by a wide neck; wall thickness and contractility (Fig. 2A-B) were normal, and no late gadolinium uptake was observed (Fig. 2C). Approximately 90 minutes after symptom onset, the patient fully recovered the ability to speak, remaining asymptomatic during hospitalisation. The case was discussed in a multidisciplinary meeting where we decided to adopt a conservative approach, prescribing oral anticoagulant treatment (acenocoumarol at doses adjusted by the haematology department) and outpatient follow-up.

Congenital left ventricular aneurysm and diverticulum are rare primary heart defects first described in 1816. They may be associated with other cardiac, vascular, and thoracoabdominal malformations; very pronounced cases are part of the pentalogy of Cantrell.¹ Two entities have classically been differentiated: aneurysm, defined as an akinetic or dyskinetic protrusion of the ventricular wall with a neck diameter/maximum diameter ratio >1; and diverticulum, characterised by normal contractility and a ratio <1.² Although this differentiation may seem simple, the literature includes multiple unclear examples, and the terms are even used interchangeably. Therefore, in 2014, Malakan Rad et al.³ developed a new classification aimed at standardising these definitions. Under the common term LVO, they described 4 types of malformations (I, IIa, IIb, and IIc), classified according to the thickness and contractility of the walls.³ LVOs are usually diagnosed incidentally by imaging studies requested for another reason, with symptoms including those secondary to embolic phenomena or heart rate alterations.⁴

Our patient presented isolated motor aphasia, a frequent manifestation of cardioembolic stroke⁵; complementary studies revealed an LVO. After ruling out coronary artery disease, we concluded that this finding corresponds to a congenital malformation. After analysing its anatomi-

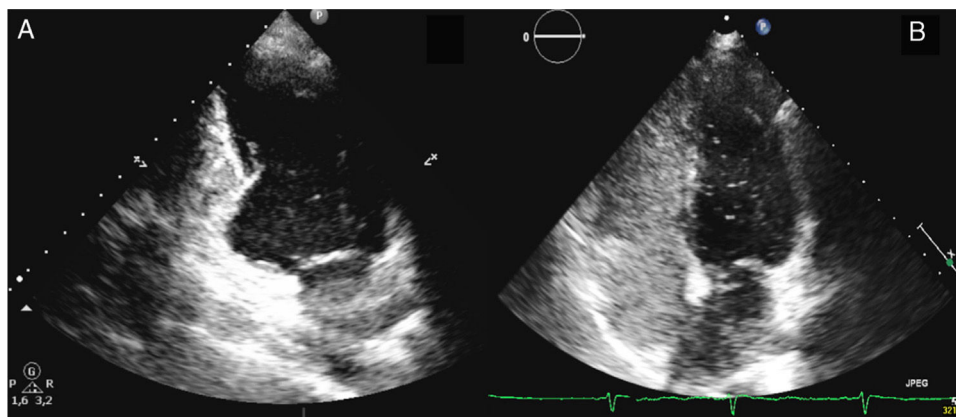


Fig. 1 Transthoracic echocardiogram. A) Two-chamber view showing a congenital left ventricular outpouching in the inferobasal wall. B) Right-to-left shunt was demonstrated by the passage of bubbles after the injection of agitated saline solution.

[☆] Please cite this article as: Lapeña-Reguero M, et al. Evaginación ventricular izquierda congénita y foramen oval permeable: una combinación potencialmente embolígena. *Neurología*. 2020;35:334–335.

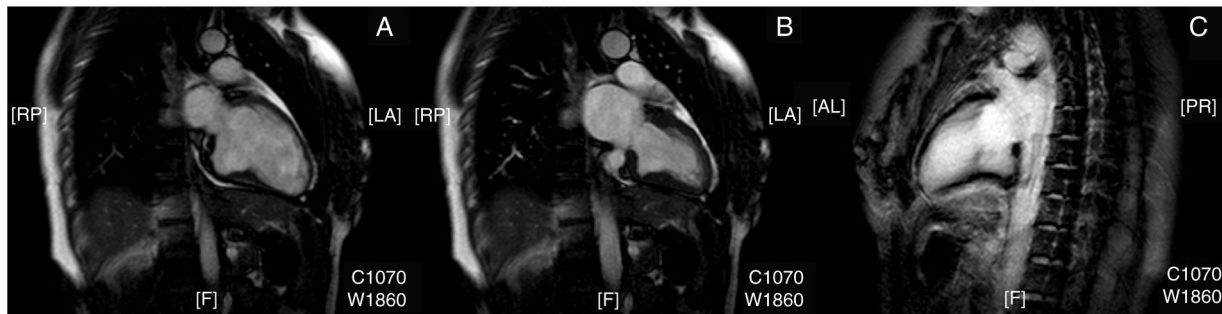


Fig. 2 Magnetic resonance imaging study. Two-chamber end-diastolic (A) and end-systolic (B) views showing the normal contractility of the anomaly. (C) Absence of late gadolinium contrast uptake.

cal characteristics, the lesion is difficult to classify as an aneurysm or a diverticulum following classical criteria, as it presents a neck diameter/maximum diameter ratio >1 (compatible with the first) and normal wall thickness and contractility (suggestive of the second). However, it could be considered a type I LVO according to the Malakan Rad et al.³ classification; therefore, we believe that using this classification may help in homogenising the terms used in reference to these malformations. Furthermore, our patient presented PFO, an association which is not frequently documented in the literature (1% of cases of LVO).⁴ Copresence of both entities makes it difficult to ascertain the cause of the cerebral ischaemic events. On the one hand, the association of PFO with cryptogenic stroke in young patients seems to be increasingly documented, with some authors estimating it to be 5 times more likely in this patient group than in the general population.⁶ On the other hand, although LVOs usually progress asymptotically and are diagnosed incidentally, the number of reported cases of these anomalies associated with stroke is increasing;⁷ however, this association remains exceptional, as demonstrated by the absence of LVO as the aetiology of cardioembolic stroke in a consecutive series of 402 patients.⁸ Therefore, and given the controversy regarding treatment of these entities in isolation, we opted to implement oral anticoagulant treatment and outpatient follow-up, with other treatment alternatives such as isolated surgical resection of the LVO or surgical closure of the PFO reserved for the potential case of symptom recurrence.

References

1. Cantrell JR, Haller JA, Ravitch MM. A syndrome of congenital defects involving the abdominal wall, sternum, diaphragm, pericardium, and heart. *Surg Gynecol Obstet.* 1958;107:602–14.
2. Ohlow MA. Congenital left ventricular aneurysms and diverticula: definition, pathophysiology, clinical relevance and treatment. *Cardiology.* 2006;106:63–72.
3. Malakan Rad E, Awad S, Hijazi ZM. Congenital left ventricular outpouchings: a systematic review of 839 cases and introduction of a novel classification after two centuries. *Congenit Heart Dis.* 2014;9:498–511.
4. Ohlow MA, von Korn H, Lauer B. Characteristics and outcome of congenital left ventricular aneurysm and diverticulum: analysis of 809 cases published since 1816. *Int J Cardiol.* 2015;185:34–45.
5. Arbois A, Alió J. Acute cardioembolic stroke: an update. *Expert Rev Cardiovasc Ther.* 2011;9:367–79.
6. Alsheikh-Ali AA, Thaler DE, Kent DM. Patent foramen ovale in cryptogenic stroke: incidental or pathogenic? *Stroke.* 2009;40:2349–55.
7. Gaillard N, Targosz F, Bertrand JL, Sablot D, Bensalah ZM. Recurrent cryptogenic stroke in young adult linked to congenital left ventricular diverticulum. *Neurology.* 2016;87:2169–70.
8. Pujadas Capmany R, Arboix A, Casañas-Muñoz R, Anguera-Ferrando N. Specific cardiac disorders in 402 consecutive patients with ischaemic cardioembolic stroke. *Int J Cardiol.* 2004;95(2–3):129–34.

M. Lapeña-Reguero^a, R. Fábregas-Casal^a,
M.D. Fernández-Couto^b, G. Barge-Caballero^{a,c,d,*}

^a *Servicio de Cardiología, Complejo Hospitalario Universitario A Coruña, A Coruña, Spain*

^b *Servicio de Neurología, Complejo Hospitalario Universitario A Coruña, A Coruña, Spain*

^c *Centro de Investigación Biomédica en Red (CIBERCV), Instituto de Salud Carlos III, Madrid, Spain*

^d *Instituto de Investigación Biomédica de A Coruña (INIBIC), A Coruña, Spain*

* Corresponding author.

E-mail address: gonzalo.barge.caballero@sergas.es (G. Barge-Caballero).

13 September 2017

<https://doi.org/10.1016/j.nrleng.2018.02.003>
2173-5808/

© 2018 Sociedad Española de Neurología. Published by Elsevier España, S.L.U. This is an open access article under the CC BY-NC-ND license (<http://creativecommons.org/licenses/by-nc-nd/4.0/>).