

R. Cuenca Hernández\*, A. Esquivel Lopez, R. Gordo Mañas, D. Hípola González

*Servicio de Neurología, Hospital Infanta Leonor, Madrid, Spain*

\* Corresponding author.

E-mail address: [rcuencah@gmail.com](mailto:rcuencah@gmail.com)  
(R. Cuenca Hernández).

<https://doi.org/10.1016/j.nrleng.2017.07.013>  
2173-5808/

© 2017 Sociedad Española de Neurología. Published by Elsevier España, S.L.U. This is an open access article under the CC BY-NC-ND license (<http://creativecommons.org/licenses/by-nc-nd/4.0/>).

## Subclavian steal syndrome: A forgotten aetiology of acute cerebral ischaemia<sup>☆</sup>



### Síndrome del robo de la subclavia. Una causa olvidada de isquemia cerebral aguda

*Dear Editor:*

Subclavian steal syndrome refers to subclavian artery stenosis before the origin of the vertebral artery, mainly due to the appearance of atheromatous plaques, which causes a retrograde flow in the ipsilateral vertebral artery together with transient neurological symptoms secondary to ischaemia in the affected territory.<sup>1</sup>

Its prevalence ranges from 0.6% to 6.4% in the general population.<sup>2</sup> It is more frequent in men (ratio of 2:1), with the exception of cases secondary to Takayasu arteritis, in which women are more commonly affected. The left subclavian artery is more frequently involved, with a ratio of 4:1.

We present the case of a 70-year-old man with a history of arterial hypertension controlled with calcium channel blockers, angiotensin II receptor blockers, and thiazide; and type 2 diabetes mellitus treated with oral anti-diabetic drugs. The patient was admitted to the neurology department due to symptoms of central vertigo and gait ataxia of 48 hours' progression.

The physical examination revealed marked asymmetry when arterial blood pressure (BP) was measured simultaneously in both arms. The mean BP calculated from 3 measurements was 100/70 mm Hg in the right arm and 148/97 mm Hg in the left. Heart sounds were regular and no heart or carotid murmur was heard. The radial pulse was less easily felt in the left wrist than in the right. The neurological examination revealed vertical nystagmus, gait ataxia, and moderate dysarthria. During the targeted interview, the patient reported frequent left arm pain of several months' progression.

A head CT scan revealed no signs of acute ischaemia; a brain MRI confirmed an acute vertebrobasilar stroke. A Doppler ultrasonography of the supra-aortic trunks showed a biphasic pattern in the left subclavian artery, compati-

ble with subclavian steal syndrome (grade 2). Examination of the basilar artery through the transforaminal window revealed inverted flow at a depth of 80 mm in the left vertebral artery and reduced flow speed in both posterior cerebral arteries.

An MRI-angiography revealed severe stenosis of approximately 5 mm in diameter in the left subclavian artery, proximal to the origin of the homolateral vertebral artery; images were suggestive of retrograde flow in the left vertebral artery, which was permeable in a contrast study. These findings are compatible with subclavian steal syndrome (Fig. 1).

Considering a diagnosis of acute vertebrobasilar ischaemia secondary to subclavian steal syndrome, we opted for endovascular treatment, placing a stent in the left prevertebral subclavian artery. A subsequent angiography confirmed that flow was adequate and no complications were observed. A one-month follow-up Doppler ultrasonography of the supra-aortic trunks and BP measurement in both arms revealed a significant reduction in the BP asymmetry: mean BP was 135/77 mm Hg in the right arm and 145/76 mm Hg in the left. The patient presented no new neurological events and the systematic examination revealed minimal residual ataxia, no vertigo signs, and remission of the left arm pain.

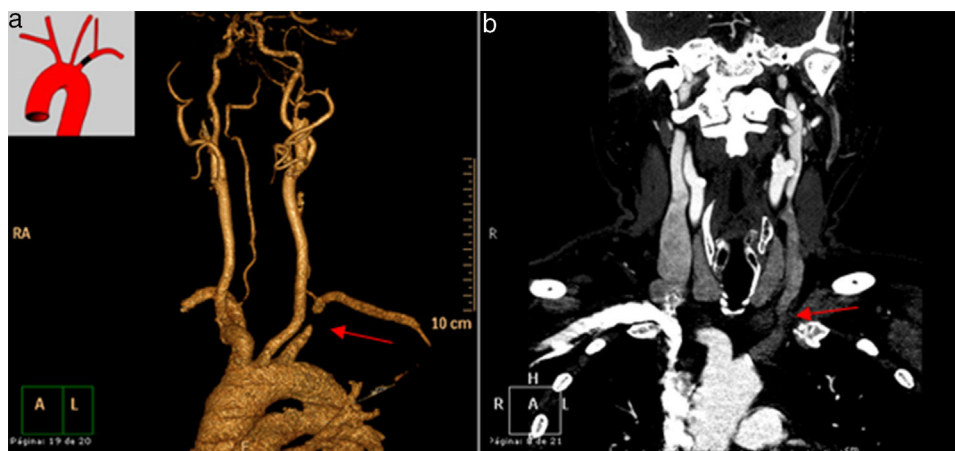
The most frequent aetiology in subclavian steal syndrome is atherosclerosis, followed in order of frequency by vasculitis, temporal arteritis, and embryonic malformation of the aortic arch and supra-aortic trunks.

Stenosis of the subclavian artery provokes a compensatory increase in flow in the contralateral vessels (which is responsible for the presence of a retrograde flow from the vertebral artery) to ensure adequate blood supply and improve perfusion in the affected territory.<sup>2</sup> Vertebrobasilar insufficiency is infrequent, except in the event of a lesion affecting the contralateral vertebral artery or innominate artery stenosis.<sup>3</sup>

Only 5% of patients with subclavian steal syndrome develop neurological symptoms. Most patients present proximal stenosis of the subclavian artery, compromising circulation to the posterior cerebral artery territory, specifically the V4 segment, which supplies the brainstem and cerebellum. Clinical symptoms typically include vertigo, ataxia, dysarthria, syncope, diplopia, and monocular or binocular vision impairment.<sup>4</sup>

Arterial occlusion only occurs distally in rare cases, with the predominant symptom being claudication of the affected limb. Physical examination reveals asymmetric radial pulses, with a difference in BP of > 20 mm Hg between arms; supraclavicular auscultation may reveal artery bruit, depending on the degree of stenosis.<sup>5</sup>

<sup>☆</sup> Please cite this article as: Antón Vázquez V, Armario García P, García Sánchez SM, Martí Castillejos C. Síndrome del robo de la subclavia. Una causa olvidada de isquemia cerebral aguda. *Neurología*. 2020;35:65–67.



**Figure 1** (a) MRI angiography of the thoracic aorta rendering reconstructions and (b) chest MRI angiography showing complete obstruction of the proximal third of the left subclavian artery, with contrast uptake in the post-stenotic area through the left vertebral artery.

There are 4 types of subclavian steal syndrome, depending on ultrasound findings: type 1, proximal stenosis of the subclavian artery or brachiocephalic trunk; type 2, severe proximal stenosis of the subclavian artery; type 3, antegrade flow from the vertebral artery at rest; and type 4, antegrade flow from the subclavian artery.<sup>6</sup>

Diagnosis of vertebral subclavian steal syndrome is initially established if flow inversion in the vertebral artery is observed in a Doppler ultrasound study in patients with clinical suspicion. The study should be completed with a CT scan, MRI angiography, and arteriographic study,<sup>7</sup> in order to locate the lesion precisely and assess treatment options. If vertebral subclavian steal syndrome is suspected, we should rule out such other causes as arrhythmias, poorly controlled hypertension, or pacemaker malfunction.<sup>8</sup>

Indications for revascularisation are presence of symptoms of vertebrobasilar ischaemia, or severe extracranial atherosclerotic disease. The aim of treatment is to restore antegrade flow in the vertebral artery in order to improve the cerebral hypoperfusion.

Endovascular treatment of the lesions to the prevertebral subclavian artery is the treatment of choice, presenting a high success rate, minimal complications, and a low mortality rate.<sup>9</sup> This technique offers greater long-term permeability when revascularisation is indicated due to symptoms of vertebrobasilar ischaemia than when it is indicated due to upper limb ischaemia.<sup>10</sup>

Follow-up with Doppler ultrasound is very important in patients undergoing endovascular therapy in order to ensure the permeability of the stent.<sup>11</sup>

In addition to the invasive revascularisation treatment, we should not forget the importance of adequately controlling cardiovascular risk in these patients by closely monitoring and controlling BP, lipid profile, and anticoagulant treatment, given the reported association between coronary and peripheral artery disease.<sup>12</sup>

Our case illustrates the challenge of diagnosing subclavian steal syndrome as the cause of acute brain ischaemia. We stress the importance of simultaneously measuring BP in both arms; this should be performed routinely in all hypertensive patients as it is essential in the early diagnosis of the disease.

## References

- Potter BJ, Pinto DS. Subclavian steal syndrome. *Circulation*. 2014;129:2320.
- Labropoulos N, Nandivada P, Bekelis K. Prevalence and impact of the subclavian steal syndrome. *Ann Surg*. 2010;252:166–70.
- Osiro S, Zurada A, Gielecki J, Shoja MM, Tubbs RS, Loukas M. A review of subclavian steal syndrome with clinical correlation. *Med Sci Monit*. 2012;18:RA57–63.
- Shadman R, Criqui MH, Bundens WP, Fronek A, Denenberg JO, Gamst CA, et al. Subclavian artery stenosis: prevalence, risk factors, and association with cardiovascular diseases. *J Am Coll Cardiol*. 2004;44:618–23.
- Clark CE, Rod-Taylor S, Shore CA, Ukoumunne OC, Campbell LL. Association of a difference in systolic blood pressure between arms with vascular disease and mortality: a systematic review and meta-analysis. *Lancet*. 2012;379:905–14.
- Kotval PS, Sateesh CH, Shah PM. Doppler diagnosis of partial vertebral-subclavian steals convertible to full steals with physiologic maneuvers. *J Ultrasound Med*. 1990;9:207–13.
- Wu C, Zhang J, Ladner CJ, Babb JS, Lamparello PJ, Krinsky GA. Subclavian steal syndrome: diagnosis with perfusion metrics from contrast-enhanced MR angiographic bolus-timing examination – initial experience. *Radiology*. 2005;235:927–33.
- Pilo-De la Fuente B, Masjuán-Vallejo J, Toledano-Delgado R, Gilo-Arrojo F, García-Barragán N, Blázquez J, et al. Tratamiento endovascular del síndrome del robo de la subclavia sintomático. *Rev Neurol*. 2006;42:57–8.
- AbuRahma AF, Bates MC, Stone PA, Dyer B, Armistead L, Scott Dean L, et al. Angioplasty and stenting versus carotid subclavian bypass for the treatment of isolated subclavian artery disease. *J Endovasc Ther*. 2007;14:698–704.
- Linni K, Ugurluoglu A, Mader N, Hitzl W, Magometschnigg H, Hölzenbein T.J. Endovascular management versus surgery for proximal subclavian artery lesions. *Ann Vasc Surg*. 2008;22:769–75.
- Sixt S, Rastan A, Schwarzwälder U, Bürgelin K, Noory E, Schwarz T, et al. Results after balloon angioplasty or stenting. *Catheter Cardiovasc Interv*. 2009;73:395–403.
- Miranda G, Zarca MA, Mora C, Sánchez MD, Ferreras I, Rivera F. Estenosis de arteria subclavia: importancia de medir la presión arterial en ambas extremidades y su asociación con el riesgo cardiovascular. *Hipertenso Riesgo Vasc*. 2014;31:23–6.

V. Antón Vázquez<sup>a,\*</sup>, P. Armario García<sup>a</sup>,  
S.M. García Sánchez<sup>b</sup>, C. Martí Castillejos<sup>c</sup>

<sup>a</sup> Servicio de Medicina Interna, Hospital Moisès Broggi, Sant Joan Despí, Barcelona, Spain

<sup>b</sup> Servicio de Neurología, Hospital Moisès Broggi, Sant Joan Despí, Barcelona, Spain

<sup>c</sup> Área de Riesgo Cardiovascular, Hospital Moisès Broggi, Sant Joan Despí, Barcelona, Spain

\* Corresponding author.

E-mail address: [vanesa.anton.v@gmail.com](mailto:vanesa.anton.v@gmail.com)  
(V. Antón Vázquez).

<https://doi.org/10.1016/j.nrleng.2017.07.011>

2173-5808/

© 2017 Sociedad Española de Neurología. Published by Elsevier España, S.L.U. This is an open access article under the CC BY-NC-ND license (<http://creativecommons.org/licenses/by-nc-nd/4.0/>).

## Posterior reversible leukoencephalopathy after cyanamide overdose<sup>☆</sup>



### Leucoencefalopatía posterior reversible tras sobredosis de carbimida

Dear Editor:

Posterior reversible leukoencephalopathy syndrome (PRLS) is characterised by subcortical cerebral oedema of vasogenic origin in patients with acute neurological symptoms.<sup>1</sup> We present a case of PRLS associated with cyanamide overdose.

Our patient is a 48-year-old woman admitted to the intensive care unit due to low level of consciousness after taking 500 mg of Colme<sup>®</sup> (calcium cyanamide). The patient presented adjustment disorder and was under treatment with cyanamide for alcohol abuse.

At admission we observed somnolence, with the patient opening her eyes when instructed but with no voluntary gaze; menace response absent bilaterally, suggestive of cortical blindness; isochoric and reactive pupils; and non-persistent horizontal nystagmus. The patient was unable to follow simple instructions, produced unintelligible sounds, and showed loss of strength in the upper limbs with impaired osteomuscular reflexes. The neurological and systemic examination yielded no other relevant findings. An eye fundus examination revealed no alterations. The patient's body weight at the time of admission was 64 kg.

Blood analysis showed creatine kinase levels at 2394 U/L; aspartate transaminase at 428 U/L; alanine aminotransferase at 140 U/L; gamma-glutamyl transpeptidase at 240 U/L, and bilirubin at 2 mg/dL. The remaining blood analytical values (glucose, urea, creatinine, sodium, potassium, magnesium, phosphorus, calcium, ammonia, C-reactive protein, and lactate), gasometric parameters (pH, pCO<sub>2</sub>, pO<sub>2</sub>, bicarbonate, and base excess), haematology values

(haemoglobin, haematocrit, leucocyte, and platelet count), and coagulation parameters (prothrombin activity, prothrombin time, activated partial thromboplastin ratio, and fibrinogen) showed no alterations with regards to our laboratory's reference values. Urine toxicology, including tests for amphetamines, cocaine, tetrahydrocannabinol, barbiturates, benzodiazepines, tricyclic antidepressants, opioids, and phencyclidine, showed negative results.

A head computed tomography (CT) scan showed occipital white matter hypodensity bilaterally, predominantly affecting the left side. An electroencephalography showed signs of moderate encephalopathy with no signs of epileptiform activity. MRI findings confirmed the presence of vasogenic oedema associated with PRLS, involving both occipital lobes with focal extension to the parietal and left frontal areas (Fig. 1).

We administered activated charcoal, suspended cyanamide, and continued with life support measures. The patient progressed favourably, fully recovering after 14 days. Blood analysis and electroencephalography findings also normalised. Furthermore, the follow-up MRI scan confirmed the disappearance of the alterations observed at admission. The patient subsequently admitted she had taken calcium cyanamide with suicidal intent and denied having consumed alcohol concomitantly.

Carbimide or calcium cyanamide is used for treating alcoholism as it causes aversion to alcohol by provoking aldehyde syndrome or the Antabuse effect.<sup>2,3</sup> In the absence of alcohol consumption, cyanamide is well tolerated at normal doses. Although few cases are described in the literature, overdose in the absence of alcohol consumption has been associated with kidney failure, liver failure, respiratory failure, decreased level of consciousness, and metabolic acidosis.<sup>2,3</sup> In our case, symptoms manifested after ingestion of cyanamide and no other associated factor could be identified. Furthermore, the patient explicitly denied having consumed alcohol concomitantly.

Our patient presented acute neurological impairment consisting of encephalopathy associated with cortical blindness. The first CT scan was decisive in the diagnosis, whereas the blood analysis findings did not explain the neurological symptoms. The early MRI study enabled us to establish the diagnosis.

PRLS is characterised by subcortical vasogenic oedema in patients presenting acute neurological alterations.<sup>1,4,5</sup> Encephalopathy presents the typical symptoms, from disorientation to deep coma. Other reported symptoms are seizures, visual alterations, and headache. Focal symptoms

<sup>☆</sup> Please cite this article as: Peñasco Y, González-Castro A, Rodríguez-Borregán JC, Sánchez-de la Torre R, González-Suárez A. Leucoencefalopatía posterior reversible tras sobredosis de carbimida. *Neurología*. 2020;35:67–68.