




SOCIEDAD ESPAÑOLA
DE NEUROLOGÍA

NEUROLOGÍA

www.elsevier.es/neurologia



LETTER TO THE EDITOR

SARS-CoV-2 infection associated with diplopia and anti-acetylcholine receptor antibodies[☆]



Infección por SARS-CoV-2 asociada a diplopía y anticuerpos antirreceptor de acetilcolina

Dear Editor:

A novel coronavirus, SARS-CoV-2, was detected in Wuhan, China, in December 2019 and the associated disease, known as COVID-19, has quickly become a pandemic. Several reports suggest that SARS-CoV-2 may infect the central nervous system, causing neurological alterations.¹ Some authors have reported cases of encephalopathy,² acute necrotising haemorrhagic encephalopathy,³ meningoencephalitis,⁴ headache, myalgia, neuropathic pain, hyposmia, ageusia, ataxia, epileptic seizures, and cerebrovascular events.⁵ To our knowledge, no peripheral nervous system alterations other than those mentioned above have been reported to date. We present the case of a 48-year-old man with paranoid schizophrenia, under treatment with aripiprazole; inverse psoriasis; and no other relevant medical history. The patient came to the emergency department due to a 5-day history of binocular diplopia, which was more marked at long distance and with lateral gaze, with a tendency to improvement. He also reported presenting high fever, dry cough, dyspnoea, and myalgia 15 days previously; he self-isolated in view of the current epidemiological situation. Fever resolved 5 days prior to the consultation, but diplopia appeared; the remaining symptoms had improved. The physical examination revealed expiratory wheezing. The neurological examination revealed isochoric, reactive pupils; normal confrontation visual field test results; horizontal diplopia with gaze to the right; and no observable eye movement restriction. Results were normal for all other areas. A blood analysis detected high levels of acute-phase reactants (fibrinogen 885 mg/dL, CRP 8.8 mg/dL, D-dimer 1095 ng/mL). The patient was admitted to the internal medicine department due to suspected COVID-19. PCR

testing was negative for SARS-CoV-2 in nasopharyngeal exudate but positive in sputum. A chest radiography showed right lower lobe opacification and lingula consolidation; these findings were confirmed by a chest CT scan and linked to the infection (Figs. 1 and 2). More detailed analyses showed normal kidney, liver, and thyroid function; vitamin B₁₂ and folate levels within normal ranges; and normal lipid profile, blood count, and coagulation profile. Autoimmune tests yielded negative results except for antinuclear antibodies (1:320, homogeneous pattern) and acetylcholine receptor antibodies (1.10 nmol/L; positive: >0.20 nmol/L). Serology tests were negative. Diplopia resolved the day after hospital admission. A head CT scan

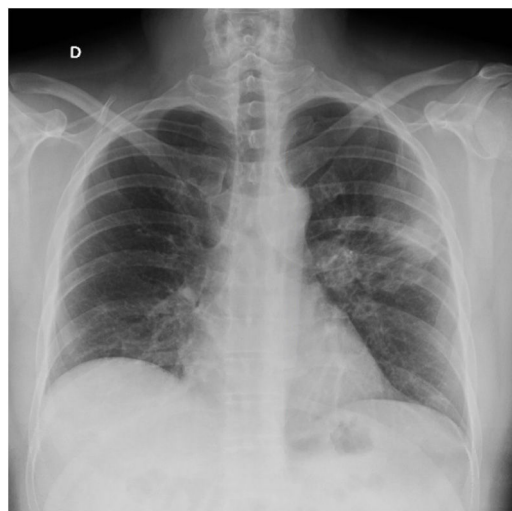

Figure 1 Chest radiography showing right lower lobe opacification and left lingula consolidation.

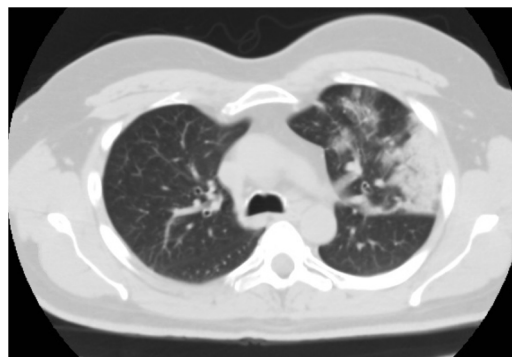


Figure 2 Chest CT scan revealing ground-glass parenchymal opacification in the upper lobe of the left lung.

[☆] Please cite this article as: Pérez Álvarez ÁI, Suárez Cuervo C, Fernández Menéndez S. Infección por SARS-CoV-2 asociada a diplopía y anticuerpos antirreceptor de acetilcolina. Neurología. 2020;35:264–265.

showed no space-occupying lesions, vascular alterations, or any other abnormal findings. The patient's general condition improved and he was discharged 2 days after admission; he was instructed to continue treatment with hydroxychloroquine and azithromycin. Our patient developed diplopia associated with acetylcholine receptor antibodies in the context of microbiologically confirmed SARS-CoV-2 infection; symptoms resolved completely within days. He had no cardiovascular risk factors and neuroimaging studies revealed no vascular or space-occupying lesions that may otherwise explain his symptoms. We suggest 2 possible explanations for our case. First, the patient had latent myasthenia gravis, which was precipitated by SARS-CoV-2 infection; and second, SARS-CoV-2 infection was the main cause of the patient's symptoms, triggering an autoimmune response, with tropism to the neuromuscular junction as a result of molecular mimicry.⁶ Clinical and serological follow-up of our patient is necessary to evaluate his progression and detect any changes. Patients with COVID-19 must be screened for symptoms of muscle fatigability. This information is essential to direct further testing, with a view to determining whether myasthenia gravis is a possible complication of SARS-CoV-2 infection. This may open new lines of research into COVID-19.

References

1. Matías-Guiu J, Gomez-Pinedo U, Montero-Escribano P, Gomez-Iglesias J, Porta-Etessam J, Matias-Guiu JA. ¿Es esperable que haya cuadros neurológicos por la pandemia por SARS-CoV-2? Neurología. 2020, <http://dx.doi.org/10.1016/j.nrl.2020.03.001>.
2. Filatov A, Sharma P, Hindi F, Espinosa PS. Neurological complications of coronavirus disease (COVID-19): encephalopathy. *Cureus*. 2020, <http://dx.doi.org/10.7759/cureus.7352>.
3. Poyiadji N, Shahin G, Noujaim D, Stone M, Patel S, Griffith B. COVID-19-associated acute hemorrhagic necrotizing encephalopathy: CT and MRI features. *Radiology*. 2020, <http://dx.doi.org/10.1148/radiol.2020201187>.
4. Moriguchi T, Harii N, Goto J, Harada D, Sugawara H, Takamino J, et al. A first case of meningitis/encephalitis associated with SARS-Coronavirus-2. *Int J Infect Dis*. 2020, <http://dx.doi.org/10.1016/j.ijid.2020.03.062>.
5. Mao L, Jin H, Wang M, Hu Y, Chen S, He Q, et al. Neurologic manifestations of hospitalized patients with coronavirus disease 2019 in Wuhan, China. *JAMA Neurol*. 2020, <http://dx.doi.org/10.1001/jamaneurol.2020.1127>.
6. Rojas M, Restrepo-Jiménez P, Monsalve DM, Pacheco Y, Acosta-Ampudia Y, Ramírez-Santana C, et al. Molecular mimicry and autoimmunity. *J Autoimmun*. 2018;95:100–23.

Á.I. Pérez Álvarez^{a,*}, C. Suárez Cuervo^b,
S. Fernández Menéndez^a

^a Servicio de Neurología, Hospital Universitario Central de Asturias, Oviedo, Spain

^b Servicio de Medicina Interna, Hospital Universitario Central de Asturias, Oviedo, Spain

* Corresponding author.

E-mail address: angelperez@telecable.es
(Á.I. Pérez Álvarez).

<https://doi.org/10.1016/j.nrleng.2020.04.003>
2173-5808/

© 2020 Published by Elsevier España, S.L.U. on behalf of Sociedad Española de Neurología. This is an open access article under the CC BY-NC-ND license (<http://creativecommons.org/licenses/by-nc-nd/4.0/>).

Fatal Guillain-Barre syndrome after infection with SARS-CoV-2[☆]



Síndrome de Guillain-Barré fatal tras infección por el virus SARS-CoV-2

Dear Editor:

Since the appearance of the first cases of infection with the severe acute respiratory syndrome coronavirus 2 (SARS-CoV-2) in the Chinese province of Hubei in December 2019, the disease caused by this pathogen has spread across the world, with high infectivity and mortality rates. The typical symptoms of SARS-CoV-2 infection include fever, asthenia, and

dry cough¹; more severe cases present respiratory insufficiency secondary to alveolar damage caused by massive release of proinflammatory molecules.² However, little is known about the neurological complications associated with SARS-CoV-2 infection.³ We present a case of progressive tetraparesis, global areflexia, and fatal bulbar syndrome, clinically compatible with acute inflammatory polyradiculoneuropathy associated with SARS-CoV-2 infection.

Our patient was a 76-year-old woman with previously good quality of life who was transferred to the emergency department at Complejo Hospitalario de Navarra due to a 10-day history of lower back pain radiating to the backs of the legs and progressive tetraparesis with distal-onset paraesthesia. Pain was bilateral, predominantly affecting the right side; it was more intense during the night, leading to difficulties falling asleep. The patient was treated with nonsteroidal anti-inflammatory drugs, pyrazolones, and transdermal morphine. Progressive, predominantly proximal weakness was observed in the lower limbs; 2 days before our assessment, she presented weakness of the upper limbs, with functional limitation.

Eight days before symptom onset, the patient had presented cough and fever without dyspnoea, lasting 72 hours, which were treated with amoxicillin/clavulanic acid and

[☆] Please cite this article as: Marta-Enguita J, Rubio-Baines I, Gastón-Zubimendi I. Síndrome de Guillain-Barré fatal tras infección por el virus SARS-CoV-2. *Neurología*. 2020;35:265–267.