

showed no space-occupying lesions, vascular alterations, or any other abnormal findings. The patient's general condition improved and he was discharged 2 days after admission; he was instructed to continue treatment with hydroxychloroquine and azithromycin. Our patient developed diplopia associated with acetylcholine receptor antibodies in the context of microbiologically confirmed SARS-CoV-2 infection; symptoms resolved completely within days. He had no cardiovascular risk factors and neuroimaging studies revealed no vascular or space-occupying lesions that may otherwise explain his symptoms. We suggest 2 possible explanations for our case. First, the patient had latent myasthenia gravis, which was precipitated by SARS-CoV-2 infection; and second, SARS-CoV-2 infection was the main cause of the patient's symptoms, triggering an autoimmune response, with tropism to the neuromuscular junction as a result of molecular mimicry.⁶ Clinical and serological follow-up of our patient is necessary to evaluate his progression and detect any changes. Patients with COVID-19 must be screened for symptoms of muscle fatigability. This information is essential to direct further testing, with a view to determining whether myasthenia gravis is a possible complication of SARS-CoV-2 infection. This may open new lines of research into COVID-19.

References

1. Matías-Guiu J, Gomez-Pinedo U, Montero-Escribano P, Gomez-Iglesias J, Porta-Etessam J, Matias-Guiu JA. ¿Es esperable que haya cuadros neurológicos por la pandemia por SARS-CoV-2? Neurología. 2020, <http://dx.doi.org/10.1016/j.nrl.2020.03.001>.
2. Filatov A, Sharma P, Hindi F, Espinosa PS. Neurological complications of coronavirus disease (COVID-19): encephalopathy. *Cureus*. 2020, <http://dx.doi.org/10.7759/cureus.7352>.
3. Poyiadji N, Shahin G, Noujaim D, Stone M, Patel S, Griffith B. COVID-19-associated acute hemorrhagic necrotizing encephalopathy: CT and MRI features. *Radiology*. 2020, <http://dx.doi.org/10.1148/radiol.2020201187>.
4. Moriguchi T, Harii N, Goto J, Harada D, Sugawara H, Takamino J, et al. A first case of meningitis/encephalitis associated with SARS-Coronavirus-2. *Int J Infect Dis*. 2020, <http://dx.doi.org/10.1016/j.ijid.2020.03.062>.
5. Mao L, Jin H, Wang M, Hu Y, Chen S, He Q, et al. Neurologic manifestations of hospitalized patients with coronavirus disease 2019 in Wuhan, China. *JAMA Neurol*. 2020, <http://dx.doi.org/10.1001/jamaneurol.2020.1127>.
6. Rojas M, Restrepo-Jiménez P, Monsalve DM, Pacheco Y, Acosta-Ampudia Y, Ramírez-Santana C, et al. Molecular mimicry and autoimmunity. *J Autoimmun*. 2018;95:100–23.

Á.I. Pérez Álvarez^{a,*}, C. Suárez Cuervo^b,
S. Fernández Menéndez^a

^a Servicio de Neurología, Hospital Universitario Central de Asturias, Oviedo, Spain

^b Servicio de Medicina Interna, Hospital Universitario Central de Asturias, Oviedo, Spain

* Corresponding author.

E-mail address: angelperez@telecable.es
(Á.I. Pérez Álvarez).

<https://doi.org/10.1016/j.nrleng.2020.04.003>
2173-5808/

© 2020 Published by Elsevier España, S.L.U. on behalf of Sociedad Española de Neurología. This is an open access article under the CC BY-NC-ND license (<http://creativecommons.org/licenses/by-nc-nd/4.0/>).

Fatal Guillain-Barre syndrome after infection with SARS-CoV-2[☆]



Síndrome de Guillain-Barré fatal tras infección por el virus SARS-CoV-2

Dear Editor:

Since the appearance of the first cases of infection with the severe acute respiratory syndrome coronavirus 2 (SARS-CoV-2) in the Chinese province of Hubei in December 2019, the disease caused by this pathogen has spread across the world, with high infectivity and mortality rates. The typical symptoms of SARS-CoV-2 infection include fever, asthenia, and

dry cough¹; more severe cases present respiratory insufficiency secondary to alveolar damage caused by massive release of proinflammatory molecules.² However, little is known about the neurological complications associated with SARS-CoV-2 infection.³ We present a case of progressive tetraparesis, global areflexia, and fatal bulbar syndrome, clinically compatible with acute inflammatory polyradiculoneuropathy associated with SARS-CoV-2 infection.

Our patient was a 76-year-old woman with previously good quality of life who was transferred to the emergency department at Complejo Hospitalario de Navarra due to a 10-day history of lower back pain radiating to the backs of the legs and progressive tetraparesis with distal-onset paraesthesia. Pain was bilateral, predominantly affecting the right side; it was more intense during the night, leading to difficulties falling asleep. The patient was treated with nonsteroidal anti-inflammatory drugs, pyrazolones, and transdermal morphine. Progressive, predominantly proximal weakness was observed in the lower limbs; 2 days before our assessment, she presented weakness of the upper limbs, with functional limitation.

Eight days before symptom onset, the patient had presented cough and fever without dyspnoea, lasting 72 hours, which were treated with amoxicillin/clavulanic acid and

[☆] Please cite this article as: Marta-Enguita J, Rubio-Baines I, Gastón-Zubimendi I. Síndrome de Guillain-Barré fatal tras infección por el virus SARS-CoV-2. *Neurología*. 2020;35:265–267.

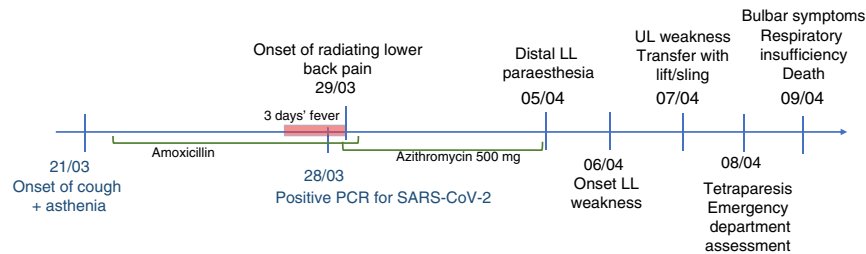


Figure 1 Timeline of symptoms. Symptom progression from respiratory symptom onset to neurological manifestations and death. PCR: polymerase chain reaction; LL: lower limb; UL: upper limb.

azithromycin. A polymerase chain reaction (PCR) test yielded positive results for SARS-CoV-2 infection (Fig. 1).

The neurological examination revealed predominantly proximal muscle weakness in the upper limbs of 0/5 in proximal muscles, and 4/5 in distal muscles; in the lower limbs, we observed proximal weakness of 0/5 in the psoas and 1/5 in quadriceps, and distal weakness of 2–3/5 in the tibialis anterior muscles. The patient presented global areflexia and hypoaesthesia in both legs, progressing distally from the knees.

An emergency blood analysis showed mild thrombocytopenia ($102 \times 10^9/L$) and high levels of fibrinogen (470 mg/dL) and D-dimer (773 ngFEU/mL), with no other alterations. A head CT scan revealed no alterations, and a cervical and thoracic spine CT scan showed degeneration of the vertebral bodies without invasion of the spinal canal. A chest CT scan showed a pattern compatible with mild lung involvement due to SARS-CoV-2 infection.

Four hours after admission, the patient presented dysphagia to liquids and progressively to solids, nasal voice, and difficulty swallowing saliva, with progressive onset of respiratory failure. Her condition progressively deteriorated, and she required oxygen therapy (60% FiO₂), with oxygen saturation levels at about 91%, which is not suggestive of blood–air barrier dysfunction or impaired gas exchange. The patient finally died 12 hours after onset of the bulbar symptoms.

The main limitation of our case report is the lack of complementary tests supporting the diagnostic suspicion, given the rapid progression of symptoms and the context of the public health crisis. However, the symptoms of progressive tetraparesis and areflexia meet the main clinical criteria for diagnosis of Guillain-Barré syndrome.⁴ The presence of symmetrical motor involvement, mild to moderate sensory alterations, the radiating lower back pain at onset, and the bulbar symptoms also support this diagnosis.^{5,6} Diagnosis of such other conditions as myasthenic syndrome seems less likely, due to the presence of sensory symptoms.

The literature includes few data on the development of acute inflammatory polyradiculoneuropathy secondary to SARS-CoV-2 infection. In some of the cases reported, the temporal association is unclear and the SARS-CoV-2 infection may be incidental, rather than the aetiological cause.⁷ However, the presence of a viral or bacterial infection or vaccination in the weeks before symptom onset, acting as trigger factor for dysimmunity, is one of the classic pillars of this process. In the context of infection with similar coronaviruses, acute inflammatory

polyradiculoneuropathy has been associated with Bickerstaff encephalitis in a patient with Middle East respiratory syndrome coronavirus infection.⁸ Other pathogenic agents, such as human coronavirus OC43, have also been associated with cases of acute inflammatory polyradiculoneuropathy.⁹ Further studies are needed to understand the effects of SARS-CoV-2 infection on the central nervous system and the possible development of neurological complications, such as acute inflammatory polyradiculoneuropathy.

References

- Wang D, Hu B, Hu C, Zhu F, Liu X, Zhang J, et al. Clinical characteristics of 138 hospitalized patients with 2019 novel coronavirus-infected pneumonia in Wuhan, China. *JAMA*. 2020;323:1061–9. <http://dx.doi.org/10.1001/jama.2020.1585>.
- Chen G, Wu D, Guo W, Cao Y, Huang D, Wang H, et al. Clinical and immunological features in severe and moderate coronavirus disease 2019. *J Clin Invest*. 2020;130:2620–9. <http://dx.doi.org/10.1172/JCI137244>.
- Matias-Guiu J, Gomez-Pinedo U, Montero-Escribano P, Gomez-Iglesias P, Porta-Etessam J, Matias-Guiu JA. ¿Es esperable que haya cuadros neurológicos por la pandemia por SARS-CoV-2? *Neurología*. 2020;35:170–5. <http://dx.doi.org/10.1016/j.nrl.2020.03.001>.
- Asbury AK, Cornblath DR. Assessment of current diagnostic criteria for Guillain-Barré syndrome. *Ann Neurol*. 1990;27:21–4. <http://dx.doi.org/10.1002/ana.410270707>.
- Fokke C, van den Berg B, Drenth J, Walgaard C, van Doorn PA, Jacobs BC. Diagnosis of Guillain-Barré syndrome and validation of Brighton criteria. *Brain*. 2014;137:33–43. <http://dx.doi.org/10.1093/brain/awt285>.
- Leonhard SE, Mandarakas MR, Gondim FAA, Bateman K, Ferreira MLB, Cornblath DR, et al. Diagnosis and management of Guillain-Barré syndrome in ten steps. *Nat Rev Neurol*. 2019;15:671–83. <http://dx.doi.org/10.1038/s41582-019-0250-9>.
- Zhao H, Shen D, Zhou H, Liu J, Chen S. Guillain-Barré syndrome associated with SARS-CoV-2 infection: Causality or coincidence? *Lancet Neurol*. 2020;19:383–4. [http://dx.doi.org/10.1016/S1474-4422\(20\)30109-5](http://dx.doi.org/10.1016/S1474-4422(20)30109-5).
- Kim JE, Heo JH, Kim HO, Song SH, Park SS, Park TH, et al. Neurological complications during treatment of middle east respiratory syndrome. *J Clin Neurol*. 2017;13:227–33. <http://dx.doi.org/10.3988/jcn.2017.13.3.227>.
- Sharma K, Tengsupakul S, Sanchez O, Phaltas R, Maertens P. Guillain-Barré syndrome with unilateral peripheral facial and bulbar palsy in a child: a case report. *SAGE Open Med Case Rep*. 2019;7, 2050313X1983875, [10.1177/2050313X19838750](http://dx.doi.org/10.1177/2050313X19838750).

J. Marta-Enguita*, I. Rubio-Baines, I. Gastón-Zubimendi

Servicio de Neurología, Complejo Hospitalario de Navarra, Pamplona, Navarra, Spain

*Corresponding author.

E-mail address: j.marta.enguita@navarra.es (J. Marta-Enguita).

<https://doi.org/10.1016/j.nrleng.2020.04.004>
2173-5808/

© 2020 Sociedad Española de Neurología. Published by Elsevier España, S.L.U. This is an open access article under the CC BY-NC-ND license (<http://creativecommons.org/licenses/by-nc-nd/4.0/>).

A neurology department at a tertiary-level hospital during the COVID-19 pandemic[☆]



Un servicio de neurología de un hospital terciario en la pandemia COVID-19

Dear Editor:

In the current healthcare context, we believe it may be beneficial to share information on the adaptations implemented in the working dynamics of the Neurology Department at Hospital General Universitario Gregorio Marañón (Madrid, Spain) in response to the COVID-19 pandemic.

After the first patients with COVID-19 were admitted to our centre in late February 2020, we suspended clinical training sessions to respect social distancing. Essential clinical information on hospitalised patients was communicated in sessions with very few attendees: the incoming and outgoing on-call teams, ward managers, and the head of the department. From that time, all the department's internal communication was made by email or telephone. COVID-19 training sessions were provided through online platforms.

In early March, there was an exponential increase in patients attended at the emergency department and hospitalised due to COVID-19; the magnitude of demand left the first-line departments dealing with the pandemic (the emergency, pulmonology, infectious diseases, and internal medicine departments and the intensive care unit) at the limit of their capacity. The neurology department had to be adapted to contribute to this first line of response against the pandemic while simultaneously guaranteeing the best possible care for neurological patients.

The specific targets for this adaptation were:

- 1) To guarantee the neurological care of patients with urgent conditions.
- 2) To provide the staff needed in the response against COVID-19, whenever this was required.
- 3) To maintain contact with patients who would normally be seen in consultations at the hospital or at other specialty

centres but were unable to attend these consultations given the current circumstances.

Pursuant to these objectives, the following measures were implemented:

- 1) Specific neurology on-call shifts and inpatient wards, as well as the stroke unit, were maintained. Code stroke protocols were maintained, including neurointerventional procedures. Replacement of generators from nerve stimulators was also continued. Scheduled hospitalisations were suspended.
- 2) The neurology in-hospital consultation team was maintained.
- 3) Telephone consultations were implemented to replace conventional in-person consultations. Electronic prescribing was implemented. Patients with implanted nerve stimulators or drug infusion pumps received special follow-up.
- 4) Essential treatments continued to be administered at the neurology day hospital. Botulinum toxin administration was temporarily suspended. Immunosuppressive treatments were postponed in cases where the patient's situation allowed for this.
- 5) Contact was made almost on a daily basis with emergency department and inpatient ward staff responsible for patients with COVID-19 in order to determine the number of additional physicians needed.

From the second week of March, neurologists gradually began to join the team caring for patients with COVID-19 (14 neurologists are currently in this team), frequently leading to reallocation of duties. Furthermore, the number of neurological patients attended at the emergency department and hospitalised decreased, enabling us to decrease the number of neurologists in the inpatient ward, where only patients without COVID-19 are being admitted.

Patients with COVID-19 presenting neurological disorders are admitted to specific COVID-19 wards (currently, the hospital is working almost exclusively in the care of patients with COVID-19) and are attended jointly by physicians from these wards and the neurology in-hospital consultation team, except if the ward team already includes a neurologist.

The structured "withdrawal" from care activity in this dynamic situation involved the participation of all staff and residents in the neurology department, who worked with great speed, effectiveness, dedication, and commitment. Clinical research has temporarily been suspended with the exception of special cases. Undergraduate teaching, which was suspended in February, has continued through the Vir-

[☆] Please cite this article as: Grandas F, García Domínguez JM, Díaz Otero F, en nombre del Servicio de Neurología del Hospital General Universitario Gregorio Marañón. Un servicio de neurología de un hospital terciario en la pandemia COVID-19. *Neurología*. 2020;35:267–268.