

## References

- Ogawa R, Nakashima I, Takahashi T, Kaneko K, Akaishi T, Takai Y, et al. MOG antibody-positive, benign, unilateral, cerebral cortical encephalitis with epilepsy. *Neurol Neuroimmunol NeuroInflamm.* 2017;4.
- Budhram A, Sechi E, Nguyen A, Lopez-Chiriboga AS, Flanagan EP. FLAIR-hyperintense Lesions in Anti-MOG-associated Encephalitis with Seizures (FLAMES): is immunotherapy always needed to put out the fire? *Mult Scler Relat Disord* [Internet]. 2020;44:102283, <http://dx.doi.org/10.1016/j.msard.2020.102283>.
- Budhram A, Mirian A, Le C, Hosseini-Moghaddam SM, Sharma M, Nicolle MW. Unilateral cortical FLAIR-hyperintense Lesions in Anti-MOG-associated Encephalitis with Seizures (FLAMES): characterization of a distinct clinico-radiographic syndrome. *J Neurol.* 2019;266:2481–7.
- Zhou L, Zhang Bao J, Li H, Li X, Huang Y, Wang M, et al. Cerebral cortical encephalitis followed by recurrent CNS demyelination in a patient with concomitant anti-MOG and anti-NMDA receptor antibodies. *Mult Scler Relat Disord* [Internet]. 2017;18:90–2, <http://dx.doi.org/10.1016/j.msard.2017.09.023>.
- Fujimori J, Takahashi T, Kaneko K, Atobe Y, Nakashima I. Anti-NMDAR encephalitis may develop concurrently with anti-MOG antibody-associated bilateral medial frontal cerebral cortical encephalitis and relapse with elevated CSF IL-6 and CXCL13. *Mult Scler Relat Disord.* 2021;47:13–5.
- Chang YC, Sharma M, Budhram A. Unilateral cortical FLAIR-hyperintense Lesion in Anti-MOG-associated Encephalitis with Seizures (FLAMES) on TNF inhibitor therapy. *J Neurol Neurosurg Psychiatry.* 2021;2–3.
- Jain K, Cherian A, Divya KP, Rajalakshmi P, Thomas B, Nandana J. FLAMES: a novel burning entity in MOG IgG associated disease. *Mult Scler Relat Disord.* 2021;49, 2020.
- Kunchok A, Aksamit AJ, Davis JM, Kantarci OH, Keegan BM, Pittock SJ, et al. Association between tumor necrosis factor inhibitor exposure and inflammatory central nervous system events. *JAMA Neurol.* 2020;77:937–46.
- Philippart M, Fastré S, Rahier JF, London F. First report of coexistence of MOG-antibody-positive disease and Crohn's disease. *Mult Scler Relat Disord* [Internet]. 2019;28:1–3, <http://dx.doi.org/10.1016/j.msard.2018.12.006>.
- Stamenova S, Redha I, Schmierer K, Garcia ME. FLAIR-hyperintense lesions in anti-MOG-associated encephalitis with seizures (FLAMES) unmasked by withdrawal of immunosuppression for Crohn's disease? *Mult Scler Relat Disord.* 2021;48.

P. Cabezudo-García<sup>a,\*</sup>, M. Vidal Denis<sup>b</sup>,  
N.L. Ciano-Petersen<sup>a</sup>, M.V. Irigoyen-Oyarzábal<sup>c</sup>,  
P.J. Serrano-Castro<sup>a</sup>

<sup>a</sup> Instituto de Investigación Biomédica de Málaga (IBIMA), Servicio de Neurología, UGC de Neurociencias, Hospital Regional Universitario de Málaga, Málaga, Spain

<sup>b</sup> Servicio de Radiología, Hospital Regional Universitario de Málaga, Málaga, Spain

<sup>c</sup> Instituto de Investigación Biomédica de Málaga (IBIMA), Servicio de Reumatología, Hospital Regional Universitario de Málaga, Málaga, Spain

\* Corresponding author.

E-mail address: [pablocabezudo@gmail.com](mailto:pablocabezudo@gmail.com)

(P. Cabezudo-García).

<https://doi.org/10.1016/j.nrl.2021.06.002>  
2173-5808/

© 2021 Sociedad Española de Neurología. Published by Elsevier España, S.L.U. This is an open access article under the CC BY-NC-ND license (<http://creativecommons.org/licenses/by-nc-nd/4.0/>).

## Isolated speech-induced lingual dystonia successfully treated with botulinum neurotoxin

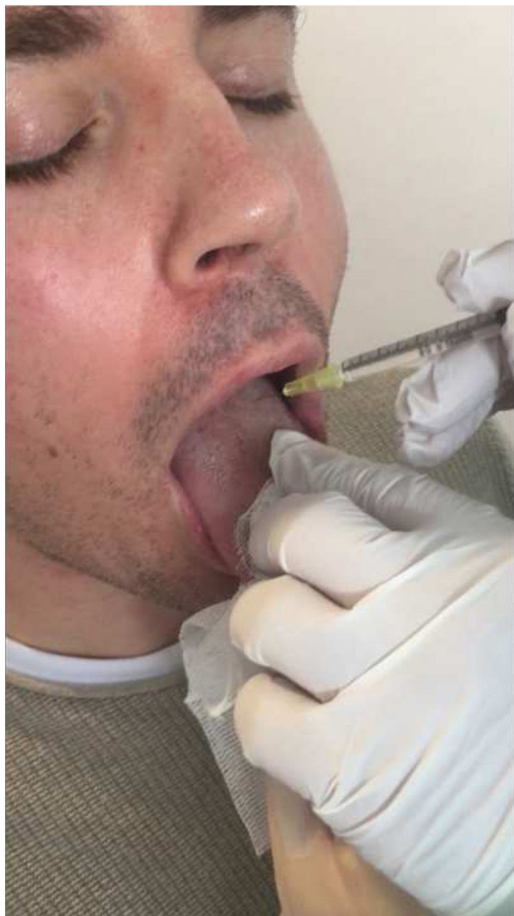


## Distonía lingual inducida por el habla con respuesta favorable a toxina botulínica

Dear Editor:

Dystonia is a hyperkinetic disorder characterized by sustained or intermittent muscle contractions, resulting in abnormal repetitive movements and/or postures.<sup>1</sup> Oro-mandibular dystonia (OMD) is a focal type of dystonia that involves masticatory and/or lingual muscles. Lingual dystonia is one of its subtypes. According to some case series, it might take up to the 4% of all the dystonias assessed in a Movement Disorder Department.<sup>2</sup> Speech-induced lingual dystonia is rare. Mainly, it can be idiopathic and according to literature can be considered as an occupational dystonia in some patients.<sup>3</sup> Despite its low prevalence, it can be very disabling and requires proper identification and management. We report here a case of a young man who presented with an isolated speech-induced lingual dystonia with an excellent response to Botulinum neurotoxin (BoNT).

A 34 year-old man was referred to our department of Neurology with a five month history of slurred speech and progressive difficulty to move the tongue. A second-grade relative suffered from epilepsy, but there was no other family history of interest. He worked as telemarketer and spent up to eight hour-a-day speaking. Due to his symptoms, which continued worsening, he had to stop working and felt embarrassed when holding a conversation. No concomitant treatment or any other precipitating factor were found. His neurological exam revealed speech-induced tongue protrusion associated with mild to moderate dysarthria (Video 1). His symptoms improved when chewing gum (Video 2) or bread, as well as when speaking out. Brain MRI (including T2-sequence), electromyography (EMG), and extensive blood tests (including thyroid function, copper metabolism, folate and vitamin B12 levels) were normal. A diagnosis of idiopathic speech-induced focal dystonia (occupational) was performed and trihexyphenidyl (up to 4.5 mg) was started, obtaining slight improvement without remarkable secondary effects. Six months later BoNT was started. Specifically, 2.5 units of BoNT (Botox®, Allergan Pharmaceuticals) were injected intraoral bilaterally in only 1 point of each genioglossus muscle (Fig. 1). No secondary effects were observed. One week later he noticed slight clinical improvement, but only maintained for one month. BoNT injection was repeated within 3 and 6 months, increasing dosage up to 5 units at each genioglossus. The second infiltration led to a clinical benefit that remained



**Figure 1** Intraoral injection of BoNT at left genioglossus muscle.

for only two months. Five days after the third injection a remarkable and sustained response was referred. The neurological exam was normal four months later (Video 3). Trihexyphenidyl was left progressively without impairment. One year later, the patient was looking for a job and reported a great improvement into his social life.

Speech-induced dystonia is a rare, but potentially really disabling condition. Its pathophysiology is not clear yet. Classical models were based into the idea of an abnormal plasticity regulation.<sup>4</sup> However, some recent publications question this hypothesis, considering the plasticity response variability inter and intra-subject as well as plasticity is not required to develop secondary dystonia.<sup>5,6</sup> Current hypothesis defend that both genetic and environmental factors play an important role in the aetiology of dystonia. Different brain structures (thalamus, cerebellum and sensorimotor cortex) are thought to be involved in its pathophysiology, leading to a network disfunction.<sup>6,7</sup> Due to the low prevalence of lingual dystonia, it has previously been reported on in single case reports<sup>8,9</sup> or case series.<sup>10,11</sup> Recently, Yoshida et al. reported the largest series with 172 patients with lingual dystonia.<sup>2</sup> Lingual protrusion, as in our case, was the most frequent but retraction, curling and lateropulsion dystonia have been observed as well. Moreover, it can be considered as an occupational dystonia. Indeed, task-specificity was observed in 90.1% of patients reported by Yoshida et al during speaking, chewing, or swallowing. Our

patient had no history of exposure to neuroleptic medications, facial or oromandibular injuries, or recent infection. For this reason, the condition was diagnosed as a lingual dystonia specifically induced by speaking after all laboratory examinations had ruled out secondary causes. Isolated lingual dystonia is extremely rare as most reports have described patients with lingual dystonia who also displayed dystonic movements elsewhere.<sup>2</sup> According to this, a case of speech-induced task-specific OMD (involving perioral muscles, the tongue and the jaw) has been reported in a bingo caller<sup>8</sup> as well as in a telemarketer.<sup>9</sup>

A number of treatments are used in oromandibular dystonia such as trihexyphenidyl, baclofen, clonazepam, tiapride, or zolpidem.<sup>11</sup> However, BoNT injection has been demonstrated to be the most effective.<sup>2,8,11–13</sup> The genioglossus makes up the bulk of the tongue's muscle mass and is responsible for tongue protrusion, making it an ideal candidate for injection. We did not use EMG guide for injections. However, its use is recommended as it may help to identify muscles correctly and to reduce the risk of potential complications such as dysphagia or aspiration. In any event, administration should be always done by an experienced professional. BoNT tongue injections can cause some potential life-threatening secondary effects, as dysphagia or aspiration. Therefore, its administration should be done by an experienced professional. In our case, it is worth noting the absence of side effects and the good response with low doses.

As conclusion, speech-induced lingual dystonia is an uncommon movement disorder that can face as an occupational phenomenon. Neurologists and other physicians need to be aware of this condition, even in the absence of other dystonic phenomena. Although a few cases have been reported to date, BoNT seem to be an effective treatment for this condition. Further studies are needed to clarify underlying mechanism and to evaluate the long-term efficacy of BoNT.

## Funding

None declared.

## Author's contribution

Carlos Cores Bartolomé: conception, organization, and execution of the project writing of the first draft of the manuscript.

José Manuel Paz González: review and critique. Treatment of the patient.

María José García Antelo: review and critique. Diagnosis of the patient.

Diego Santos García: review and critique. Diagnosis and treatment of the patient.

## Conflicts of interest

None.

## Acknowledgment

Carlos Cores Bartolomé has received honoraria for educational presentations by Lundbeck, UCB Pharma and Bial.

José Manuel Paz González has received honoraria for educational presentations by UCB Pharma, KRKA, Zambon, Abbvie and Bial.

María José García Antelo: none.

Diego Santos García has received honoraria for educational presentations and advice service by Abbvie, UCB Pharma, Lundbeck, KRKA, Zambon, Bial, Italfarmaco, and Teva.

## Appendix A. Supplementary data

Supplementary data associated with this article can be found, in the online version, at [doi:10.1016/j.nrl.2021.05.010](https://doi.org/10.1016/j.nrl.2021.05.010).

## References

- Albanese A, Bhatia K, Bressman SB, Delong MR, Fahn S, Fung VS, et al. Phenomenology and classification of dystonia: a consensus up date. *Mov Disord.* 2013;28:863–73.
- Yoshida K. Botulinum Neurotoxin therapy for lingual dystonia using an individualized injection method based on clinical features. *Toxins.* 2019;11:51.
- Yoshida K. Clinical and phenomenological characteristics of patients with task-specific lingual dystonia. Possible association with occupation. *Front Neurol.* 2017;8:649.
- Quartarone A, Hallett M. Emerging concepts in the physiological basis of dystonia. *Mov Disord.* 2013;28:958–67.
- Sadnicka A, Hamada M. Plasticity and dystonia: a hypothesis shrouded in variability. *Exp Brain Res.* 2020;238(August):1611–7.
- Latorre A, Cocco A, Bathia KP, Erro R, Antelmi E, Conte A, et al. Defective somatosensory inhibition and plasticity are not required to develop dystonia. *Mov Disord.* 2021;36(April):1015–21.
- Sadnicka A, Kornysheva K, Rothwell JC, Edwards MJ. A unifying motor control framework to task-specific dystonia. *Nat Rev Neurol.* 2018;14(February):116–24.
- Díaz-Sánchez M, Martínez-Castrillo JC. Botulinum toxin in a task-specific oromandibular dystonia in a bingo caller. *J Neurol.* 2008;255:942–3.
- Kim SD, Kim H. Task-specific oromandibular dystonia in a telemarketer. *J Mov Disord.* 2019;12:125–7.
- Budak F, Aydin E, Kockaya A, Ilbay G. Botulinum toxin in the treatment of lingual dystonia induced by speaking. *Case Rep Neurol.* 2013;5:18–20.
- Baik JS, Park JH, Kim JY. Primary lingual dystonia induced by speaking. *Mov Disord.* 2004;19:1251–2.
- Yoshida K, Kaji R, Kubori T, Kohara N, Iizuka T, Kimura J. Muscle afferent block for the treatment of oromandibular dystonia. *Mov Disord.* 1998;13:699–705.
- Blitzer A, Brin MF, Fahn S. Botulinum toxin injections for lingual dystonia. *Laryngoscope.* 1991;101:799.

C. Cores-Bartolomé\*, J.M. Paz-González,  
M.J. García-Antelo, D. Santos-García

*CHUAC, Complejo Hospitalario Universitario de A Coruña, A Coruña, Spain*

\*Corresponding author.

*E-mail address:* [Carlos.Cores.Bartolome@sergas.es](mailto:Carlos.Cores.Bartolome@sergas.es)  
(C. Cores-Bartolomé).

<https://doi.org/10.1016/j.nrl.2021.05.010>  
2173-5808/

© 2021 Sociedad Española de Neurología. Published by Elsevier España, S.L.U. This is an open access article under the CC BY-NC-ND license (<http://creativecommons.org/licenses/by-nc-nd/4.0/>).

## Primary central nervous system germinoma as a rare cause of diffuse ependymal involvement in adults<sup>☆</sup>



### Germinoma primario del sistema nervioso central como causa infrecuente de afectación ependimaria difusa en el adulto

Dear Editor:

Central nervous system germ cell tumours are neoplastic proliferations of germ cells; their incidence is very low

in Western countries, representing fewer than 0.5% of all primary intracranial tumours. In Asian countries, however, germ cell tumours are more frequent.<sup>1</sup> They may be classified into different histological subtypes, with germinomas being the most common, accounting for up to 69% of cases.<sup>2</sup> These tumours are usually diagnosed in childhood, with 90% of patients being younger than 25 years.<sup>3</sup> The clinical manifestations of germ cell tumours vary according to their location. These tumours exhibit variable radiological characteristics, frequently presenting as oval-shaped or lobulated masses located in the pineal gland (38%-57%), suprasellar region (34%-49%), or in both locations (5%-10%). Only 3%-5% of cases involve such other regions as the ventricles.<sup>4,5</sup> Definitive diagnosis is based on histopathological findings, and treatment consists of radiotherapy alone or combined with chemotherapy, achieving remission in up to 90% of cases.<sup>6</sup>

We present the case of a 31-year-old white man, born in Spain, a smoker, with no relevant medical history, who consulted due to a 3-month history of asthenia, nausea, polyuria with polydipsia, reduced libido, loss of appetite, and weight loss of 6 kg. The neurological examination revealed horizon-

<sup>☆</sup> Please cite this article as: Sanesteban Beceiro E, Mayo Rodríguez P, Jorquera Moya M, Ginestal López RC. Germinoma primario del sistema nervioso central como causa infrecuente de afectación ependimaria difusa en el adulto. *Neurología.* 2022;37:308–310.