

infection, lymphopenia could induce regulatory T cell depletion, triggering associated immune hyperactivation.<sup>5</sup>

Besides, there are different techniques to diagnose AE; immunoblotting is still a practice, low-cost sensitive way to detect the classic antibodies.<sup>4</sup> In this case, it was possible to corroborate the presence of the antigens GAD65 and NMDA in the dot-blotting technique and the intracellular and cell-surface antigens in the tissue-based assay.

We hypothesized that an indirect mechanism could have stimulated the production of neuronal antibodies in this patient, where SARS-CoV-2 activated both cellular and humoral immunological that could have generated antibodies that mimicked NMDAR and GAD65 as a spectrum of the neuropathology in COVID-19.<sup>1,6</sup>

We suggest considering AE as a differential diagnosis in patients with similar presentations and making allowances of unusual antibodies as the cause of the encephalitis.

## Funding

This research did not receive any specific grant from funding agencies in the public, commercial, or not-for-profit sectors.

## Conflicts of interest

The authors declare no conflict of interest.

## Acknowledgments

We thank the patient for providing consent to share his clinical history. Informed consent was obtained from the patient.

## References

1. Dalmau J, Graus F. Antibody-mediated encephalitis. *N Engl J Med.* 2018;378:840–51, <http://dx.doi.org/10.1056/NEJMra1708712>.

2. McHattie AW, Coebergh J, Khan F, Morgante F. Palilalia as a prominent feature of anti-NMDA receptor encephalitis in a woman with COVID-19. *J Neurol.* 2021;1–3, <http://dx.doi.org/10.1007/s00415-021-10542-5>.
3. Kammeyer R, Piquet AL. Multiple co-existing antibodies in autoimmune encephalitis: a case and review of the literature. *J Neuroimmunol.* 2019;337:577084, <http://dx.doi.org/10.1016/j.jneuroim.2019.577084>.
4. Lee SK, Lee ST. The laboratory diagnosis of autoimmune encephalitis. *J Epilepsy Res.* 2016;6:45–50, <http://dx.doi.org/10.14581/jer.16010>. Published online 2016 Dec 31.
5. Sheu TT, Chiang BL. Lymphopenia, lymphopenia-induced proliferation, and autoimmunity. *Int J Mol Sci.* 2021;22:4152, <http://dx.doi.org/10.3390/ijms22084152>.
6. Al-Sarraj S, Troakes C, Hanley B, Osborn M, Richardson MP, Hotopf M, et al. Invited review: The spectrum of neuropathology in COVID-19. *Neuropathol Appl Neurobiol.* 2021;47:3–16, <http://dx.doi.org/10.1111/nan.12667>.

J. Valadez-Calderon<sup>a,b</sup>, A. Ordinola Navarro<sup>a,b</sup>, E. Rodriguez-Chavez<sup>c</sup>, O. Vera-Lastra<sup>a,b,\*</sup>

<sup>a</sup> *Department of Internal Medicine, Hospital de Especialidades "Dr. Antonio Fraga Mouret", Centro Médico Nacional La Raza, Mexico City, Mexico*

<sup>b</sup> *Division of Postgraduate Studies, Universidad Nacional Autónoma de Mexico City, Mexico, Mexico*

<sup>c</sup> *Department of Neurology and Neuroimmunology Clinic, Hospital de Especialidades "Dr. Antonio Fraga Mouret", Centro Médico Nacional La Raza, Mexico City, Mexico*

\* Corresponding author.

E-mail address: [olgavera62@yahoo.com.mx](mailto:olgavera62@yahoo.com.mx) (O. Vera-Lastra).

<https://doi.org/10.1016/j.nrl.2021.09.003>  
2173-5808/

© 2021 Sociedad Española de Neurología. Published by Elsevier España, S.L.U. This is an open access article under the CC BY-NC-ND license (<http://creativecommons.org/licenses/by-nc-nd/4.0/>).

## Haemorrhage within the cavity of a porencephalic cyst: a haemorrhagic complication in a patient with COVID-19<sup>☆</sup>



## Hemorragia en el interior de la cavidad de un quiste porencefálico: una complicación hemorrágica en paciente con COVID-19

Dear Editor:

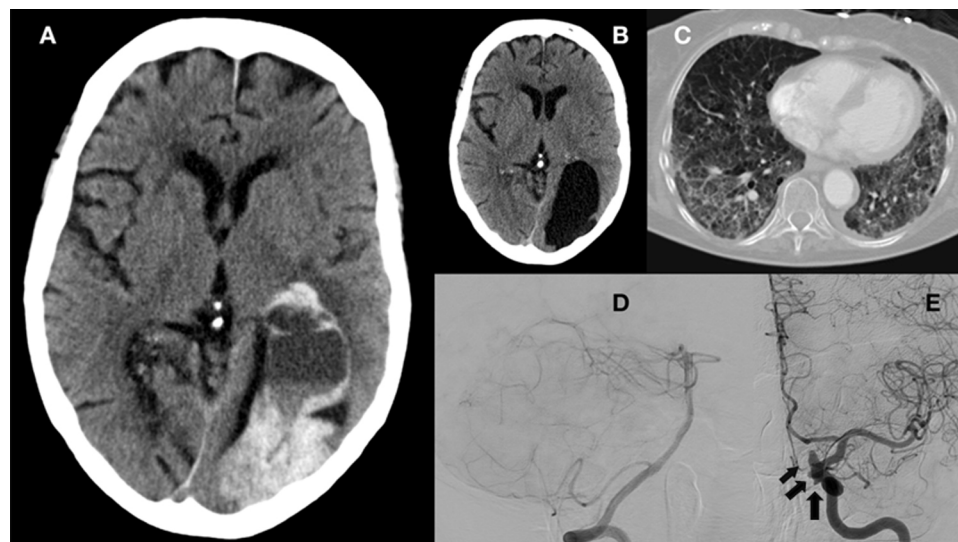
SARS-CoV-2 was first described in patients with atypical pneumonia in Wuhan (China).<sup>1</sup> Subsequent studies have addressed

the complications associated with coagulation disorders, due to their frequency and severity.<sup>2</sup> Among these disorders, haemorrhagic complications, though less frequent than thrombotic complications, are associated with high rates of morbidity and mortality and force us to assess the risk and benefits of starting or maintaining anticoagulation therapy.

We present the case of a 74-year-old woman, a former smoker, with personal history of arterial hypertension and dyslipidaemia. She had been under follow-up by the neurology department since 2019 due to stroke in the territory of the right posterior cerebral artery, which resulted in left homonymous hemianopsia; stroke aetiology was undetermined according to the aetiological study. The study incidentally detected a porencephalic cyst in the left parieto-occipital region, measuring 6.5 × 3.5 cm.

In March 2020, the patient visited the emergency department due to respiratory symptoms; a PCR test of nasopharyngeal exudate detected SARS-CoV-2. She was initially admitted to the intensive care unit and subsequently transferred to the respiratory intermediate care unit, where she presented an episode of paroxysmal atrial fibrillation; treatment was started with low-molecular weight heparin dosed at 60 mg every 12 hours (patient weight: 60 kg).

<sup>☆</sup> Please cite this article as: Muro I, Ramos C, Barbosa A, Vivancos J. Hemorragia en el interior de la cavidad de un quiste porencefálico: una complicación hemorrágica en paciente con COVID-19. *Neurología.* 2022;37:504–507.



**Figure 1** A) Brain CT showing a porencephalic cyst in the left parieto-occipital region displaying haemorrhage ( $8.5 \times 4 \times 7$  cm) and causing moderate mass effect, obliterating the left temporal, parietal, and occipital sulci, and causing anterior displacement of the left lateral ventricle. Blood content was observed in the body and temporal horn of the left lateral ventricle. Gliosis and malacia in the right paramedian occipital region, associated with an old stroke in the territory of the right posterior cerebral artery. B) Brain CT scan performed 3 months before admission due to COVID-19, revealing a porencephalic cyst in the left parieto-occipital region and an area of gliosis and malacia in the right paramedian occipital lobe, with no evidence of bleeding. C) Chest CT scan performed during hospitalisation, showing multiple ground-glass opacities in both lungs, more prominent in pressure areas. D) Brain angiography (right vertebral artery injection) showing normal morphology of the basilar and posterior cerebral arteries. E) Brain angiography showing several aneurysms along the internal carotid artery (black arrow). The first aneurysm measured  $3.6 \times 3.6$  mm, with a neck of 2.7 mm, and was located on the posterior aspect of the cavernous segment. The second measured  $3.09 \times 1.1$  mm, with a neck of 2.3 mm, and was located on the posterolateral aspect of the clinoid segment. The third measured  $2.5 \times 5.2$  mm, with a neck of 3.7 mm, and was located on the superior aspect of the ophthalmic segment.

Ten days after onset of anticoagulation therapy, and 45 days after diagnosis of COVID-19, the patient presented mixed aphasia of unknown origin, with arterial blood pressure of 130/90 mm Hg and preserved consciousness. Code stroke was activated. Head CT detected a haemorrhage within the cavity of the porencephalic cyst (Fig. 1). A CT angiography study of the circle of Willis showed no underlying vascular alterations, and a contrast study found no signs of active bleeding. In the preceding days, the patient had presented elevated levels of D-dimer (up to 1.54  $\mu\text{g}/\text{mL}$ ; normal range, 0.15-0.50), fibrinogen (524 mg/dL; normal range, 150-400), and LDH (308 U/L; normal range, 135-214), with a platelet count of 242 000/ $\mu\text{L}$  (normal range, 150 000-350 000); prothrombin and partial thromboplastin times were within the normal range.

In view of these findings, the patient was assessed by the neurosurgery team, who ruled out surgery, and anticoagulation therapy was suspended.

The aetiological study also included a brain angiography study, which revealed aneurysms with irregular borders in the territory of the left internal carotid artery, but no vascular anomalies of the posterior circulation that might explain the haemorrhage (Fig. 1).

Twenty-eight days after the haemorrhage, the patient was diagnosed with pulmonary thromboembolism (PTE) in the segmental arteries of the right lung. After assessing the risks and benefits of anticoagulation therapy, we opted for inferior vena cava filter placement.

At the follow-up consultation 3 months after the stroke, aphasia had resolved.

## Discussion

Several hypotheses have attempted to explain the aetiopathogenic mechanisms of coagulation disorders in patients with COVID-19. One such hypothesis is based on the virus' affinity for the angiotensin-converting enzyme 2 (ACE2) receptor, associated with increased prothrombotic and proinflammatory activity of angiotensin II. Other potential mechanisms include immune system activation with macrophage activation and cytokine release, and vasculitis.<sup>3</sup>

Regarding the virus' affinity for the ACE2 receptor, some authors suggest that ACE2 dysregulation may cause alterations in blood pressure and consequently hypertensive haemorrhages. Other authors postulate virus-induced endothelial damage,<sup>4</sup> a prothrombotic state due to decreased levels of coagulation factors, and such concomitant factors as kidney disease or anticoagulation therapy.<sup>3</sup> Furthermore, haemorrhagic complications may occur in the context of cerebral venous thrombosis or haemorrhagic transformation of stroke.<sup>5</sup>

Guidelines on anticoagulation therapy in patients with COVID-19 are constantly being reviewed and updated, and recommend prophylactic anticoagulation in patients with COVID-19 and no contraindications; the dose should be adjusted in patients without contraindications but presenting higher thrombotic risk.<sup>6</sup>

Few studies analyse the clinical characteristics of patients presenting brain haemorrhages in the context of COVID-19. One case series reported a mean age of 52.2 years, history of arterial hypertension, lobar localisation affecting the anterior circulation, and a mean of 32 days from symptom onset to haemorrhage.<sup>7</sup> Our patient, in contrast, was considerably older; symptoms appeared 45 days after diagnosis of COVID-19 and the location of the haemorrhage was atypical (within a porencephalic cyst).

The unusual location of the haemorrhage in our patient is noteworthy. Porencephalic cysts are defined as cerebrospinal fluid accumulation in a cavity in the brain parenchyma that communicates with the ventricular system, the subarachnoid space, or both.

These lesions may be congenital or acquired. In adults, they are found incidentally on brain imaging studies and are rarely associated with complications; when complications do present, they are typically epileptic seizures, focal neurological signs, and low intelligence quotient.<sup>8</sup>

The literature includes reports of intracystic and subdural haemorrhage in arachnoid cysts. These cysts, unlike porencephalic cysts, are located between the brain surface and the skull, within the arachnoid membrane, and do not communicate with the ventricular system. The most widely accepted aetiopathogenic hypothesis for intracystic haemorrhage is traumatic injury to the walls of vessels surrounding the cyst.<sup>9</sup> Cases have also been reported of intracystic haemorrhage secondary to aneurysm rupture; this is rare, however. In these cases, it has been suggested that haemorrhage may be explained by the proximity between the vessel wall and the cyst wall, combined with arterial pulsatility.<sup>10</sup>

To our knowledge, however, no cases have been reported of intracystic haemorrhage in patients with porencephalic cysts.

The aetiological study failed to determine the cause of the haemorrhage in our patient, and we were unable to rule out an association with coagulation disorders secondary to COVID-19 or anticoagulation therapy. In view of the location of aneurysms in the carotid artery territory, which were not contiguous with the cyst, and in the absence of haemorrhage at other locations, we may rule out aneurysm rupture as the cause of intracystic bleeding.

The patient also presented thromboembolic complications after anticoagulant discontinuation, which underscores the complexity of managing anticoagulation therapy in patients with COVID-19.

## Conclusions

Cerebral haemorrhage is a rare complication of COVID-19 but may be associated with poor outcomes, further complicating the challenge of anticoagulation therapy in patients with severe infection. This case demonstrates that cerebral haemorrhage may occur at such atypical locations as within the cavity of porencephalic cysts.

## Funding

This study received no funding of any kind.

## Conflicts of interest

The authors have no conflicts of interest to declare.

## References

- Zhu N, Zhang D, Wang W, Li X, Yang B, Song J, et al. China Novel Coronavirus Investigating and Research Team. A novel coronavirus from patients with pneumonia in China. *N Engl J Med*. 2020;382:727–33.
- Boccia M, Aronne L, Celia B, Mazzeo G, Ceparano M, D'Agnano V, et al. COVID-19 and coagulative axis: review of emerging aspects in a novel disease. *Monaldi Arch Chest Dis*. 2020;90, <http://dx.doi.org/10.4081/monaldi.2020.1300>.
- Tsivgoulis G, Palaiodimou L, Zand R, Lioutas VA, Krogias C, Katsanos AH, et al. COVID-19 and cerebrovascular diseases: a comprehensive overview. *Ther Adv Neurol Disord*. 2020;13, <http://dx.doi.org/10.1177/1756286420978004>.
- Paniz-Mondolfi A, Bryce C, Grimes Z, Gordon RE, Reidy J, Lednický J, et al. Central nervous system involvement by severe acute respiratory syndrome

- coronavirus-2 (SARS-CoV-2). *J Med Virol.* 2020;92:699–702, <http://dx.doi.org/10.1002/jmv.25915>.
5. Vogrig A, Gigli GL, Bnà C, Morassi M. Stroke in patients with COVID-19: Clinical and neuroimaging characteristics. *Neurosci Lett.* 2020;743:135564, <http://dx.doi.org/10.1016/j.neulet.2020.135564>.
  6. Tiwari NR, Khatib KI, Dixit SB, Rathore PK, Melinker S, Ganapule A, et al. Anticoagulation in COVID-19. An Update. *J Crit Care Med (Targu Mures).* 2020;6:217–23, <http://dx.doi.org/10.2478/jccm-2020-0033>.
  7. Bengera M, Williams O, Siddiqui J, Sztrihaa L. Intracerebral haemorrhage and COVID-19: Clinical characteristics from a case series. *Brain Behav Immun.* 2020;88:940–4, <http://dx.doi.org/10.1016/j.bbi.2020.06.005>.
  8. Oommen AT, Sethy G, Minz NT, Patra J, Panda SS. Unusual presentation of porencephalic cyst in an adult. *J Clin Diagn Res JCDR.* 2017;11:OD12–3, <http://dx.doi.org/10.7860/JCDR/2017/22654.9374>.
  9. Van Burken MMG, Sarioglu AC, O'Donnell HD. Supratentorial arachnoidal cyst with intracystic and subdural haematoma. *Neurochirurgia.* 1992;35:199–203, <http://dx.doi.org/10.1055/s-2008-1052278>.
  10. Brasileiro de Aguiar G, Gomes Dos Santos R, Campos Paiva AL, de Almeida Silva JM, da Silva RC, Esteves Veiga JC. Intracranial aneurysm and arachnoid cyst : just a coincidence? A case report. *Sao Paulo Med J.* 2019;137:92–5, <http://dx.doi.org/10.1590/1516-3180.2017.0083290517>.
- I. Muro<sup>a,\*</sup>, C. Ramos<sup>a</sup>, A. Barbosa<sup>b</sup>, J. Vivancos<sup>a</sup>
- <sup>a</sup> *Servicio de Neurología, Hospital Universitario de La Princesa, Instituto de Investigación Sanitaria Princesa, Madrid, Spain*  
<sup>b</sup> *Servicio de Radiodiagnóstico, Hospital Universitario de La Princesa, Madrid, Spain*
- \* Corresponding author.  
 E-mail address: [ines.muro@gmail.com](mailto:ines.muro@gmail.com) (I. Muro).
- <https://doi.org/10.1016/j.nrleng.2021.09.003>  
 2173-5808/  
 © 2021 Sociedad Española de Neurología. Published by Elsevier España, S.L.U. This is an open access article under the CC BY-NC-ND license (<http://creativecommons.org/licenses/by-nc-nd/4.0/>).

## Bilateral chorea as a manifestation of cerebral venous sinus thrombosis associated with COVID-19<sup>☆</sup>



## Corea bilateral como forma de presentación de trombosis venosa cerebral asociada a COVID-19

Dear Editor:

Cerebral venous sinus thrombosis (CVST) is a rare cause of stroke. To date, some cases have been reported in association with SARS-CoV-2 infection, which appears to increase the incidence of thrombotic phenomena.<sup>1–4</sup> We present a patient with bilateral chorea as an initial symptom of COVID-19-associated CVST. The patient was a 69-year-old woman with history of fatty liver disease and fibromyalgia, who was admitted to hospital with bilateral pneumonia due to SARS-CoV-2 infection; she tested positive for IgG antibodies and was under prophylactic treatment with enoxaparin sodium. On day 21, she awoke with mixed aphasia, mild right hemiparesis, and choreic movements in all 4 limbs (video in Supplementary material), leading to in-hospital code stroke activation.

The CT/CT angiography study (Fig. 1) identified capsuloganglionic and thalamic infarcts bilaterally, with thrombosis of the lateral veins, left lateral sinus, straight sinus, and vein of Galen. Blood analysis showed elevated D-dimer levels (3160 µg/L), without thrombocytopenia. The patient was prescribed anticoagulation with enoxaparin. Progression over the following

24 hours was unfavourable, with persistence of choreic movements and a progressive decrease in the level of consciousness. A second head CT study (Fig. 2A) suggested haemorrhagic transformation of the left thalamic infarct.

In the light of the clinical worsening, we decided to perform arteriography and mechanical thrombectomy, achieving partial recanalisation (Fig. 2B). During the procedure, the patient presented a hypertensive peak with arreactive bilateral mydriasis, which persisted despite measures to reduce oedema. An additional head CT scan showed no changes with respect to the previous study. The patient eventually died. We were not able to collect blood samples for antiphospholipid antibody determination or a thrombophilia study.

This case presents 2 noteworthy characteristics. The first is the association between CVST and COVID-19. CVST accounts for 0.5% to 1% of cases of stroke, with an estimated incidence of 1.6 cases per 100 000 person-years. It usually affects young patients, with a woman-to-man ratio of 3:1.<sup>5,6</sup> Risk factors include hormonal factors, inherited or acquired hypercoagulable states, and infections.<sup>5</sup> Clinical presentation depends on the territory involved; the most frequent symptoms are headache, focal neurological deficits, seizures, and diffuse encephalopathy. Treatment with low-molecular weight heparin is recommended, although the ideal treatment duration and the role of oral anticoagulants are not well established.<sup>6</sup> Endovascular treatment should be considered in severe cases with clinical worsening or lack of improvement despite anticoagulation treatment, and is associated with a higher rate of intracranial haemorrhagic complications.<sup>5,6</sup>

In the last year, SARS-CoV-2 infection has been associated with an increased risk of thrombotic events, including CVST. While deep vein thrombosis and arterial thrombosis appear to be more common in patients with moderate-severe respiratory tract infections, CVST also occurs in patients with mild symptoms. Among the reported cases, incidence appears to be similar between sexes; patients tend to be middle-aged and not present relevant comorbidities.<sup>1–4</sup> The risk of thrombotic events persists for several weeks after resolution of infectious symptoms.<sup>7</sup> Thrombosis associated with COVID-19 seems to be explained by endothelial damage mediated by the virus' inter-

<sup>☆</sup> Please cite this article as: Revert Barberà A, Estragués Gazquez I, Beltrán Márml MB, Rodríguez Campello A. Corea bilateral como forma de presentación de trombosis venosa cerebral asociada a COVID-19. *Neurología.* 2022;37:507–509.