



Revista Colombiana de Anestesiología

Colombian Journal of Anesthesiology

www.revcolanest.com.co



Case report

Two cases of refractory writer's cramp in pain clinic: Is botulinum the answer? ☆

Preet Mohinder Singh*, Anjan Trikha

Anesthesiologist. All India Institute of Medical Sciences, New Delhi, India

ARTICLE INFO

Article history:

Received 9 June 2012

Accepted 13 December 2012

Available online 9 February 2013

Keywords:

Botulinum for focal dystonia

Writer's cramp

Botulinum in pain clinic

ABSTRACT

Introduction: Writer's cramp is a refractory painful disorder, often presenting as a disabling disease while writing for a short duration. The conventional therapy in the form of neurogenic agents such as carbamazepine often fails to benefit these patients. Modern literature has highlighted the used of botulinum toxin in focal dystonias and hence its use can also be extrapolated in patients of writer's cramps.

AIM: Evaluating the efficacy and safety of botulinum toxin in refractory writer's cramps.

Methodology: We present 2 cases of diagnosed refractory writer's cramp. These patients were evaluated for group of hand muscles involved. Once the muscles were identified, botulinum toxin was injected into these muscles and clinical response was used to iterate the total dose of botulinum needed. These patients were followed up for degree of relief and any associated adverse effects.

Results: Both patients showed significant clinical relief after the use of botulinum toxin. Their writing time improved and both patients reported a significant pain relief. The patients required repeat injection after 3–6 months, however with each reoccurrence their ailment decreased and they could be taken off oral medication.

Minor clinically insignificant reversible weakness was seen in one patient, which reverted to normal in 2–3 weeks time which did not affect patients' satisfaction to treatment, as the primary disease was disabling for daily professional work.

Conclusion: Botulinum toxin is a safe and effective therapeutic option for treating patients of refractory writer's cramp presenting in the pain clinic.

© 2012 Sociedad Colombiana de Anestesiología y Reanimación. Published by Elsevier España, S.L. All rights reserved.

Dos casos de calambre refractario del escribano en la clínica de dolor: ¿está la respuesta en la toxina botulínica?

RESUMEN

Introducción: El calambre del escribano es un trastorno doloroso refractario que suele manifestarse como enfermedad incapacitante tras un período corto de escritura. La terapia convencional con agentes neurogénicos como la carbamazepina muchas veces no beneficia a estos pacientes. En la literatura moderna se ha resaltado el uso de la toxina botulínica en

Palabras clave:

Toxina botulínica para distonía focal

Espasmo del escribano

Toxina botulínica en la clínica de dolor

* Please cite this article as: Singh PM, Trikha A. Dos casos de calambre refractario del escribano en la clínica de dolor: ¿está la respuesta en la toxina botulínica? Rev Colomb Anestesiol. 2013;41:161–5.

* Corresponding author at: Hostel 7, Room 48, All India Institute of Medical Sciences, New Delhi, India.
E-mail address: Preetrajpal@gmail.com (P.M. Singh).

distonías focales, de manera que su uso también podría extrapolarse a los pacientes con espasmo del escribano.

Objetivo: Evaluar la eficacia y la seguridad de la toxina botulínica en casos de calambre refractario del escribano.

Metodología: Presentamos 2 casos de calambre refractario del escribano. Se evaluó a los pacientes para determinar el grupo de los músculos de la mano que estaban comprometidos. Una vez identificados los músculos se inyectó en ellos la toxina botulínica y se utilizó la respuesta clínica como base para determinar la dosis total requerida. Se hizo seguimiento a los pacientes a fin de evaluar el grado de alivio y cualquier efecto adverso asociado.

Resultados: Los 2 pacientes presentaron un grado significativo de alivio clínico tras la aplicación de la toxina botulínica. El tiempo de escritura mejoró y los 2 pacientes refirieron un alivio significativo del dolor. En ambos casos fue necesario repetir la inyección después de 3-6 meses, aunque la afección fue menor en cada recaída y fue posible suspenderles la medicación oral. Uno de los pacientes presentó leve debilidad de la mano, que tuvo un impacto clínico menor y revirtió a la normalidad en un lapso de 2-3 semanas. Este hecho no afectó la satisfacción de los pacientes con el tratamiento, considerando que la enfermedad primaria era incapacitante y afectaba el trabajo profesional de todos los días.

Conclusión: La toxina botulínica es una alternativa terapéutica segura y eficaz para tratar a los pacientes afectados con calambre refractario del escribano que consulten la clínica de dolor.

© 2012 Sociedad Colombiana de Anestesiología y Reanimación. Publicado por Elsevier España, S.L. Todos los derechos reservados.

Introduction

Writer's cramp is an uncommon form of focal dystonia limited to small muscles of hand. Patients present with not only debilitation spasm of hand muscles but also unpleasant aching pain in the hand and hence are referred to the pain clinic. A simple writer's cramp is only limited to hand and manifests only while writing whereas a dystonic writer's cramp may hamper in other daily activities such as combing or eating.^{1,2} The disease is often progressive and worsens with time if untreated.³ First described in 1830 by Bell and Burk² it was assumed to be a psychiatric neuroses only but research now has proved it to have an organic cause. Electromyography (EMG) has revealed abnormal prolonged bursts in agonistic and antagonistic muscles.^{4,5} Clinically patients present with progressive difficulty while writing. The grip on writing instrument tightens with ulnar deviation of hand. Patient also complains of simultaneously increasing dull cramping pain in the hand and he is unable to continue to write. The time of onset of episode depends on disease severity and on resting the hand pain and spasm wear off. One-third patients may present with fine tremors; however, a neurological examination reveals normal tendon reflexes in the affected hand of all patients.³

Pain physicians have reported successful treatment of writer's cramps with the use of botulinum toxin. We present our experience in two cases of refractory writer's cramp who responded to botulinum toxin injection after failed conventional neurology treatment. The use of botulinum for the above indication is in preliminary stages of development and needs more evidence to be incorporated in routine protocols for treatment.⁶ Our results highlight a promising role of botulinum in future for treating this refractory disabling disease.

Case 1

16-years-southpaw female high school student noticed difficulty in writing for the past one year. This difficulty had been increasing. Initially when it started she was able to write for around an hour but gradually this time had decreased to 5-10 min. At the onset of difficulty she felt her thumb started to get stiff and pencil began to slip towards fingers. The middle and index finger seemed to extend in spasm and she felt disabling cramping pain in her hand. She could not continue writing and had to take small breaks in between. Gradually these breaks were becoming longer and needed to be more frequent. She had appeared in 9th class examination where she was provided with a writer in view of the illness.

She initially presented to neurology where no abnormality could be documented on clinical examination. She also complained about redness at the onset of cramp. Which was believed to be more of subjective feeling as the mother denied any color change. She was evaluated for any vasculitis and possibility of Raynaud's phenomena leading to color change was ruled out. All other investigations were within normal limits. A psychiatric evaluation was done which suggested a likely organic cause of problem. The pain and stiffness were relieved completely in between the episodes and her writing charts made, which were suggestive of writer's cramp. No family history of such symptoms was there.

An EMG was obtained which further substantiated the diagnosis of writer's cramp. She was started on oral carbamazepine and baclofen, which she took for 2 months without any improvement. Subsequently she was referred to pain clinic due to associated cramping pain and possibility of use of botulinum toxin injections.

On examination of EMG pattern, involvement of flexor pollicis longus, flexor digitorum profundus, extensor carpi ulnaris




Fig. 1 – Hand posture case 1 after 15 min of writing prior to treatment.

and extensor pollicis was noted. Since she was refractory to conventional treatment use of botulinum toxin injection was planned for the above muscles. A total of 10 units for each large muscles of wrist were used. Since she had all 4 muscles involvement of wrist she received 40 units of botulinum into the belly of these muscles at different sites in divided doses. In 2 weeks time she had around 50% improvement in the writing time and her spasmodic pain also seemed to have improved.

We further supplemented the botulinum does by 5 units in each muscle again after 2 weeks of first injection. By the end of 3rd week her writing time had gone up to an hour and no pain was noticed anymore. She was followed up in the pain clinic and subsequently she required a repeat injection after 4 months with again re-normalization of her writing times. During this period no hand weakness was noticed. She is under regular follow-up since more than a year and is currently asymptomatic (Fig. 1).

Case 2

37-years-old male lawyer by profession noticed progressive difficulty in writing. Since last 2 years his ability to write had become severely effected. While writing he noticed that the thumb began to extend in spasm and loosening his grip on pen. His hand would flex at the wrist with an ulnar deviation,

which he could not control. This was accompanied by severe pain at the wrist. The painful cramp was limited to wrist with no radiation and the relieving factor noted was resting the limb in between writing. No other hand movements or repetitive work was associated with such episodic pain or posturing. Familial history revealed a possibility of such an ailment in his mother. She had died of an acute myocardial ischemia at age of 67 years. She had history of cramping pain while knitting for some time; however, she was not a literate so no history about writing associated cramp could be elicited.

His writing time was only now limited to 5 min and the pain re-appeared which was hampering severely in his professional work. While writing he needed frequent breaks to relieve spasm and associated pain. He had been worked up for all possible alternative diagnosis in neurology and a diagnosis of writer's cramp was made by exclusion. Electromyography revealed the involvement of extensor pollicis longus, flexor carpi ulnaris and flexor digitorum profundus. He had received multiple drugs in neurology but none of them showed any clinical improvement. He was referred to pain clinic for a trial of botulinum injection.

A total of 30 units of botulinum was injected into the 3 involved muscles with 10 units to each muscle at different locations into their belly. The writing time improved to 25 min in 2 weeks time. To achieve further improvement each muscle was injected with additional 5 units of botulinum (total of additional of 15 units). The writing time improved significantly to an hour and no further abnormal posturing of hand was noted. Subsequently in next 2 weeks patient complained of mild weakness in fingers while strong grip, which was attributed to possible weakness of flexor digitorum profundus. On follow-up this weakness resolved in the next month and a repeat session of botulinum injection was done 5 months later with 10 units in two muscles and 7.5 units in flexor digitorum profundus. The disease went into remission and patient has not needed a repeat injection since last 8 months (Fig. 2).

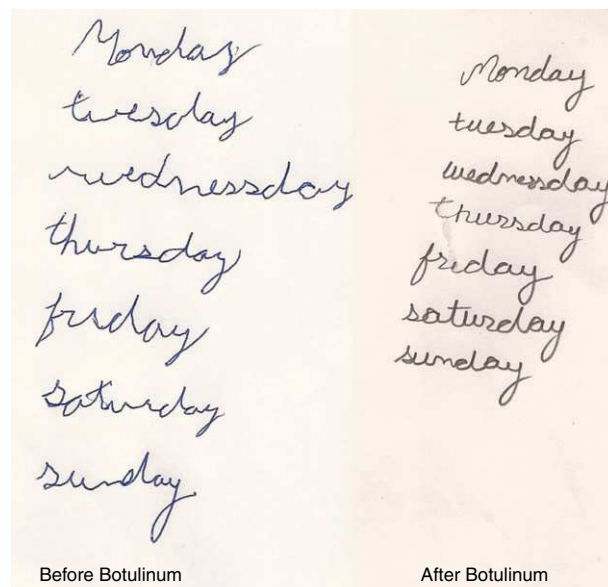


Fig. 2 – Case 2 – handwriting before and after the treatment.

Discussion

Botulinum toxin is of 7 types and its A and B forms are used in numerous clinical indications.⁷ Botulinum appears to work by weakening or paralyzing proportional capacity of skeletal muscles. On injecting therapeutic doses of botulinum it leads to partial motor denervation of the muscle. The initial action of botulinum toxin (BTX) on the muscle is dysfunction of alpha motor neurons that stimulate muscle fibers. It is also known to reduce innervation to gamma motor neurons distributed to muscle spindles thus breaking the reflex arc and decreasing the myotonic activity.⁸ Botulinum not only affects the muscles but it possesses analgesic activity as well. This is highlighted by its increasing use in various neuralgias.^{9,10} Its role in treating patients with refractory writer's cramps is thus probably bimodal. Muscle relaxing activity relieves the associated cramp but the analgesic activity lowers the pain associated.

Writer's cramp is a task specific focal dystonia. The pathophysiology recognized behind it is the failure of reciprocal inhibition. Normally when a group of muscles contract its antagonists relax as a reflex. It is the failure of this relaxation that causes continuous muscle contraction and thus cramping. This may be attributed to decreased sensitivity of sensory cortex to proprioception and increased excitability of motor cortex.¹¹ The group of muscles involved may vary from patient to patient and hence the abnormal posturing may also vary. In our patients the posturing was only limited to hand in the first one and involvement of wrist was seen in second. The known posturing and involved muscle can be inferred from clinical findings suggested by Rivest et al.⁶ Thus this posturing can help clinically decide the effected muscle and likelihood of use of botulinum in these muscles.

Writer's cramps most commonly involve patients in age group between 30 and 50 years. Our first patient was 16 years

only which could be possibly because the disease is often diagnosed in later stages and by the time an established diagnosis is made on patients who have received years of therapy.¹² Due to isolated involvement of hand and almost no complaints in between the episodes, diagnosing the writer's cramps conclusively is difficult. In both of our patients, it took 6 months to 1 year to diagnose their problem being writer's cramp. A differential diagnosis of Parkinsonism, multiple sclerosis and Wilson disease must be ruled out.¹³ MRI scan can be advised to localize any suspected anatomical cause of dystonia. Use of electromyography not only helps to consolidate the diagnosis but can also aid in deciding the muscles to be injected with botox. Involved muscles if can be clinically identified (as in Table 1), in those cases a routine EMG may even be skipped.⁶ The EMG results may also be difficult to interpret at times as the forearm has 23 groups of muscles; if one muscle group has abnormal increased tone there may be another group that may increase the tone to compensate for abnormal hand posturing, and this may not be recognized by EMG.¹⁴

Writer's cramps are refractory to commonly used neurological drugs¹⁵ as in our patients where no improvement occurred with months of treatment. Botulinum does not treat the central cause of disease but it can prevent peripheral manifestations, which are the main disability to the patient. By the time the effect of botulinum wears off, the disease can go into remission and thus may not need further therapy or repeat injections.⁶ This could be highlighted in our first case being asymptomatic since a year after last injection.

The dose of botulinum used is also of concern as Cohen et al. have pointed out that it does leave some degree to muscle weakness to have clinical action.¹⁶ We chose a small dose of 10 units and waited for 2 weeks to re-dose if needed as the peak action of botulinum occurs by 2 weeks¹⁷ and any injection given after this time is not likely to cause unexpected added weakness. The effect of single injection is likely to last for 6 weeks to 6 months¹⁸ and repeat injections needed during

Table 1 – Hand posturing and recommended muscle for botulinum injection.

Hand posture	Involved muscles recommended for botulinum injection
Forceful holding of pen with thumb and index finger	Flexor pollicis longus Flexor digitorum profundus
Thumb and index extend and lift of the pen	Extensor indicis proprius Extensor pollicis longus
Index and thumb extend and lift off the pen, slight extension and ulnar deviation of wrist	Extensor indicis proprius Extensor pollicis longus Extensor carpi ulnaris Flexor carpi ulnaris
Ulnar deviation and flexion of the wrist	
Forceful gripping of the pen between thumb and index, curling of last two fingers, severe ulnar deviation of the wrist, elbow flexion and abduction, lifting of the shoulder	Flexor pollicis longus Flexor digitorum profundus Flexor carpi ulnaris Extensor carpi ulnaris
Curling of the index finger with flexion of the wrist	Flexor digitorum profundus Flexor carpi ulnaris Flexor carpi radialis

Source: Adapted from Rivest J, Lees AJ, Marsden CD. Writer's cramp: treatment with botulinum toxin injections. *Mov Disord.* 1991;6:55-9.

this period may be additive to weakness and hence we advice to use lower doses and subsequent titration to clinical effect.

The use of botulinum in writer's cramp is documented in isolated case reports in literature and with our successful treatment of these two cases we will like to highlight its likely hood of becoming an established treatment of this rare refractory disorder for future.

Funding

The authors have not availed any external funding.

Conflicts of interest

The authors state no conflicts of interest.

REFERENCES

- Marsden CD, Sheehy MP. Writer's cramp. *Trends Neurosci.* 1990;13:148-53.
- Sheehy MP, Marsden CD. Writers' cramp – a focal dystonia. *Brain.* 1982;105:461-80.
- Rhoad RC, Stern PJ. Writer's cramp – a focal dystonia: etiology, diagnosis, and treatment. *J Hand Surg Am.* 1993;18:541-4.
- Cordivari C, Lees AJ, Misra VP, Brown P. EMG-EMG coherence in writer's cramp. *Mov Disord.* 2002;17:1011-6.
- Kristeva R, Chakarov V, Losch F, Hummel S, Popa T, Schulte-Mönting J. Electroencephalographic spectral power in writer's cramp patients: evidence for motor cortex malfunctioning during the cramp. *Neuroimage.* 2005;27:706-14.
- Rivest J, Lees AJ, Marsden CD. Writer's cramp: treatment with botulinum toxin injections. *Mov Disord.* 1991;6:55-9.
- Setler PE. Therapeutic use of botulinum toxins: background and history. *Clin J Pain.* 2002;18 6 Suppl.:S119-24.
- Freund B, Schwartz M. Temporal relationship of muscle weakness and pain reduction in subjects treated with botulinum toxin A. *J Pain.* 2003;4:159-65.
- Linde M, Hagen K, Stovner LJ. Botulinum toxin treatment of secondary headaches and cranial neuralgias: a review of evidence. *Acta Neurol Scand Suppl.* 2011;191:50-5.
- Wu C-J, Lian Y-J, Zheng Y-K, Zhang H-F, Chen Y, Xie N-C. Botulinum toxin type A for the treatment of trigeminal neuralgia: results from a randomized, double-blind, placebo-controlled trial. *Cephalalgia.* 2012. Available from: <http://www.ncbi.nlm.nih.gov/pubmed/22492424> [Internet, cited 2012 May 14].
- Weise D, Gentner R, Zeller D, Nagel A, Reinsberger C, Rumpf J-J, et al. Focal hand dystonia: lack of evidence for abnormality of motor representation at rest. *Neurology.* 2012;78:122-8.
- Writer's Cramp; 2012. Available from: <http://emedicine.medscape.com/article/1154398-overview#a0199> [cited 2012 May 14].
- Gordon NS. Focal dystonia with special reference to writer's cramp. *Int J Clin Pract.* 2005;59:1088-90.
- Jankovic J, Schwartz K. Botulinum toxin injections for cervical dystonia. *Neurology.* 1990;40:277-80.
- Taira T, Harashima S, Hori T. Neurosurgical treatment for writer's cramp. *Acta Neurochir Suppl.* 2003;87:129-31.
- Cohen LG, Hallett M, Geller BD, Hochberg F. Treatment of focal dystonias of the hand with botulinum toxin injections. *J Neurol Neurosurg Psychiatr.* 1989;52:355-63.
- Panicker JN, Muthane UB. Botulinum toxins: pharmacology and its current therapeutic evidence for use. *Neurol India.* 2003;51:455-60.
- Truong DD, Stenner A, Reichel G. Current clinical applications of botulinum toxin. *Curr Pharm Des.* 2009;15:3671-80.