

# Revista Colombiana de Anestesiología

## Colombian Journal of Anesthesiology

www.revcolanest.com.co



### Essay

## Anesthesia for awake craniotomy: An update<sup>☆</sup>



Jason Chui\*

Assistant Professor, Department of Anesthesia and Perioperative Medicine, University of Western Ontario, Ontario, Canada

#### ARTICLE INFO

##### Article history:

Received 26 May 2014

Accepted 8 July 2014

Available online 3 September 2014

##### Keywords:

Craniotomy

Epilepsy

Brain neoplasms

Anesthesia

Perioperative period

#### ABSTRACT

Awake craniotomy has become a common procedure and its application has been continually evolving. Anesthesia for awake craniotomy poses a unique challenge to anesthesiologists. The aims of this article are to review under a critical perspective of the author, the current evidence and application of awake craniotomy and to briefly describe the principles of anesthetic management during this procedure.

© 2014 Sociedad Colombiana de Anestesiología y Reanimación. Published by Elsevier España, S.L.U. All rights reserved.

#### Anestesia para craneotomía en el paciente despierto: una actualización

#### RESUMEN

La craneotomía en el paciente despierto se ha generalizado y su aplicación ha evolucionado continuamente. La anestesia para este procedimiento plantea un reto singular para los anestesiólogos. Son revisar, bajo una perspectiva crítica del autor, la evidencia actual y la aplicación de la craneotomía en el paciente despierto, y describir brevemente los principios del manejo anestésico durante el procedimiento.

© 2014 Sociedad Colombiana de Anestesiología y Reanimación. Publicado por Elsevier España, S.L.U. Todos los derechos reservados.

##### Palabras clave:

Craneotomía

Epilepsia

Neoplasias encefálicas

Anestesia

Periodo perioperatorio

<sup>☆</sup> Please cite this article as: Chui J. Anestesia para craneotomía en el paciente despierto: una actualización. Rev Colomb Anestesiolog. 2015;43:22-28.

\* Correspondence to: Department of Anesthesia and Perioperative Medicine, University of Western Ontario, 339 Windermere Road, London, ON, Canada N6A 5A5.

E-mail address: [jasonswchui@gmail.com](mailto:jasonswchui@gmail.com)

2256-2087/© 2014 Sociedad Colombiana de Anestesiología y Reanimación. Published by Elsevier España, S.L.U. All rights reserved.

**Table 1 – Current indications for awake craniotomy.**

Indication	Rationale	Examples
Awake functional cortical mapping	An awake and cooperative state is required for performing the required tasks	Lesions located in close proximity to the eloquent area (e.g., tumor resection and lesionectomy) Vascular lesions that supply the eloquent area (e.g., AVM and aneurysm excision)
Electrophysiological mapping and recording	Cortical or subcortical signals are easily abolished by anesthetic agents	Intraoperative electrocorticography Deep brain stimulation
Improving perioperative outcomes	Non-functional purposes aiming at earlier discharges, reduced lengths of stay, and reduced ICU admissions	Stereotactic brain biopsy, ventriculostomy and resection of small brain lesions

Source: Author.

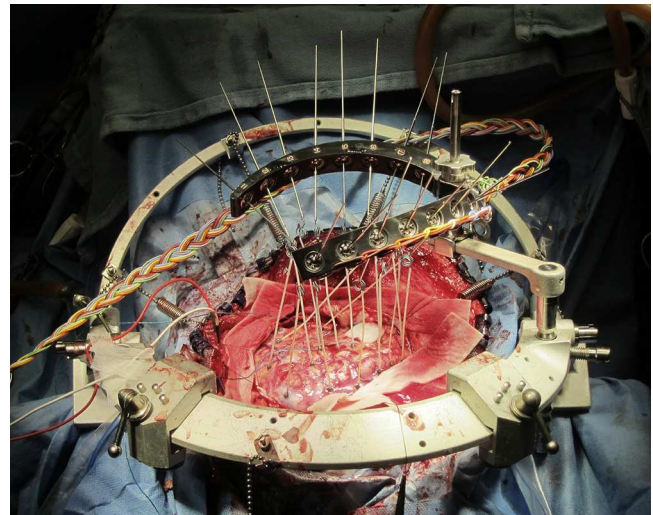
## Introduction

Awake craniotomy poses a unique challenge to anesthesiologists, and its success is highly dependent on careful patient selection and the experience of the surgical and anesthesia team. The modern era of awake craniotomies began more than 50 years ago when Penfield and Andre Pasquet started to perform awake craniotomies for epileptic foci excision.<sup>1</sup> Historically, anesthesia for awake craniotomy was regarded as a high-risk procedure and was only performed when it was absolutely indicated. With the improved understanding of cerebral localization and the availability of new anesthetic agents, the application of awake craniotomy has become much broader and safer than before. The aims of this article are to review the current evidence and application of awake craniotomy and to briefly describe the principles of anesthetic management during this procedure.

## Indication for awake craniotomy

The current indications for awake craniotomy are listed in Table 1. The use of awake craniotomy with electrocorticography in surgical excision of intractable epileptic foci has been started by Penfield since 1950s.<sup>1</sup> Electrocorticography is an invasive electrophysiological technique for the direct recording of the cortical potentials from the surface of the brain to localize seizure foci (Fig. 1). However, intraoperative electrocorticography is greatly affected by the anesthetic agents, and awake craniotomy is indicated to minimize pharmacological interference with the recordings.<sup>2</sup> With the advancement of pre-surgical imaging techniques, the use of intraoperative electrocorticography for localization and hence the associated use of awake craniotomy for this purpose have been markedly reduced.

Currently, awake craniotomy is commonly indicated for procedures that require awake functional cortical mapping, where the lesion is located in close proximity to the eloquent cortical tissues that are indispensable for defined cortical functions. The motor, sensory, visual and language cortex have been successfully mapped during awake craniotomy.<sup>3,4</sup> Tailored resection can be performed to preserve the patients' function. A typical example of this category is a glioma resection in the motor or Broca's area.



**Fig. 1 – Medussa (or Montreal) frame for intraoperative electrocorticographic recording.**

Source: Author.

The availabilities of propofol and ultrashort-acting opioids that permit rapid and smooth anesthetic control have led to the establishment of a wide application of awake craniotomy in neurosurgical patients, irrespective of the requirement for functional cortical mapping or electrophysiological recording. During the 1990s, awake craniotomy was advocated for ambulatory procedures.<sup>5</sup> The indication for awake craniotomy has already been extended from procedures necessitating awake functional mapping to methods aiming to improve perioperative outcomes and to minimize resource utilization, including stereotactic brain biopsy, ventriculostomy and the resection of small brain lesions.<sup>5,6</sup> In some centers, awake craniotomy has already been used routinely and non-selectively in the majority of patients for supratentorial tumor excision.<sup>7</sup>

## Current evidence for awake craniotomy

The major benefit of awake craniotomy is to enable a tailored resection that can theoretically maximize the extent of the tumor resection and can minimize the neurological damage. The current supporting evidence is mainly based on prospective cohort and retrospective chart reviews.<sup>8</sup> One of the recent

large population cohort studies, involving 575 patients, has compared the gross total resection rate and postoperative neurological deficits between awake craniotomy and general anesthesia patients.<sup>9</sup> Awake craniotomy was associated with a higher gross total resection rate in the eloquent area (37% vs 14%,  $p < 0.05$ ), fewer permanent neurological deficit (4.6% vs 16%,  $p < 0.001$ ) and fewer new-onset postoperative neurological deficits (3.3% vs 58% of patients,  $p < 0.001$ ). However, these benefits were not consistently demonstrated by other studies, particularly for the prevention of neurological deficits.<sup>8</sup> Interestingly, the only available randomized controlled study on this topic revealed that general anesthesia yielded fewer and non-significant neurological deficits.<sup>10</sup>

The evidence supporting awake craniotomy in earlier hospital discharges are more consistent, and nearly all the previous studies have demonstrated shorter hospital stays for awake craniotomy patients. The additional benefits include shorter ICU stays, a shorter total length of stay, less resource utilization and high patient satisfaction.<sup>7,8</sup>

## Perioperative management

### Preoperative preparation

Careful patient selection is one of the major components of successful awake craniotomy. The selection should be individualized and based on the airway assessment, risks of sedation failure, patient's cooperation and the risks of intraoperative surgical complications such as bleeding. A history of alcohol or drug abuse, chronic pain disorders, low tolerance to pain and anxiety or psychiatric disorders are known risk factors for sedation failure.<sup>11</sup> The selection of patients presenting with seizures or mixed dysphasia, having a history of using multiple anti-convulsants or undergoing perioperative loading of phenytoin is associated with the loss of intraoperative cooperation and results in failed awake craniotomies.<sup>12</sup> Well-motivated and mature patients are the best candidates for awake craniotomy. There was also a recent pilot study of using objective psychological and psychophysiological test to select their patients.<sup>13</sup> Although there are reports of the safe use of awake craniotomy in pediatric patients, the case selection should be more rigorous and based on the patients' maturity and the individual risk-benefit assessment.<sup>14</sup>

Preoperative psychological preparation and rapport building are the important components of preoperative preparation. The preoperative discussion should include a realistic description of the entire procedure, the expected discomforts, the level of cooperation desired, the tasks that must be performed and the possibility of adverse events. A well-conducted preoperative consultation usually can alleviate the patient's anxiety and improve his or her cooperation during the awake craniotomy.

### Intraoperative management

There are three major anesthetic challenges for awake craniotomy: (i) provision of a rapid and smooth transition of the anesthetic depth according to the different surgical stages, (ii) maintenance of stable cerebral hemodynamic and

cardiopulmonary function, and (iii) crisis management for an awake patient with an open cranium. The requirement regarding the depth of anesthesia varies markedly at the different stages of surgery. Over-sedation may lead to apnea, hypoxemia, hypercapnia and cerebral swelling, whereas under-sedation may result in agitation, arterial hypertension and tachycardia. The common anesthetic goals for all neurosurgical patients, such as the avoidance of hypercapnia and hypoxemia, adequate cerebral perfusion pressure and brain relaxation, may not be easily achieved in awake craniotomy patients with uncontrolled airways.

Adequate local anesthesia can usually be achieved by either using a scalp block or a regional field block. Arterial line is commonly used; but other invasive monitoring, such as central venous lines, is not routinely required. Comfortable positioning is mandatory because extremely limited movements will be possible after the head-pinning. The draping should always allow easy access to the patient's face and airway. A microphone may be used to facilitate communication with the staff.

### Choice of anesthetic techniques

Various institutions and anesthesiologists have their own favored techniques for awake craniotomies, including local anesthesia, conscious sedation, asleep-awake-asleep techniques and asleep-awake techniques. None of these techniques has any demonstrated superiority. In the asleep-awake-asleep techniques, the patient is under general anesthesia, with the use of a laryngeal mask airway or endotracheal intubation during the positioning, head-pinning and craniotomy. The general anesthesia is discontinued for the period of functional cortical mapping and intraoperative electrocorticography. After the complete resection, the patient is put back under general anesthesia for the skin closure.<sup>15</sup> In the asleep-awake technique, the patient is kept awake throughout the rest of the procedure, with the flexibility of permitting additional mapping if symptoms develop.<sup>16</sup> By contrast, for conscious sedation, the patient is maintained with spontaneous breathing throughout the entire procedure, and the sedatives and analgesics are titrated based on the surgical stages.

### Choice of anesthetic agents

The choice of anesthetic agents for awake craniotomy is highly dependent upon the requirement for functional cortical mapping and intraoperative electrocorticography. Intraoperative electrocorticography recordings are highly affected by different anesthetics, and the choice of anesthetic agents should have minimal effects on the suppression and over-activation. Complete cessation of all anesthetic agents for 20–30 min prior to the electrocorticography has been recommended; however, this recommendation may not be feasible in all cases of awake craniotomy, and general anesthesia may even be necessary in some patients. A detailed discussion of the effects of anesthetics on electrocorticography is beyond the scope of this article, and readers can refer to other papers for references.<sup>4</sup>

The anesthetic goal for awake cortical mapping is to maintain an awake and cooperative patient for performing the

**Table 2 – Commonly used anesthetic agents and dosages for awake craniotomy.**

Drugs	Dosages
Propofol <sup>19,27</sup>	Manual infusion: 50–150 mcg/kg/min TCI effect site (sedation): 2.4–4.8 mcg/ml TCI effect site (mapping): 0.6–1.2 mcg/ml
Remifentanyl <sup>19,27</sup>	Manual infusion: 0.03–0.05 mcg/kg/min TCI effect site (sedation): 2–2.8 ng/ml TCI effect site (mapping): 1.6–2 ng/ml
Fentanyl <sup>17</sup>	Bolus: 0.75 mcg/kg Infusion: 0.01 mcg/kg/min
Alfentanil <sup>17</sup>	Bolus: 0.075 mcg/kg Infusion: 0.0015 mcg/kg/min
Sulfentanil <sup>17</sup>	Bolus: 7.5 mcg/kg Infusion: 0.5 mcg/kg/min
Dexmedetomidine <sup>20,21</sup>	Bolus: 0–0.5 mcg/kg Infusion: 0.2–0.7 mcg/kg/min

Source: Author.

required tasks. The purpose of the mapping procedure is to reliably identify the cortical areas and subcortical pathways involved in the motor, sensory, language, and cognitive functions. Inaccurate mapping could create a false sense of security with incorrect resection margins. Observation of the patient's reaction to the trans-cortical stimulation is used to define the function of the testing area. Clonic movement signifies primary motor area stimulation, whereas tonic movement is more related to the premotor area. For the mapping of language and cognitive functions, a fully awake and compliant patient is crucial for performing naming tasks and basic mental gymnastics, such as thinking of items within a category. Induced-inhibition of speech, language and cognition should be distinguished from non-compliance, over-sedation and focal seizures.<sup>2</sup> During the mapping, the patient might feel uncomfortable and anxious due to experiencing involuntary movements or the inhibition of voluntary movements or language. The level of anesthetic depth should strike a balance between the patient's comfort and the accuracy of the mapping result.

The most commonly used agents and dosages for awake craniotomy are listed in Table 2. Propofol infusion with a supplementary opioid is the most commonly reported choice for awake craniotomy. Propofol-only anesthesia with spontaneously breathing patients has been described as safe.<sup>17</sup> The addition of an opioid is a common practice to improve the analgesic quality and reduce the hypnotic requirement. A comparison of different types of opioids, including fentanyl, alfentanil, or sulfentanil, found no significant difference in the operative condition, electrocorticography and stimulation testing.<sup>18</sup> In a comparison of continuous remifentanyl infusion or intermittent fentanyl, both narcotics yielded similar patient satisfaction, recall, and intraoperative complications, although fewer patients experienced reversible respiratory depression with the use of remifentanyl.<sup>19</sup> Therefore, all narcotics are regarded as equally good for use during awake craniotomy. Notably, the time of emergence from sedation for intraoperative testing with the use of remifentanyl-propofol is approximately 9 min.<sup>20</sup>

The  $\alpha_2$  agonist dexmedetomidine has gained popularity for use in awake craniotomy owing to its unique ano-analgesic

property, less dis-inhibition and minimal respiratory depressant effects. There is an increasing trend of using the combination of propofol and dexmedetomidine to minimize dis-inhibition and to ensure speedy awakening. Dexmedetomidine has also been demonstrated to have minimal effects on the electrocorticography and has been successfully used in awake craniotomy for epileptic surgery.<sup>21,22</sup> However, there have been reports of more intense efforts being required to rouse the patient from dexmedetomidine sedation (i.e., via a physical stimulus such as sternal rubbing and calling of the patient's name). However, once roused and engaged, the patient remains able to cooperate with the cognitive testing.<sup>23</sup> A direct comparison between dexmedetomidine and the propofol-remifentanyl combination, particularly for performing awake cortical mapping, has yet to be evaluated.

### Complications and the safe performance of awake craniotomy

Major intraoperative complications include seizures, respiratory depression, air embolisms, cerebral swelling and the trigeminocardiac reflex. The common complications, preventive measures and management techniques are listed in Table 3. The overall complication rate is reported to be approximately 16.5%,<sup>5</sup> with 6.4% patients failing to complete the mapping procedure.<sup>12</sup> The main causes of failure are the onset of seizures and the loss of the patient's cooperation due to severe somnolence, restlessness or the development of mixed dysphasia. Failed awake craniotomies are associated with a lower incidence of gross-total resections, increased postoperative speech deterioration and a longer length of stay.<sup>12</sup>

Because intraoperative complications are not uncommon, certain preventive measures and monitoring are mandatory for the safe performance of awake craniotomy. In addition to all routine monitoring, monitoring of breathing both clinically and via end-tidal CO<sub>2</sub> are mandatory for all patients. Optimizing the positioning and access are essential for easily controlling the airway, dealing with emergencies and communicating with patients during the mapping procedure. Intubation equipment, such as laryngeal mask, endotracheal tube, laryngoscopy, and medications should be prepared for emergency use. Fiber-optic bronchoscopy should also be easily accessible in the operation theater complex. Additionally, intraoperative seizure is a known complication during awake craniotomy. The majority of intraoperative seizures are mostly focal seizures related to cortical stimulation, and these seizures usually resolve spontaneously after the cessation of stimulation. However, ice-cold saline applied by the surgeon to the brain surface and small doses of anti-convulsants (e.g. 1 mg/kg of propofol) may required in some cases.<sup>4</sup>

### Protocols of outpatient awake craniotomy

Ambulatory awake craniotomy has been performed and studied extensively in Toronto since the early 1990s. The initial successful same-day discharge rate was reported to be 89.1%,<sup>24</sup> and the data of the subsequent two cohort studies from the same center were maintained as high as 92.4 and 94%, respectively.<sup>25,26</sup> Their protocol emphasizes rigorous patient selection, minimally invasive surgical and anesthetic



**Table 3 – Intraoperative complications of awake craniotomy**<sup>16,28,29</sup>

Complication	Incidence	Prevention	Management
Respiratory depression	2–18%	Preoperative evaluation Tight titration of anesthetics Prophylactic use of NIV AAA technique	Lower the level of anesthetics Optimize head positioning Insertion of LMA or intubation, if necessary
Loss of patients' cooperation	4.2%	Careful patient selection Psychological support Tight titration of sedatives and analgesics Optimize the patient positioning	Optimize the level of anesthetics General anesthesia, if necessary
Seizure	2.1–11.6%	Ensure adequate levels of anticonvulsants	To stop seizures: 2. Cold saline irrigation of the brain 3. Propofol (10–30 mg boluses) – multiple boluses may be required 4. Midazolam (1–2 mg boluses) – may interfere with ECoG General supportive measures: 1. Airway protection - may need to secure the airway, especially with prolonged seizures 2. Protect the patient from injury 3. A long-acting medication (phenytoin) may be required
Nausea and vomiting	4%	Preoperative evaluation Psychological support Prophylactic anti-emetics Use of propofol Optimize local anesthesia	Anti-emetic administration
Hypertension	Not available	Adequate local anesthesia Optimal analgesia	Optimize local anesthesia and analgesia Rule out ICH
Air embolism	0.3–0.64%	Avoid the head-up position, if possible	Reduce air entrapment by Trendelenberg positioning and neck compression Saline flushing of the surgical field Aspiration of air, if a central venous line is available Inotropic and general support

Source: Adapted by the author from Olsen,<sup>16</sup> Lobo et al.<sup>28</sup> y Balki et al.<sup>29</sup>

Abbreviation: NIV: non-invasive ventilation; AAA: asleep-awake-asleep techniques; LMA: laryngeal mask; ECoG: electrocorticography; ICH: intra-cranial hemorrhage.

techniques and stringent discharge procedures. All patients are monitored for at least 6 h after surgery with a routine pre-discharge CT scan and are assessed individually by a surgeon and anesthesiologist for the suitability of discharge. The patients are also followed up by home-care nurses and educated about the warning signs associated with serious complications such as ICH.

## Conclusions

The application of awake craniotomy has been continually evolving. Attention to every component, including careful patient selection, preoperative psychological preparation, solid rapport building, ensuring patient comfort in positioning, superb regional anesthesia, the proper choice of anesthetic techniques and agents, preparation and prompt crisis management, and continuous team communication, are the keys to successful awake craniotomy. Tight anesthetic control and the meticulous performance of mapping procedures are essential to achieve the highest accuracy of cerebral localization results. Finally, because complications are common during awake craniotomy, prompt crisis management,

team communication and experienced anesthetic and surgical teams are important to maximize the utility and safety of this procedure.<sup>27–40</sup>

## Ethical disclosures

**Protection of human and animal subjects.** The authors declare that no experiments were performed on humans or animals for this study.

**Confidentiality of data.** The authors declare that no patient data appear in this article.

**Right to privacy and informed consent.** The authors declare that no patient data appear in this article.

## Funding

None.

## Conflicts of interest

The author has no conflicts of interest to declare.

## REFERENCES

- Bulsara KR, Johnson J, Villavicencio AT. Improvements in brain tumor surgery: the modern history of awake craniotomies. *Neurosurg Focus*. 2005;18:e5.
- Szelényi A, Bello L, Duffau H, Fava E, Feigl GC, Galanda M, et al. Intraoperative electrical stimulation in awake craniotomy: methodological aspects of current practice. *Neurosurg Focus*. 2010;28:E7.
- Nguyen HS, Sundaram SV, Mosier KM, Cohen-Gadol AA. A method to map the visual cortex during an awake craniotomy. *J Neurosurg*. 2011;114:922-6.
- Chui J, Manninen P, Valiante T, Venkatraghavan L. The anesthetic considerations of intraoperative electrocorticography during epilepsy surgery. *Anesth Analg*. 2013;117:479-86.
- Larkin M. Neurosurgeons wake up to awake-brain surgery. *Lancet*. 1999;353:1772.
- Taylor MD, Bernstein M. Awake craniotomy with brain mapping as the routine surgical approach to treating patients with supratentorial intraaxial tumors: a prospective trial of 200 cases. *J Neurosurg*. 1999;90:35-41.
- Serletis D, Bernstein M. Prospective study of awake craniotomy used routinely and nonselectively for supratentorial tumors. *J Neurosurg*. 2007;107:1-6.
- Brown T, Shah AH, Bregy A, Shah NH, Thambuswamy M, Barbarite E, et al. Awake craniotomy for brain tumor resection: the rule rather than the exception? *J Neurosurg Anesthesiol*. 2013;25:240-7.
- Sacko O, Lauwers-Cances V, Brauge D, Sesay M, Brenner A, Roux FE. Awake craniotomy vs surgery under general anesthesia for resection of supratentorial lesions. *Neurosurgery*. 2011;68:1192-8, discussion 1198-9.
- Gupta DK, Chandra PS, Ojha BK, Sharma BS, Mahapatra AK, Mehta VS. Awake craniotomy versus surgery under general anesthesia for resection of intrinsic lesions of eloquent cortex – a prospective randomised study. *Clin Neurol Neurosurg*. 2007;109:335-43.
- Erickson KM, Cole DJ. Anesthetic considerations for awake craniotomy for epilepsy and functional neurosurgery. *Anesthesiol Clin*. 2012;30:241-68.
- Nossek E, Matot I, Shahar T, Barzilai O, Rapoport Y, Gonen T, et al. Failed awake craniotomy: a retrospective analysis in 424 patients undergoing craniotomy for brain tumor. *J Neurosurg*. 2013;118:243-9.
- Santini B, Talacchi A, Casagrande F, Casartelli M, Savazzi S, Procaccio F, et al. Eligibility criteria and psychological profiles in patient candidates for awake craniotomy: a pilot study. *J Neurosurg Anesthesiol*. 2012;24:209-16.
- Klimek M, Verbrugge SJ, Roubos S, van der Most E, Vincent AJ, Klein J. Awake craniotomy for glioblastoma in a 9-year-old child. *Anaesthesia*. 2004;59:607-9.
- Sarang A, Dinsmore J. Anaesthesia for awake craniotomy – evolution of a technique that facilitates awake neurological testing. *Br J Anaesth*. 2003;90:161-5.
- Olsen KS. The asleep-awake technique using propofol-remifentanyl anaesthesia for awake craniotomy for cerebral tumours. *Eur J Anaesthesiol*. 2008;25:662-9.
- Skucas AP, Artru AA. Anesthetic complications of awake craniotomies for epilepsy surgery. *Anesth Analg*. 2006;102:882-7.
- Gignac E, Manninen PH, Gelb AW. Comparison of fentanyl, sufentanil and alfentanil during awake craniotomy for epilepsy. *Can J Anaesth*. 1993;40 5 Pt 1:421-4.
- Manninen PH, Balki M, Lukitto K, Bernstein M. Patient satisfaction with awake craniotomy for tumor surgery: a comparison of remifentanyl and fentanyl in conjunction with propofol. *Anesth Analg*. 2006;102:237-42.
- Keifer JC, Dentchev D, Little K, Warner DS, Friedman AH, Borel CO. A retrospective analysis of a remifentanyl/propofol general anesthetic for craniotomy before awake functional brain mapping. *Anesth Analg*. 2005;101:502-8.
- Bekker AY, Kaufman B, Samir H, Doyle W. The use of dexmedetomidine infusion for awake craniotomy. *Anesth Analg*. 2001;92:1251-3.
- Souter MJ, Rozet I, Ojemann JG, Souter KJ, Holmes MD, Lee L, et al. Dexmedetomidine sedation during awake craniotomy for seizure resection: effects on electrocorticography. *J Neurosurg Anesthesiol*. 2007;19:38-44.
- Bustillo MA, Lazar RM, Finck AD, Fitzsimmons B, Berman MF, Pile-Spellman J, et al. Dexmedetomidine may impair cognitive testing during endovascular embolization of cerebral arteriovenous malformations: a retrospective case report series. *J Neurosurg Anesthesiol*. 2002;14:209-12.
- Bernstein M. Outpatient craniotomy for brain tumor: a pilot feasibility study in 46 patients. *Can J Neurol Sci*. 2001;28:120-4.
- Blanshard HJ, Chung F, Manninen PH, Taylor MD, Bernstein M. Awake craniotomy for removal of intracranial tumor: considerations for early discharge. *Anesth Analg*. 2001;92:89-94.
- Boulton M, Bernstein M. Outpatient brain tumor surgery: innovation in surgical neurooncology. *J Neurosurg*. 2008;108:649-54.
- Carrabba G, Venkatraghavan L, Bernstein M. Day surgery awake craniotomy for removing brain tumours: technical note describing a simple protocol. *Minim Invasive Neurosurg*. 2008;51:208-10.
- Lobo F, Beiras A. Propofol and remifentanyl effect-site concentrations estimated by pharmacokinetic simulation and bispectral index monitoring during craniotomy with intraoperative awakening for brain tumor resection. *J Neurosurg Anesthesiol*. 2007;19:183-9.
- Balki M, Manninen PH, McGuire GP, El-Beheiry H, Bernstein M. Venous air embolism during awake craniotomy in a supine patient. *Can J Anaesth*. 2003;50:835-8.
- Bonhomme V, Franssen C, Hans P. Awake craniotomy. *Eur J Anaesthesiol*. 2009;26:906-12.
- Costello TG. Awake craniotomy and multilingualism: language testing during anaesthesia for awake craniotomy in a bilingual patient. *J Clin Neurosci*. 2014;12:123-4.
- Milian M, Tatagiba M, Feigl GC. Patient response to awake craniotomy – a summary overview. *Acta Neurochir (Wien)*. 2014;156:1063-70.
- Shinoura N, Midorikawa A, Yamada R, Hana T, Saito A, Hiromitsu K, et al. Awake craniotomy for brain lesions within and near the primary motor area: a retrospective analysis of factors associated with worsened paresis in 102 consecutive patients. *Surg Neurol Int*. 2013;4:149.
- Bilotta F, Stazi E, Titi L, Lalli D, Delfini R, Santoro A, et al. Diagnostic work up for language testing in patients undergoing awake craniotomy for brain lesions in language areas. *Br J Neurosurg*. 2013.
- Garavaglia MM, Das S, Cusimano MD, Crescini C, Mazer CD, Hare GM, et al. Anesthetic approach to high-risk patients and prolonged awake craniotomy using dexmedetomidine and scalp block. *J Neurosurg Anesthesiol*. 2013.
- Bilotta F, Titi L, Lanni F, Stazi E, Rosa G. Training anesthesiology residents in providing anesthesia for awake

- craniotomy: learning curves and estimate of needed case load. *J Clin Anesth.* 2013;25:359-66.
37. Hansen E, Seemann M, Zech N, Doenitz C, Luerding R, Brawanski A. Awake craniotomies without any sedation: the awake-awake-awake technique. *Acta Neurochir (Wien).* 2013;155:1417-24.
  38. Ouyang MW, McDonagh DL, Phillips-Bute B, James ML, Friedman AH, Gan TJ. Comparison of postoperative nausea between benign and malignant brain tumor patients undergoing awake craniotomy: a retrospective analysis. *Curr Med Res Opin.* 2013;29:1039-44.
  39. Ouyang MW, McDonagh DL, Phillips-Bute B, James ML, Friedman AH, Gan TJ. Does midline shift predict postoperative nausea in brain tumor patients undergoing awake craniotomy? A retrospective analysis. *Curr Med Res Opin.* 2013;29:1033-8.
  40. Nossek E, Matot I, Shahar T, Barzilai O, Rapoport Y, Gonen T, et al. Intraoperative seizures during awake craniotomy: incidence and consequences: analysis of 477 patients. *Neurosurgery.* 2013;73:135-40, discussion 140.