



Revista Colombiana de Anestesiología

Colombian Journal of Anesthesiology

www.revcolanest.com.co



Review

Ultrasound and nerve stimulation-guided axillary block[☆]



Luz María Lopera-Velásquez^{a,*}, Carlos Restrepo-Garcés^{b,c}

^a Department of Anaesthesia and Perioperative Medicine, University of Western Ontario, London, Ontario, Canada

^b Pain Relief Clinic, Surgery and Imaging Department, Hospital Pablo Tobón Uribe, Medellín, Colombia

^c Pain Relief Unit & Anaesthesia Department, Clínica Las Américas, Medellín, Colombia

ARTICLE INFO

Article history:

Received 17 July 2014

Accepted 26 October 2015

Available online 18 December 2015

Keywords:

Ultrasonography

Ultrasonics

Anesthesia, Conduction

Nerve block, Analgesia

ABSTRACT

Introduction: The axillary block of the brachial plexus is widely used as an anaesthesia and analgesia technique in upper limb surgery, specifically for hand, wrist and forearm procedures. The use of nerve stimulation and ultrasound guidance has increased the rate of success with this block.

Objective: This article presents a non-systematic review of the most recent literature on axillary block of the brachial plexus using ultrasound and peripheral nerve stimulation.

Materials and methods: A search for a non-systematic review was conducted in the Cochrane, Pubmed/Medline, Embase and OVID databases.

Conclusion: The axillary block of the brachial plexus is an anaesthetic and analgesic technique for upper limb surgery that has a high percentage of success, with a low degree of difficulty for the procedure.

© 2015 Sociedad Colombiana de Anestesiología y Reanimación. Published by Elsevier España, S.L.U. All rights reserved.

Bloqueo axilar guiado por ultrasonido y neuroestimulador

RESUMEN

Introducción: El bloqueo axilar del plexo braquial es un bloqueo anestésico ampliamente utilizado como técnica anestésica y analgésica en cirugía de miembro superior, específicamente para mano, muñeca y antebrazo. El uso de neuroestimulador y ultrasonido ha aumentado la tasa de éxito de éste bloqueo.

Objetivo: El presente artículo hace una revisión no sistemática de la literatura más reciente relacionada con el bloqueo axilar del plexo braquial utilizando ultrasonido y estimulación de nervio periférico.

Palabras clave:

Ultrasonografía

Ultrasonido

Anestesia de conducción

Bloqueo nervioso

Analgesia

[☆] Please cite this article as: Lopera-Velásquez LM, Restrepo-Garcés C. Bloqueo axilar guiado por ultrasonido y neuroestimulador. Rev Colomb Anesthesiol. 2016;44:30-35.

* Corresponding author at: Department of Anaesthesia and Perioperative Medicine, University of Western Ontario, 339 Windermere Road, London, Ontario, Canada.

E-mail address: lulopera@hotmail.com (L.M. Lopera-Velásquez).

2256-2087/© 2015 Sociedad Colombiana de Anestesiología y Reanimación. Published by Elsevier España, S.L.U. All rights reserved.

Métodos y Materiales: Se hizo una búsqueda en las bases de datos de Cochrane, Pubmed/Medline, Embase y OVID para la realización de una revisión no sistemática.

Conclusión: El bloqueo del plexo braquial a nivel axilar es una técnica anestésica y analgésica para cirugía de miembro superior con alto porcentaje de éxito y bajo grado de dificultad en cuanto a realización del procedimiento.

© 2015 Sociedad Colombiana de Anestesiología y Reanimación. Publicado por Elsevier España, S.L.U. Todos los derechos reservados.

Introduction

The axillary block is a regional anaesthesia technique, involving blockade of the brachial plexus at the axillary level. It is widely used as an anaesthetic and analgesic technique in upper limb surgery, specifically for hand, wrist and forearm procedures. In the axillary block, the terminal branches of the brachial plexus are blocked. The use of nerve stimulation and ultrasound has increased the rate of success with this block¹ and has reduced the incidence of complications. Unlike the inter-scalene and supra and infraclavicular blocks, the risk of injury to the stellate ganglion, pneumothorax or phrenic nerve palsy is practically non-existent with this block because of the site where the puncture is performed.^{2,3}

Methods

A search was conducted in the Cochrane, Medline/Pubmed, OVID and EMBASE databases using the words axillary block, ultrasound, nerve stimulator, regional anaesthesia. Included in the search were meta-analyses, systematic reviews, clinical trials and non-systematic reviews, and articles in English, Spanish and French.

Results

History

The first percutaneous axillary block was described by Hirschel in 1911.⁴ In 1958, Burnham described how the axillary neurovascular bundle was enveloped by a fascia that could be "filled" with local anaesthetic.⁵ In 1961, De Jong referred to the axillary space as a pyramid of 42 ml in volume, and described that the nerves and blood vessels were surrounded individually by septae.⁶ In 1979, Eriksson and Skarby used a tourniquet distal to the axillary injection site and, in 1984, Thompson and Rorie identified the brachial plexus septae in the axillary space as preventing the homogenous spread of the anaesthetic.⁷ More recently, cadaver studies using nuclear magnetic resonance have concluded that the terminal branches are lined by connective tissue and fascial sheaths that prevent the anaesthetic from flowing homogeneously after a single injection and covering the entire plexus.^{8,9} The nerve stimulator was introduced in the 1990s, and ultrasound has been introduced in recent years¹⁰; their use has increased the rate of success with the axillary block. The use of nerve stimulation and ultrasound has also reduced the number of complications because

of the smaller volume of local anaesthetic required to achieve blockade,¹¹⁻¹³ although there are reports in which the use of ultrasound does not reduce the occurrence of complications when compared to the nerve stimulator.¹⁴ Complications associated with the axillary block include toxicity from the local anaesthetics¹⁵ and neurological and vascular injury,^{16,17} although there is a paucity of reports in the literature on these occurrences, supporting the theory that this block provides a high safety margin. Obesity increases the risk of vascular puncture and failure rates with this type of block.¹⁸

Anatomy

The brachial plexus arises from the ventral branches of C5 to C8. At the level of the scalene muscles, these branches regroup to form the superior, middle and inferior trunks, and when they leave the inter-scalene space, they form anterior and posterior divisions at the supraclavicular level. The divisions regroup again at an infraclavicular level to form the three lateral, posterior and medial cords which finally give rise to the five terminal branches at the axillary level: radial, axillary, musculocutaneous, median and ulnar nerves (Fig. 1).¹⁹

The radial nerve arises from the posterior cord. It runs together with the radial artery along its posterior aspect and breaks away from the neurovascular bundle at the axillary level in order to continue along the spiral humeral groove. It provides sensation to the posterior and lateral aspects of the arm and forearm down to the wrist, the lateral aspect of the dorsum down to the hand, the dorsal surface of the first three digits and half of the fourth digit. It provides motor innervation

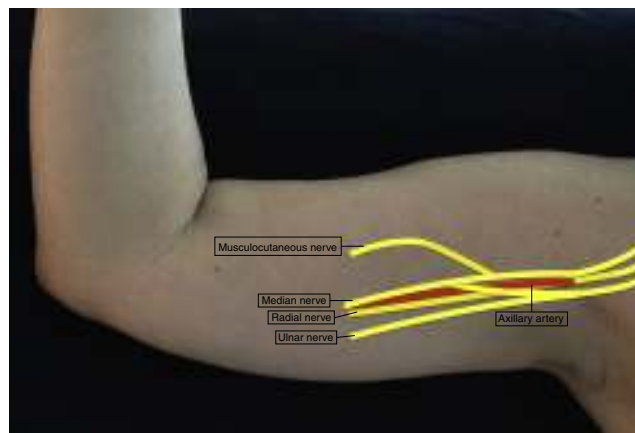


Fig. 1 – Illustration of the terminal branches of the brachial plexus at the axillary level.

Source: Authors.

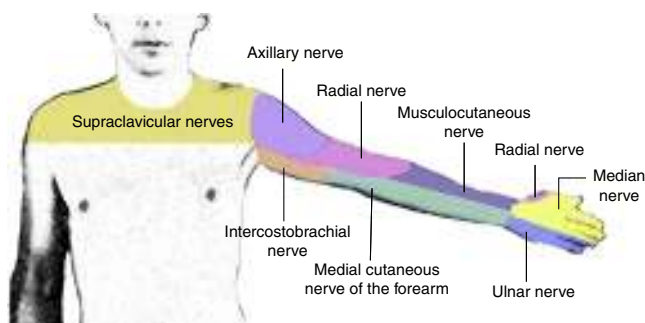


Fig. 2 – Dermatomes of the anterior aspect of the upper limb.

Source: Authors.

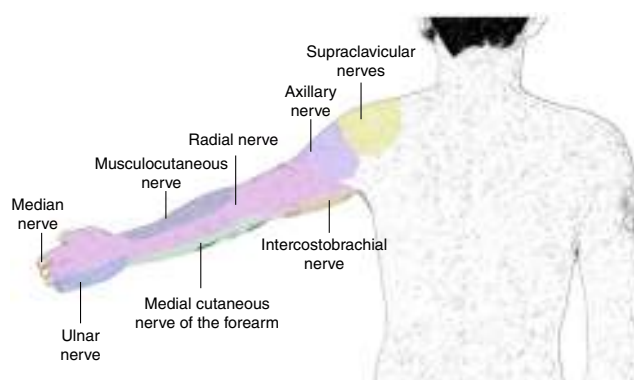


Fig. 3 – Dermatomes of the posterior aspect of the upper limb.

Source: Authors.

to the triceps and brachioradialis muscles and to the extensors of the posterior compartment of the forearm.

The axillary nerve arises from the posterior cord at the level of the coracoid process, forming an angle towards the deltoid muscle, which it innervates (Fig. 2).

The median nerve traverses most of the time superior to the axillary artery, while the ulnar and axillary nerves are found inferior to the axillary artery. The median nerve does not have cutaneous or motor branches in the arm, but in the forearm it provides motor innervation to the anterior compartment, except for the flexor carpi ulnaris and half of the flexor digitorum profundus. In the hand, it innervates the thenar eminence and the first two lumbrical muscles. It provides sensation to the lateral half of the hand and the dorsum of the first three digits, and half of the fourth finger down to the nail bed.

The ulnar nerve arises from the medial cord and it does not provide branches to the arm. It provides motor innervation to the flexor carpi ulnaris and the medial half of the flexor digitorum profundus. In the hand, it innervates all the small muscles except for the thenar eminence and the first two lumbricals. It provides sensitive innervation to the middle third of the palm, the dorsum of the fifth finger, and the medial aspect of the fourth finger.

The musculocutaneous nerve arises from the lateral cord, perforates the coracobrachialis muscle and leaves the neurovascular sheath usually at the level of the lateral edge of the pectoralis major. It may be found outside the coracobrachialis muscle and joining the median nerve in 1 out of 5 individuals.²⁰ It provides motor innervation to the coracobrachialis, biceps and brachialis muscles. At the elbow, it becomes a purely sensory nerve, innervating the anterior portion of the forearm down to the wrist (Fig. 3).

Technique

The axillary block is used in hand, wrist and forearm surgery. It is not as effective as other brachial plexus blocks in elbow surgery.²¹

The axillary block may be performed using a nerve stimulator, ultrasound or a combination of the two. With the use of the nerve stimulator, the failure rate is 5–30%, while the two techniques combined increase the success rate by up to 97%.²² As for the time required for performing the block, no

significant difference has been found with the two techniques; ultrasound has allowed the use of a smaller local anaesthetic volume, although this affects the duration of the effect. One of the advantages of ultrasound is the ability to visualize the nerves – making blockade easier in patients with anatomic variants²³ – and the spread of the local anaesthetic as it is injected.²⁴ Complications associated with the axillary block appear to be less when ultrasound is used.²⁵

The patient is positioned in supine decubitus, with the arm in 90° of abduction and the forearm in flexion (Fig. 4). Asepsis must be performed up to the distal portion of the arm. A high frequency linear probe is placed on the transverse axis, over the axillary fold. The neurovascular bundle is localized 1–2 cm underneath the skin.

The axillary artery must be localized first. It provides a spherical, pulsatile hypoechoic image and it is not readily compressible. It is found over the conjoined tendon, formed by the junction of the latissimus dorsi and teres major tendons. It is important to identify the axillary vein, because it also provides a spherical and hypoechoic image, although it is not pulsating and is readily compressible. The median, ulnar and radial nerves are arranged around the artery. They appear as spherical or oval-shaped, hyperechogenic, hypoechogenic or beehive-like structures. Their position around the artery

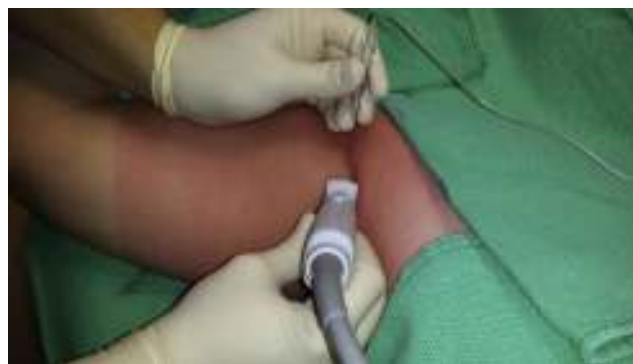

Fig. 4 – Axillary block of the brachial plexus at the level of the axilla using a linear transducer and a nerve stimulation needle.

Source: Authors.

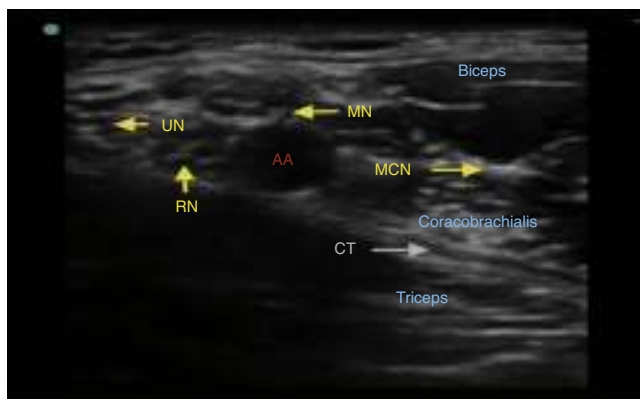


Fig. 5 – Ultrasound image of the brachial plexus at the axillary level. UN = ulnar nerve, RN = radial nerve, MN = median nerve, MCN = musculocutaneous nerve, AA = axillary artery, CT = conjoined tendon. Source: Authors.

is not constant. The position of the radial and the median nerves in relation to the artery is usually constant.²⁶ The radial nerve is located between 4 and 6 o'clock in 83% of cases, the median nerve is found between 9 and 12 o'clock in 88% of cases, and the ulnar nerve is between 12 and 3 o'clock in 85% of cases.²⁷ The musculocutaneous nerve is usually separated laterally from the artery, between the short head of the biceps and the coracobrachialis muscle (Fig. 5).

Once the structures have been identified under ultrasound, the skin is infiltrated with local anaesthetic and then, using a 50 mm 22G nerve stimulator needle on an in-plane approach, the nerves are localized with the nerve stimulator (Table 1). There is no significant difference in terms of success using the echogenic or non-echogenic needle in this type of block.²⁸ It is recommended to use a 0.5–1.0 mA current in order to reduce the risk of dysfunction or nerve injury. Stimulation with a current of 0.3–0.5 mA increases the success of the block and shortens the onset time, but increases the risk of nerve injury.²⁹ When muscle stimulation is obtained with a 0.2 mA current or less, an intraneural injection must be suspected to be likely.³⁰ Once the corresponding muscle contraction is obtained, syringe aspiration is done in order to rule out intravascular injection, and then the local anaesthetic is injected, always under ultrasound guidance in order to visualize the deposition of the anaesthetic around the nerve.

Three ways of injecting the local anaesthetic at the axillary level have been described: a single injection, dual injection, and multiple injections to deliver the full volume of the anaesthetic. When a single injection is used, the anaesthetic is

delivered under the axillary artery. In the dual injection, part of the dose is delivered under the artery and the other part is delivered around the musculocutaneous nerve.³¹ The most effective technique with less associated complications but the most time consuming is the multiple injections.²² The time to onset of the axillary block varies depending on the injection technique. In the study conducted by Lopez-Morales et al. comparing the axillary block with the infraclavicular block, time to onset was significantly longer for the axillary block, at a mean of 10.2 min.³² Blockade rate for the axillary, intercostobrachial and medial cutaneous nerves of the arm is lower through the axillary approach.³³

The choice of the local anaesthetic depends on the duration of the block and the availability in the Anaesthesia service. Reducing the local anaesthetic concentration and increasing the volume prolongs the duration of the block.^{34,35} Levobupivacaine and ropivacaine have been used in concentrations of 0.375–0.75% and 0.25–0.5%, respectively. Compared to levobupivacaine, ropivacaine has a faster onset of action (9 min vs. 12 min) but blockade duration is shorter (9.2 h vs. 11.3 h).³⁶ The total volume used ranges between 30 and 40 ml when delivered in a single injection, and between 5 and 8 ml when each nerve is anaesthetized individually. González et al. found that the MAC-90 of 1.5% lidocaine with epinephrine 5 mcg/ml is 5.5 ml and 23.5 ml in the dual injection technique.³⁷ The minimum effective volume (MEV90) of 0.5% bupivacaine is 1.56 ml per nerve.³⁸ The use of other additives to prolong the block, like using dexamethasone with the local anaesthetic, has shown to be an effective way to increase motor and sensory blockade.^{39,40} The use of clonidine as adjunct to the local anaesthetic has not been shown to increase block duration,⁴¹ different from dexmedetomidine which does appear to prolong axillary block duration.^{42,43} Magnesium sulphate has also been used as additive in axillary blocks, but has not been shown to improve block duration or efficacy.⁴⁴ Other adjuncts such as ketamine and tramadol have also been used, and some studies have shown evidence that they prolong the action of the axillary block.⁴⁵ There is recent evidence about the effect of hyaluronidase in shortening the time to onset of the axillary block in upper limb surgery.⁴⁶

Continuous infusion of the local anaesthetic using catheters is not well documented in the literature.^{47,48} The axillary region is prone to catheter displacement and does not allow adequate fixation. The continuous infusion technique for the local anaesthetic has been used, but it is the surgeon who places the catheter under direct vision.⁴⁹

It is recommended to add the intercostobrachial nerve block to the axillary block in order to increase tolerance of the tourniquet during the surgical procedure.⁵⁰ This nerve is the cutaneous branch of the second intercostal nerve and provides sensory innervation to the upper portion of the medial and posterior aspects of the arm.

Table 1 – Motor responses with nerve stimulation of each nerve.

Radial nerve	Arm or wrist extension
Median nerve	Forearm pronation, thumb flexion
Ulnar nerve	Flexion of the fifth finger
Musculocutaneous nerve	Arm flexion
Source: Authors.	

Conclusion

The brachial plexus block at the axillary level is an anaesthetic and analgesic technique used with a high degree of success in upper limb surgery, creating little difficulty for the procedure. The use of nerve stimulation and ultrasound has increased

the rate of effectiveness of this block and reduced the rate of complications.

Funding

None.

Conflict of interest

The authors declare having no conflicts of interest.

REFERENCES

- Strub B, Sonderegger J, Von Campe A, Osterwalder JJ. What benefits does ultrasound-guided axillary block for brachial plexus anaesthesia offer over the conventional blind approach in hand surgery? *J Hand Surg Eur.* 2011;36:778–86.
- Satapathy A, Coventry DM. Axillary brachial plexus block. *Anesth Res Pr.* 2011;2011:1–5.
- Monkowski D, Gay Larese CS. Bloqueo axilar del plexo braquial. *Rev Arg Anest.* 2004;62:440–4.
- Selander D. Axillary plexus block: paresthetic or perivascular. *Anesthesiology.* 1987;66:726–8.
- Burnham PJ. Simple regional nerve block for surgery of the hand and forearm. *J Am Med Assoc.* 1959;169:941–3.
- De Jong RH. Axillary block of the brachial plexus. *Anesthesiology.* 1961;22:215–25.
- Thompson G, Rorie DK. Functional anatomy of the brachial plexus. *Anesthesiology.* 1983;59:117–22.
- Ay S, Akinci M, Sayin M, Bektas U, Tekdemir I, Elhan A. The axillary sheath and single-injection axillary block. *Clin Anat.* 2007;20:57–63.
- Kjelstrup T, Courivaud F, Klaastad Ø, Breivik H, Hol PK. High-resolution MRI demonstrates detailed anatomy of the axillary brachial plexus. A pilot study. *Acta Anaesthesiol Scand.* 2012;56:914–9.
- Luyet C, Constantinescu M, Waltenspul M, Luginbuhl M, Vogelín E. Transition from nerve stimulator to sonographically guided axillary brachial anesthesia in hand surgery. *J Ultrasound Med.* 2013;32:779–86.
- Chan VW, Perlas A, McCartney CJ, Brull R, Xu D, Abbas S. Ultrasound guidance improves success rate of axillary brachial plexus block. *Can J Anesth.* 2007;54:176–82.
- Bruce BG, Green A, Blaine TA, Wesner LV. Brachial plexus blocks for upper extremity orthopaedic surgery. *J Am Acad Orthop Surg.* 2012;20:38–47.
- Toju K, Hakozaiki T, Akatsu M, Isosu T, Murakawa M. Ultrasound-guided bilateral brachial plexus blockade with propofol-ketamine sedation. *J Anesth.* 2011;25:927–9.
- Maga JM, Cooper L, Gebhard RE. Outpatient regional anesthesia for upper extremity surgery update (2005 to present) distal to shoulder. *Int Anesth Clin.* 2012;50:47–55.
- Lecours M, Lévesque S, Dion N, Nadeau M-J, Dionne A, Turgeon AF. Complications of single-injection ultrasound-guided infraclavicular block: a cohort study. *Can J Anesth.* 2013;60:244–52.
- Gong D-J, Yuan H-J, Zhang Z-H. Axillary arteriovenous fistula after axillary plexus block. *J Anesth.* 2013;27:604–6.
- Sites BD, Taenzer AH, Herrick MD, Gilloon C, Antonakakis J, Richins J, et al. Incidence of local anesthetic systemic toxicity and postoperative neurologic symptoms associated with 12,668 ultrasound-guided nerve blocks. *Reg Anesth Pain Med.* 2012;37:478–82.
- Hanouz J-L, Grandin W, Lesage A, Oriot G, Bonnieux D, Gérard J-L. Multiple injection axillary brachial plexus block: influence of obesity on failure rate and incidence of acute complications. *Anesth Analg.* 2010;111:230–3.
- Mian A, Chaudhry I, Huang R, Rizk E, Tubbs RS, Loukas M. Brachial plexus anesthesia: a review of the relevant anatomy. Complications, and anatomical variations. *Clin Anat.* 2014;27:210–21.
- Remerand F, Laulan J, Couvret C, Palud M, Baud A, Velut S, et al. Is the musculocutaneous nerve really in the coracobrachialis muscle when performing an axillary block? An ultrasound study. *Anesth Analg.* 2010;110:1729–34.
- Wada T, Yamauchi M, Oki G, Sonoda T, Yamakage M, Yamashita T. Efficacy of axillary nerve block in elbow arthroscopic surgery: a randomized trial. *J Shoulder Elb Surg.* 2014;23:291–6.
- Chin K, Alakkad H, Cubillos J. Single, double or multiple-injection techniques for non-ultrasound guided axillary brachial plexus block in adults undergoing surgery of the lower arm. *Cochrane Database Syst Rev.* 2013;CD003842.
- Cuvillon P. Bloc axillaire, balance bénéfiques/risques: quel est le bénéfice de l'abord sous échographie? *Ann Fr Anesth Reanim.* 2012;31:e193–7.
- Veneziano GC, Rao VK, Orebaugh SL. Recognition of local anesthetic maldistribution in axillary brachial plexus block guided by ultrasound and nerve stimulation. *J Clin Anesth.* 2012;24:141–4.
- Da Conceição DB, Helayel PE, de Oliveira Filho GR. A comparative study between ultrasound and neurostimulation guided axillary brachial plexus block. *Rev Bras Anestesiologia.* 2009;59:585–91.
- Silva MG, Sala-Blanch X, Marin R, Espinoza X, Arauz A, Morros C. Bloqueo axilar ecoguiado: variaciones anatómicas de la disposición de los 4 nervios terminales del plexo braquial en relación con la arteria humeral. *Rev Esp Anestesiologia Reanim.* 2014;61:15–20.
- Ustuner E, Yilmaz A, Özgencil E, Okten F, Turhan SC. Ultrasound anatomy of the brachial plexus nerves in the neurovascular bundle at the axilla in patients undergoing upper-extremity block anesthesia. *Skelet Radiol.* 2013;42:707–13.
- Duger C, Isbir AC, Kaygusuz K, Kol IO, Gursoy S. The importance of needle echogenicity in ultrasound guided axillary brachial plexus block: a randomized controlled clinical study. *Int J Med Sci.* 2013;10:1108–12.
- Vassiliou T, Müller H-H, Ellert A, Wallot P, Kwee K-M, Beyerle M, et al. High- versus low-stimulation current threshold for axillary plexus blocks: a prospective randomized triple-blinded noninferiority trial in 205 patients. *Anesth Analg.* 2013;116:247–54.
- Nadeau M-J, Lévesque S, Dion N. Ultrasound-guided regional anesthesia for upper limb surgery. *Can J Anesth.* 2013;60:304–20.
- Cho S, Kim YJ, Kim J-H, Baik H-J. Double-injection perivascular ultrasound-guided axillary brachial plexus block according to needle positioning: 12 versus 6 o'clock position of the axillary artery. *Korean J Anesth.* 2014;66:112–9.
- Lopez-Morales S, Moreno-Martin A, Leal del Ojo J, Rodriguez-Huertas F. Bloqueo axilar ecoguiado frente a bloqueo infraclavicular ecoguiado para la cirugía de miembro superior. *Rev Esp Anestesiologia Reanim.* 2013;60:313–9.
- Sariguney D, Mahli A, Coskun D. The extent of blockade following axillary and infraclavicular approaches of brachial plexus block in uremic patients. *J Clin Med Res.* 2011;4:26–32.
- Ozcan E, Izdes S, Ozturk L, Kanbak O. Comparison of the efficacy of different concentrations and volumes of levobupivacaine in axillary brachial plexus blockade. *Minerva Anestesiologia.* 2014;80:330–6.

35. Schoenmakers KPW, Wegener JT, Stienstra R. Effect of local anesthetic volume (15 vs 40 mL) on the duration of ultrasound-guided single shot axillary brachial plexus block: a prospective randomized, observer-blinded trial. *Reg Anesth Pain Med.* 2012;37:242-7.
36. González-Suárez S, Pacheco M, Roigé J, Puig MM. Comparative study of ropivacaine 0.5% and levobupivacaine 0.33% in axillary brachial plexus block. *Reg Anesth Pain Med.* 2009;34:414-9.
37. González AP, Bernucci F, Pham K, Correa JA, Finlayson RJ, Tran DQH. Minimum effective volume of lidocaine for double-injection ultrasound-guided axillary block. *Reg Anesth Pain Med.* 2013;38:16-20.
38. Ferraro LHC, Takeda A, dos Reis Falcão LF, Rezende AH, Sadatsune EJ, Tardelli MA. Determination of the minimum effective volume of 0.5% bupivacaine for ultrasound-guided axillary brachial plexus block. *Rev Bras Anesthesiol.* 2014;64:49-53.
39. Yaghoobi S, Seddighi M, Yazdi Z, Ghafouri R, Khezri MB. Comparison of postoperative analgesic effect of dexamethasone and fentanyl added to lidocaine through axillary block in forearm fracture. *Pain Res Treat.* 2013;2013:1-6.
40. Koscielniak-Nielsen ZJ, Dahl JB. Ultrasound-guided peripheral nerve blockade of the upper extremity. *Curr Opin Anesth.* 2012;25:253-9.
41. Trifa M, Ben Khalifa S, Jendoubi A, Zribi N, Regaya T, Engelhardt T. Clonidine does not improve quality of ropivacaine axillary brachial plexus block in children. *Paediatr Anaesth.* 2012;22:425-9.
42. Kaygusuz K, Kol IO, Duger C, Gursoy S, Ozturk H, Kayacan U, et al. Effects of adding dexmedetomidine to levobupivacaine in axillary brachial plexus block. *Curr Ther Res Clin Exp.* 2012;73:103-11.
43. Zhang Y, Wang C, Shi J, Sun B, Liu S, Li P, et al. Perineural administration of dexmedetomidine in combination with ropivacaine prolongs axillary brachial plexus block. *Int J Clin Exp Med.* 2014;7:680-5.
44. Choi IG, Choi YS, Kim YH, Min JH, Chae YK, Lee YK, et al. The effects of postoperative brachial plexus block using MgSO₄ on the postoperative pain after upper extremity surgery. *Korean J Pain.* 2011;24:158-63.
45. Senel AC, Ukinc O, Timurkaynak A. Does the addition of tramadol and ketamine to ropivacaine prolong the axillary brachial plexus block? *Biomed Res Int.* 2014: 686287.
46. Koh WU, Min HG, Park HS, Karm MH, Lee KK, Yang HS, et al. Use of hyaluronidase as an adjuvant to ropivacaine to reduce axillary brachial plexus block onset time: a prospective, randomised controlled study. *Anaesthesia.* 2015;70: 282-9.
47. Al E, Pirbudak L, Tahtaci N, Kul S. Combined axillary block with "selective" injection of nerves and the axillary catheter: comparison of bupivacaine 0.25% or levobupivacaine 0.25%. *Middle East J Anesth.* 2012;21:705-12.
48. Yu B, Zhang X, Sun P, Xie S, Pang Q. Non-stimulation needle with external indwelling cannula for brachial plexus block and pain management in 62 patients undergoing upper-limb surgery. *Int J Med Sci.* 2012;9:766-71.
49. Abd-Elsayed AA, Seif J, Guirguis M, Zaky S, Mounir-Soliman L. Bilateral brachial plexus home going catheters after digital amputation for patient with upper extremity digital gangrene. *J Clin Med Res.* 2011;3:325-7.
50. Roussel J, Thirkannad S. Comparison of 3 ultrasound-guided brachial plexus block approaches for cubital tunnel release surgery in 120 ambulatory patients. *AANA J.* 2014;82: 121-6.