



IMAGES IN GASTROENTEROLOGY AND HEPATOLOGY

Meckel's Diverticulum: A Rare Cause of Overt Obscure Gastrointestinal Bleeding in an Adult Male



Divertículo de Meckel: Causa Rara de Hemorragia Digestiva Obscura Manifesta num Homem Adulto

Carlos Fernandes*, Rolando Pinho, João Carvalho

Gastroenterology Department, Centro Hospitalar de Vila Nova de Gaia/Espinho, Vila Nova de Gaia, Portugal

Received 21 November 2014; accepted 9 December 2014
Available online 23 March 2015

A 64-year-old male, with history of arterial hypertension and colonic polyps, recurred to the emergency department with recurrent hematochezia in the last 6 h. He denied abdominal pain, fever or other symptoms. No anemia or hemodynamic instability was present. Physical examination confirmed fresh blood and clots in the rectal ampulla. An urgent colonoscopy revealed fresh blood and clots in the terminal ileum and through the colon. Subsequently an urgent upper gastrointestinal endoscopy was performed with no relevant findings. Hence, in the same day, an urgent capsule enteroscopy was performed. In the middle ileum, a large diverticulum (Fig. 1) with erythematous mucosa in the fundus (Fig. 2) and a linear ulcer in the neck was found. Congestive mucosa and several deep ulcers with no active bleeding were apparent adjacent and downstream from the diverticulum (Fig. 3). These features highly suggested a Meckel's diverticulum with ectopic gastric mucosa. After a multidisciplinary discussion, a laparoscopic diverticulectomy was performed. Histological evaluation confirmed a Meckel's diverticulum with gastric and pancreatic tissues (Fig. 4). The patient was discharged 5 days later. No changes in the terminal ileum were apparent in a colonoscopy performed because of a post-polypectomy surveillance 4 months later.

Meckel's diverticulum is the most common congenital anomaly in the GI tract. It results from a persistent remnant of the omphalomesenteric duct and it is usually located in the antimesenteric side of the middle/distal ileum. It has

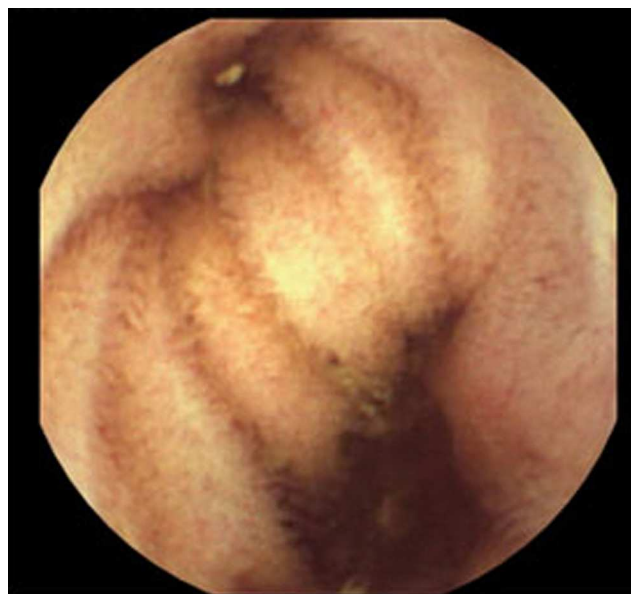

Figure 1 Double lumen image in the middle ileum suggesting a diverticulum.

* Corresponding author.

E-mail address: carlosdpfernandes@gmail.com (C. Fernandes).

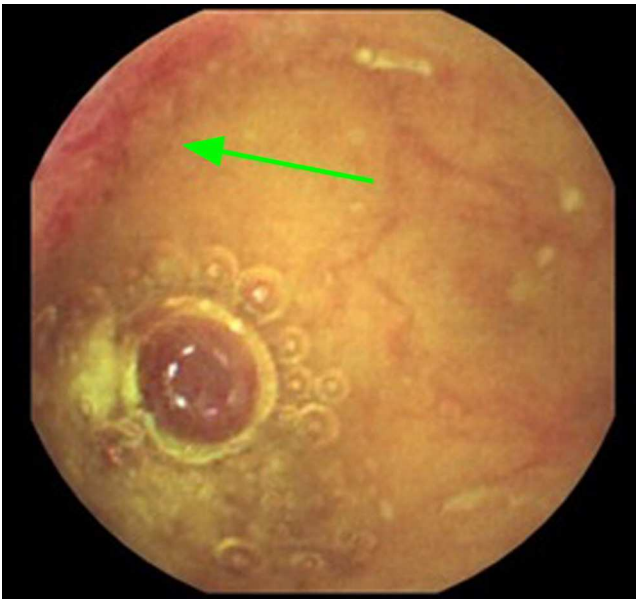


Figure 2 Erythematous mucosa in the fundus of the diverticulum.

an estimated prevalence of 2% in general population and it is twice more prevalent in males.¹ Histological evaluation reveals ectopic tissue in 10–20% of the cases, mostly gastric mucosa.² Nevertheless, the embryological origin of this later phenomenon is not well known. Meckel's diverticulum is often asymptomatic and only 2–4% will develop a related complication during the life course. Gastrointestinal bleeding is the most common manifestation in adults.³ Ectopic gastric tissue leads to acid secretion and consequently to mucosal ulceration downstream from the diverticulum. Hence, an obscure or overt GI bleeding may rarely occur. A nuclear medicine study using 99m technetium pertechnetate – *Meckel's scan* – has been used for diagnosis. Nevertheless it is only able to diagnose

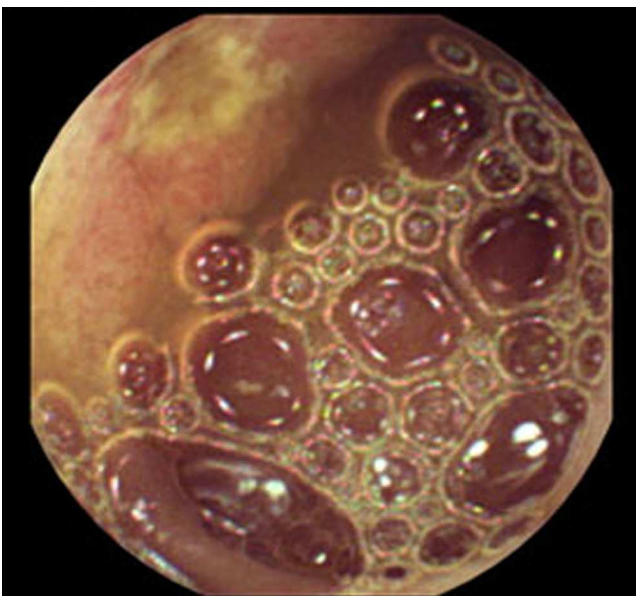

Figure 3 Congestive and ulcerated mucosa in the terminal ileum.

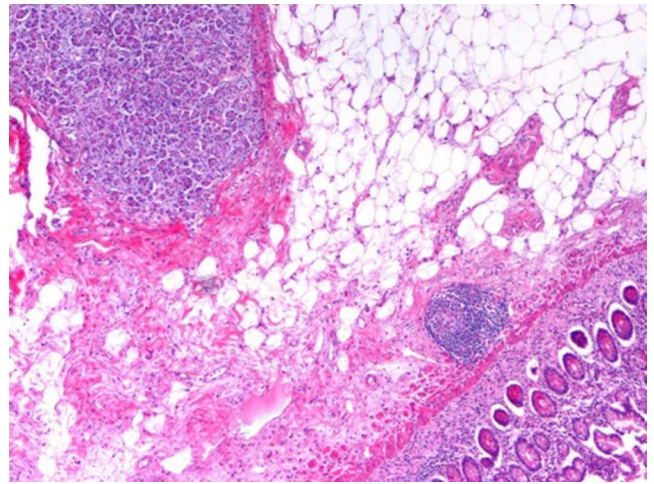


Figure 4 Histological evaluation revealing ectopic gastric and pancreatic tissues in the diverticulum (HE; 100 \times).

Meckel's diverticulum with ectopic gastric mucosa, which is only present in 20% of the cases. More recently, capsule enteroscopy and device-assisted enteroscopy have also been used for diagnosis.⁴ A surgical approach is recommended in symptomatic Meckel's diverticulum.⁵ A simple diverticulectomy or segmental bowel resection with a primary anastomosis are possible. The management of incidental and asymptomatic Meckel's diverticulum is still controversial.

Ethical responsibilities

Protection of human and animal subjects. The authors declare that no experiments were performed on humans or animals for this study.

Confidentiality of data. The authors declare that no patient data appear in this article.

Right to privacy and informed consent. The authors declare that no patient data appear in this article.

Conflict of interest

Nothing to declare.

References

1. Brown CK, Olshaker JS. Meckel's diverticulum. *Am J Emerg Med.* 1988;6:157–64.
2. Menezes M, Tareen F, Saeed A, Khan N, Puri P. Symptomatic Meckel's diverticulum in children: a 16-year review. *Pediatr Surg Int.* 2008;24:575–7.
3. Freeny PC, Walker JH. Inverted diverticula of the gastrointestinal tract. *Gastrointest Radiol.* 1979;4:57–9.
4. Zheng CF, Huang Y, Tang ZF, Chen L, Leung YK. Double-balloon enteroscopy for the diagnosis of Meckel's diverticulum in pediatric patients with obscure GI bleeding. *Gastrointest Endosc.* 2014;79:354–8.
5. Papparella A, Nino F, Noviello C, Marte A, Parmeggiani P, Martino A, et al. Laparoscopic approach to Meckel's diverticulum. *World J Gastroenterol.* 2014;20:8173–8.