



## ENDOSCOPIC SNAPSHOT

# Burkitt's Lymphoma Diagnosed by Colonoscopy in Immunocompetent Patient



## Linfoma de Burkitt Diagnosticado por Colonoscopia em Doente Imunocompetente

Rosa Coelho<sup>a,\*</sup>, Regina Gonçalves<sup>a</sup>, Jennifer Costa<sup>b</sup>, Guilherme Macedo<sup>a</sup>

<sup>a</sup> Gastroenterology Department, Centro Hospitalar de São João, Porto, Portugal

<sup>b</sup> Pathology Department, Centro Hospitalar de São João, Portugal

Received 4 January 2015; accepted 1 February 2015

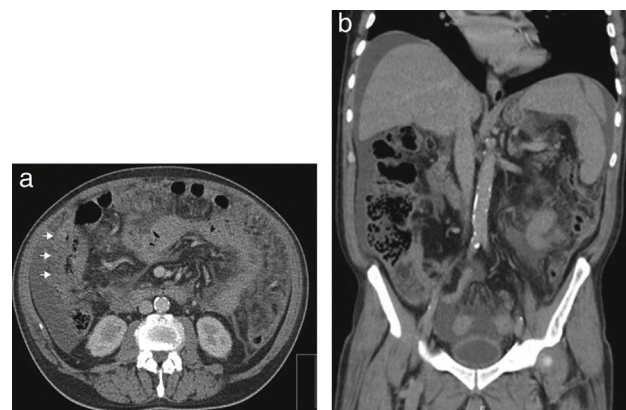
Available online 18 March 2015

### 1. Case report

A 67-year-old caucasian man without significant past medical history presented with colicky abdominal pain, in the right lower quadrant, for the last 3 weeks. He also referred a total weight loss of 10% during the last month. Complete blood count revealed hemoglobin of 9.0 g/dL with normal platelet and leukocyte count. Biochemical tests showed elevated C-reactive protein 148 (N: <3 mg/L) and erythrocyte sedimentation 78 (N <20 mm 1st hour). Serum lactate dehydrogenase levels were 1340 (N: 135–225 U/L). Abdominopelvic computed tomography (CT) showed hepatomegaly and splenomegaly and a small amount of ascitis consistent with peritoneal carcinomatosis (Fig. 1). CT also revealed parietal thickening of the intestinal wall in the hepatic flexure. Colonoscopy showed in the hepatic flexure one round shape lesion, with 20 mm of maximum diameter, predominately with normal mucosa and central ulceration (Fig. 2). Biopsies were performed and histologic examination revealed fragments of colorectal mucosa type, some with chorion occupied by some malignant cells of diffuse pattern consisting of intermediate to large cells. Immunohistochemical studies revealed positive lymphoid cells staining

for CD20 in the absence of expression of CD5 and cyclin D1. Malignant cells had expression of CD10 and Mib 1/Ki-67, with proliferative index of about 100% (Fig. 3). Epstein–Barr antibodies were IgG (VCA and EBNA) positive and IgM and IgG (early) negative.

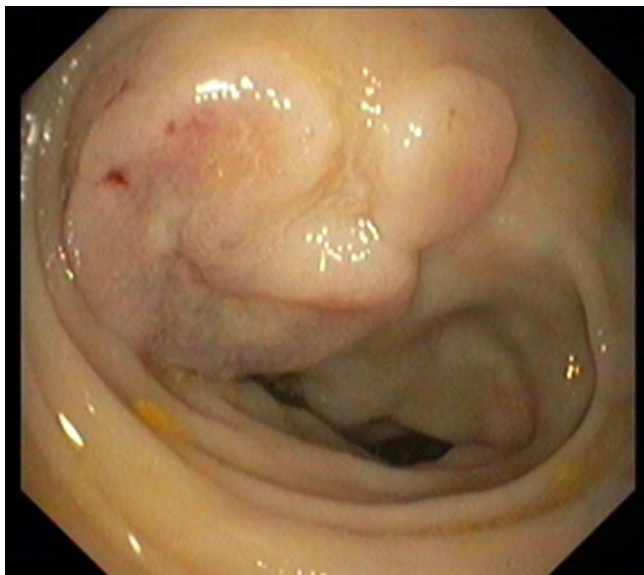
Bone marrow aspiration and biopsy were performed and flow cytometry revealed expression of surface immunoglobulin M, CD10, CD22, CD23, CD38 and CD79b. Fluorescence in situ hybridization was negative for (8:14) (q24; q32).



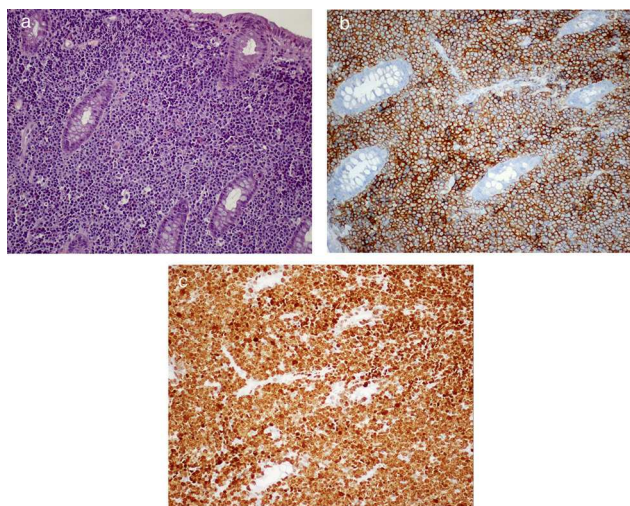
**Figure 1** Abdominal computed tomography showing parietal thickening of colonic flexure. (A) Axial view. (B) Coronal view.

\* Corresponding author.

E-mail address: [rosacoelhoabrantess@hotmail.com](mailto:rosacoelhoabrantess@hotmail.com) (R. Coelho).



**Figure 2** Colonoscopy showing in the hepatic flexure one round shape lesion, with 20 mm of maximum diameter, predominately with normal mucosa and with a central ulceration.



**Figure 3** Colonic mucosa infiltrated by Burkitt lymphoma. The cells are large with regular nuclei and conspicuous nucleolus (H&E, 200 $\times$ ) (a). In the immunohistochemical study the tumor cells stained for CD20 (100 $\times$ ) (b) and ki-67 (c).

However, the translocation MYC (8q24) was present in 53% of the malignant cells. The diagnosis of Burkitt lymphoma (BL) was performed and R-hiper-CVAD (cyclophosphamide, vincristine, doxorubicin and dexamethasone) chemotherapy regimen was started.

The authors describe a case of BL diagnosed by colonoscopy through a unique lesion in the hepatic flexure.<sup>1</sup> The colonic involvement by a sporadic form of BL is not a rare phenomenon. However, it is usually present in the terminal ileum or with massive abdominal involvement.<sup>2,3</sup>

In this case, the colonic involvement allowed a prompt diagnosis and the initiation of an appropriate therapy of this aggressive lymphoma. Taking into consideration the rapid growth of a BL, the diagnosis should be performed as soon as possible and made by the least invasive procedure.

### Conflicts of interest

The authors have no conflicts of interest to declare.

### References

1. Leoncini L, Raphael M, Stein H, Harris NL, Jaffe ES, Kluin PM. Burkitt lymphoma. In: Swerdlow SH, Campo E, Harris NL, et al., editors. WHO classification of tumours of haematopoietic and lymphoid tissues. 4th ed. Lyon: IARC Press; 2008. p. 262–4.
2. Blum KA, Lozanski G, Byrd JC. Adult Burkitt leukemia and lymphoma. *Blood*. 2004;104:3009.
3. Ferry JA. Burkitt's lymphoma: clinicopathologic features and differential diagnosis. *Oncologist*. 2006;11:375–83.