



IMAGES IN GASTROENTEROLOGY AND HEPATOLOGY

Upper Gastrointestinal Hemorrhage as an Unexpected Feature of Hepatocellular Carcinoma



Um Achado Inesperado em Doente com Carcinoma Hepatocelular com Hemorragia Digestiva Alta

Rosa Coelho^{a,*}, Branca Orfão^a, João Santos-Antunes^a, Eduardo Rodrigues-Pinto^a, Pedro Pereira^a, Helena Baldaia^b, Guilherme Macedo^a

^a Gastroenterology Department, Centro Hospitalar de São João, Porto, Portugal

^b Pathology Department, Centro Hospitalar de São João, Porto, Portugal

Received 17 February 2015; accepted 24 March 2015

Available online 5 May 2015

KEYWORDS

Carcinoma, Hepatocelular;
Gastrointestinal Hemorrhage

PALAVRAS-CHAVE

Carcinoma Hepatocelular;
Hemorragia Gastrointestinal

1. Case report

The authors describe a 63 year old male patient with a previous diagnosis of hereditary hemochromatosis (HH) performed an abdominal computed tomography (CT) that confirmed 2 liver masses compatible with hepatocellular carcinoma (HCC). He was proposed to chemoembolization treatment however he refused it. He presented in

Emergency Department, nine months after, with melenic stool and epigastric pain, the laboratory work-up revealed hemoglobin 6.5 g/dL with MCV of 72.3 fl. Esophagogastroduodenoscopy was performed and revealed in the anterior and superior bulb wall, protruding into the duodenal lumen, a dark reddish polypoid lesion with 30 mm of maximum diameter that occluded half of the lumen (Fig. 1).

Biopsies were taken as it was not actively bleeding at the time of endoscopy. Histological analysis showed a fibrin clot with hepatic phenotype cells in the peripheral area. These cells showed cytological atypia and were disaggregated (Fig. 2A). Immunohistochemical studies revealed positive tumor cells staining for Heppar-1 (Fig. 2B), HSP-70 (Fig. 2C) and glutamine synthetase (Fig. 2D). Immunostaining showed negative results for CDX-2 and glipican-3, confirming the diagnosis of locally advanced HCC. Abdominopelvic CT was performed and showed multiple liver masses located in the left hepatic lobe, with the confluent lesions measuring 19.9 cm of maximum diameter, some of them occupied the right lobe (Fig. 3A). It was also possible to recognize evidence of local invasion of the first part of the duodenum (Fig. 3B). Supportive treatment was given and the patient died of hepatic coma three weeks after the episode of gastrointestinal bleeding.

* Corresponding author.

E-mail address: rosacoelhoabrantres@hotmail.com (R. Coelho).

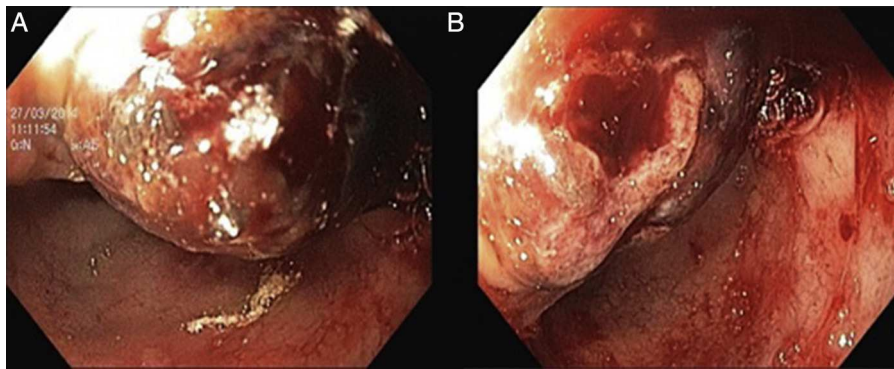


Figure 1 Endoscopy of the upper gastrointestinal tract showing a dark reddish polypoid lesion with 30 mm of maximum diameter that occluded half of the lumen of the duodenum.

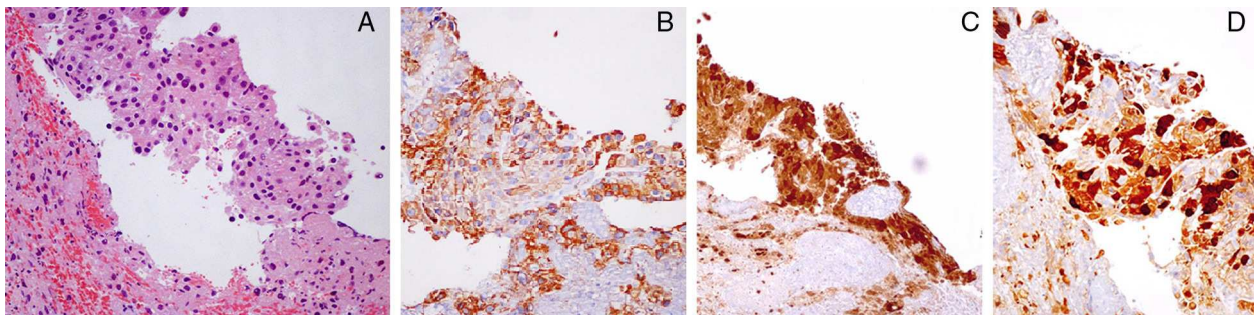


Figure 2 Histological analysis of the duodenal lesion revealed a fibrin clot with hepatic phenotype cells with cytological atypia, H&E 200 \times (A). Immunohistochemical studies revealed positive tumor cells staining for Heppar-1, 200 \times (B), HSP-70, 200 \times (C) and glutamine synthetase, 200 \times (D).

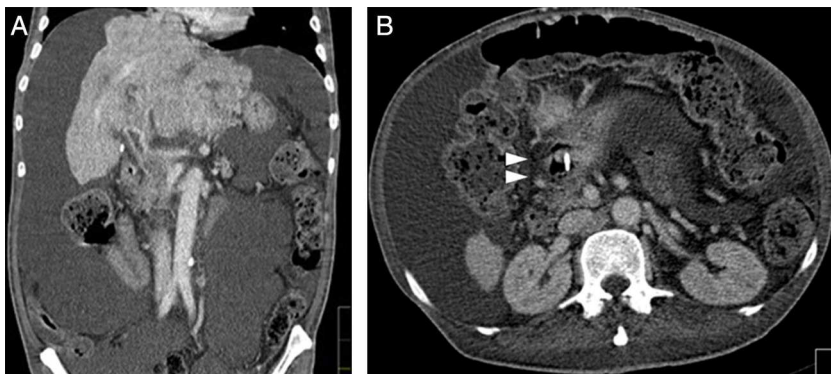


Figure 3 Abdominal computed tomography, coronal view, showing multiple liver masses located in the left hepatic lobe with 19.9 cm of maximum extension (Fig. 3A). The local invasion of the first part of the duodenum by the HCC is pointed out with an arrow in Fig. 3B (axial view).

2. Discussion

The authors describe a case of a duodenal invasion due to an HCC with upper digestive hemorrhage. In fact, the upper gastrointestinal bleeding is one of the most common complications in patients with HCC. Common etiologies include peptic ulcer disease, variceal bleeding due to portal hypertension from underlying cirrhosis, tumor invasion of portal vein causing thrombosis and portal hypertensive gastropathy.¹⁻⁴ The direct invasion of tumor to gut is considered a rare cause among patients with a non-variceal

source of upper digestive hemorrhage with an estimated incidence of 0.05–2%.⁵⁻⁷ The authors describe a 63-year-old male patient with a diagnosis of HCC who presented with melanic stool and epigastric pain. Esophagogastroduodenoscopy revealed in the anterior and superior bulb wall, a dark reddish polypoid lesion with 30 mm that occluded half of the lumen. Histological analysis confirmed the diagnosis of HCC with locally advanced disease.

Metastatic spread of HCC can be hematogenous, lymphatic or by direct invasion of the tumor into adjacent organs.⁴ In our case the abdominopelvic CT performed

showed local invasion of the first part of the duodenum (Fig. 3B and C) making the direct tumor invasion of the gastrointestinal tract the most likely process. In conclusion, despite being a rare situation, gastrointestinal bleeding in advanced HCC should raise suspicions of duodenal involvement.

Ethical disclosures

Protection of human and animal subjects. The authors declare that no experiments were performed on humans or animals for this study.

Confidentiality of data. The authors declare that no patient data appear in this article.

Right to privacy and informed consent. The authors declare that no patient data appear in this article.

Conflicts of interest

The authors have no conflicts of interest to declare.

References

1. Lin CP, Cheng JS, Lai KH, Lo GH, Hsu PI, Chan HH, et al. Gastrointestinal metastasis in hepatocellular carcinoma: radiological and endoscopic studies of 11 cases. *J Gastroenterol Hepatol.* 2000;15:536–41.
2. Humbert P, Sarmiento J, Boix J, Planas R, Quintero E, Franquet T, et al. Hepatocellular carcinoma presenting with bleeding due to duodenal perforation by the tumor. *Endoscopy.* 1987;19:37–8.
3. Liang JD, Chen CH, Hsu SJ, Sheu JC, Yang PM, Lee HS, et al. Hepatocellular carcinoma with duodenal invasion and metastasis. *J Gastroenterol Hepatol.* 2012;27: 677–83.
4. Sayana H, Yousef O, Clarkston WK. Massive upper gastrointestinal hemorrhage due to invasive hepatocellular carcinoma and hepato-gastric fistula. *World J Gastroenterol.* 2013;19: 7472–5.
5. Yeo W, Sung JY, Ward SC, Chung SC, Lee WY, Li AK, et al. A prospective study of upper gastrointestinal hemorrhage in patients with hepatocellular carcinoma. *Dis Sci.* 1995;40: 2516–21.
6. Maruyama A, Murabayashi K, Hayashi M, Nakano H, Isaji S, Uehara S, et al. Hepatocellular carcinoma complicated by gastrointestinal hemorrhage caused by direct tumor invasion of stomach. *J Hepatobiliary Pancreat Surg.* 1999;6:90–3.
7. Lynch P, Green L, Jordan PH, Graham DY. Hepatocellular carcinoma metastatic to the stomach presenting as bleeding multiple craterogenic ulcers. *Am J Gastroenterol.* 1989;84: 653–5.