



IMAGES IN GASTROENTEROLOGY AND HEPATOLOGY

Duodenal and Colonic Metastases of Ovarian Neoplasm



Metástases Duodenais e Cólicas de Neoplasia do Ovário

Sandra Barbeiro*, Catarina Atalaia Martins, Cláudia Gonçalves

Gastroenterology Department, Centro Hospitalar de Leiria, Leiria, Portugal

Received 28 February 2015; accepted 25 April 2015

Available online 2 July 2015

KEYWORDS

Colonic Neoplasms/secondary;
Duodenal Neoplasms/secondary;
Ovarian Neoplasms

PALAVRAS-CHAVE

Neoplasias do Cólon/secundária;
Neoplasias do Duodeno/secundária;
Neoplasias do Ovário

1. Case report

A 75-year-old female presented with asthenia and melena. Her past medical history included Alzheimer's disease, laparotomy in childhood due to unknown reason and an advanced ovarian neoplasm with peritoneal carcinomatosis in palliative treatment during the last year. Two years

before, the patient was submitted to gastrointestinal endoscopic examination (endoscopy and colonoscopy) that were normal. She was pale and her vital signs were stable. The abdomen was distended and asymmetric, with an abdominal surgical scar in midline and multiple visible and palpable masses in all quadrants (Fig. 1). Laboratory tests showed hemoglobin of 8.3 g/dL. Endoscopy demonstrated an excavated ulcer with elevated irregular borders, in the antero-inferior wall of duodenal first portion with no major bleeding stigmata (Fig. 2) and endoscopic biopsies were performed. Blood transfusion and medical treatment were started and clinical improvement was observed. However, on the third day after admission she had haematochezia. A colonoscopy was performed and showed two ulcerated masses in the sigmoid colon with active bleeding (Fig. 3). Endoscopic hemostasis with argon plasma coagulation was attempted without success. Biopsies were done. Histopathological examination confirmed metastatic malignant ovarian neoplasm in duodenum and colon (Fig. 4).

2. Discussion

Duodenal and colonic metastases are a very rare cause of gastrointestinal bleeding.^{1,2} However, they should be considered in a patient presenting with gastrointestinal bleeding and a previous history of malignancy.¹ The main

* Corresponding author.

E-mail address: sandrabarbeiro@gmail.com (S. Barbeiro).

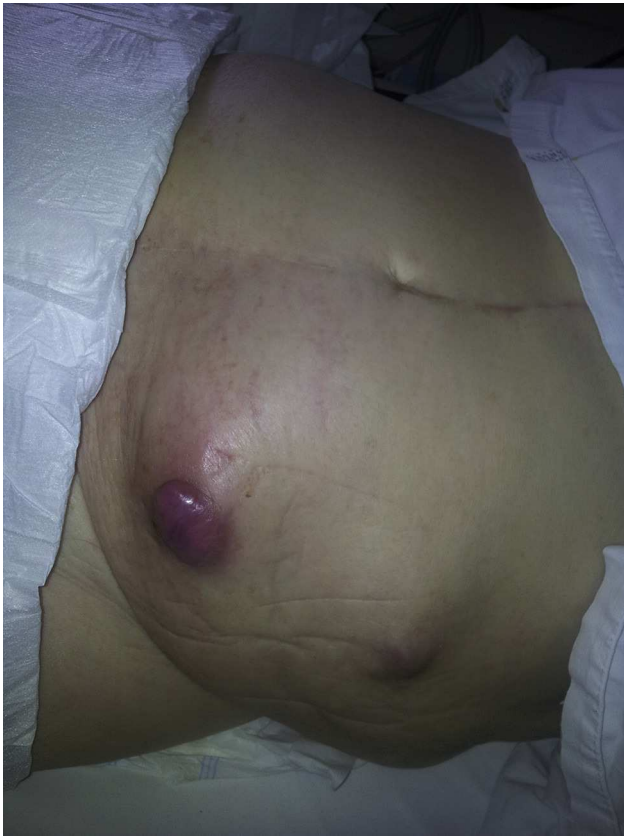

Figure 1 The abdominal examination revealed a distended and asymmetric abdomen with multiple visible and palpable masses, one of them in the left lower quadrant covered with purple skin.

dissemination pattern in epithelial ovarian neoplasm is the transcoelomic route. Metastasis to the intestinal mucosa can occur as a result of transmural involvement by invasion from the serosal surface. Lymphatic and hematogenous dissemination may also occur in the case of advanced peritoneal disease.¹ Symptoms are nonspecific and similar to those caused by other gastrointestinal tumors: abdominal pain, altered bowel habits, tenesmus, small bowel obstruction or perforation, hematemesis, melena and anemia. Imaging and endoscopic findings are unspecific and histopathological examination allowed definitive diagnosis. Special

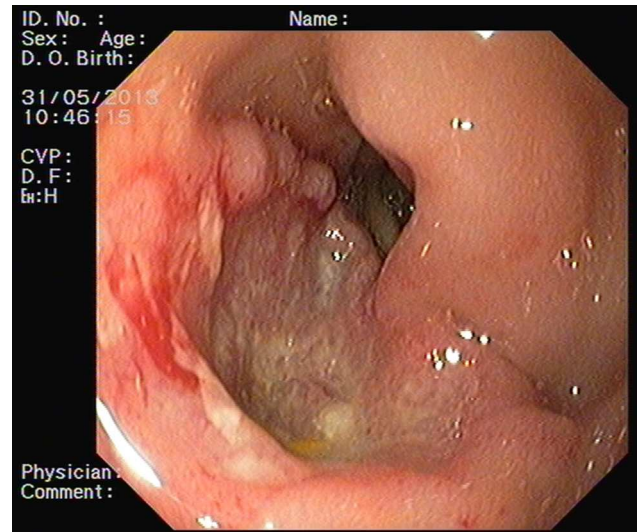


Figure 2 Excavated ulcer with elevated irregular borders, in the antero-inferior wall of duodenal first portion.

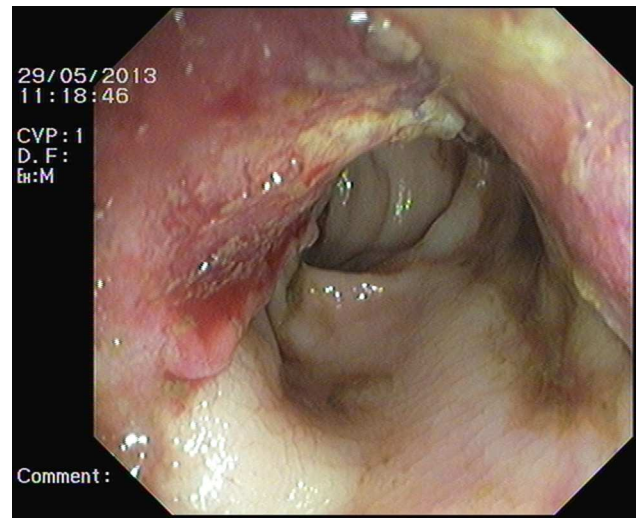


Figure 3 Ulcerated mass in the sigmoid colon.

immunohistochemical staining, including cyokeratin-7 and 20, Ber-EP4 and the anti-calretinin antibody, is important to confirm diagnosis.^{1,3-5} Prognosis is poor and treatment is mainly palliative. Endoscopic treatment is hardly effective.

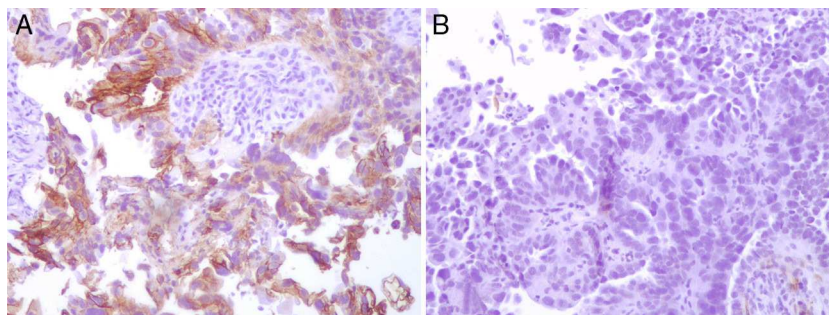


Figure 4 Immunohistochemistry staining was positive for Ber-EP4 (A) and negative for the anti-calretinin antibody (B).

In some cases surgical resection and chemotherapy may be considered.²

Ethical disclosures

Protection of human and animal subjects. The authors declare that no experiments were performed on humans or animals for this study.

Confidentiality of data. The authors declare that no patient data appear in this article.

Right to privacy and informed consent. The authors declare that no patient data appear in this article.

Conflicts of interest

The authors have no conflicts of interest to declare.

References

1. Loualidi A, Spooren PF, Grubben MJ, Blomjous CE, Goey SH. Duodenal metastasis: an uncommon cause of occult small intestinal bleeding. *Neth J Med.* 2004;60:201–5.
2. Zigelboim I, Broaddus R, Ramirez P. Atypical sigmoid metastasis from a high-grade mixed adenocarcinoma of the ovary. *Gynecol Oncol.* 2004;94:850–3.
3. Okamoto S, Ito K, Sasano H, Moriya T, Niikura H, Terada Y, et al. Ber-EP4 and anti-calretinin antibodies: a useful combination for differential diagnosis of various histological types of ovarian cancer cells and mesothelial cells. *Tohoku J Exp Med.* 2005;206:31–40.
4. Shin JH, Bae JH, Lee A, Jung CK, Yim HW, Park JS, et al. CK7, CK20, CDX2 and MUC2 immunohistochemical staining used to distinguish metastatic colorectal carcinoma involving ovary from primary ovarian mucinous adenocarcinoma. *Jpn J Clin Oncol.* 2010;40:208–13.
5. Tot T. Cytokeratins 20 and 7 as biomarkers: usefulness in discriminating primary from metastatic adenocarcinoma. *Eur J Cancer.* 2002;38:758–63.