



## IMAGES IN GASTROENTEROLOGY AND HEPATOLOGY

## Giant Pancreatic Cyst: An Unusual Entity

## Quisto Gigante do Pâncreas: Entidade Pouco Comum

Rita Vale Rodrigues<sup>a,\*</sup>, Sandra Faias<sup>a</sup>, Ricardo Fonseca<sup>b</sup><sup>a</sup> Gastroenterology Department, Instituto Português de Oncologia de Lisboa Francisco Gentil, Lisbon, Portugal<sup>b</sup> Pathology Department, Instituto Português de Oncologia de Lisboa Francisco Gentil, Lisbon, Portugal

Received 24 December 2015; accepted 9 February 2016

Available online 3 April 2016

## KEYWORDS

Endosonography;  
Pancreatic Cyst

## PALAVRAS-CHAVE

Ecoendoscopia;  
Quisto Pancreático

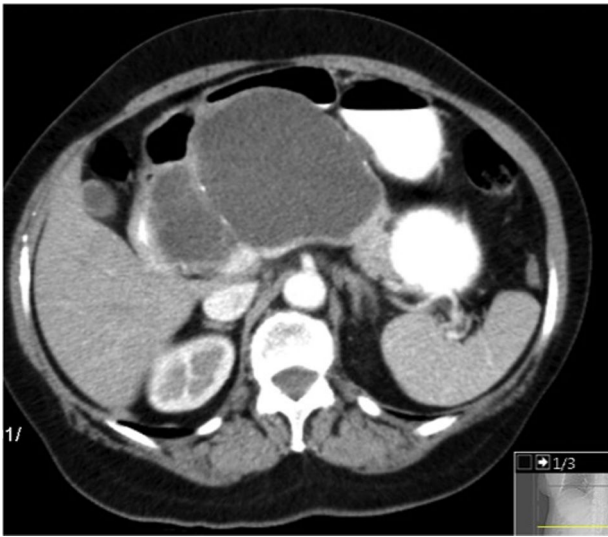
A 74-year-old woman was referred for further evaluation of a large pancreatic cystic lesion. She presented with abdominal discomfort, without weight loss, anorexia or history of pancreatitis or abdominal trauma. Physical examination revealed a large epigastric mass. A contrast-enhanced computed tomography (CT) showed a huge, well-defined, multiloculated cyst of 12 cm in greatest dimension arising from the pancreatic body, with multiple wall calcifications, without typical imaging features of a particular pancreatic cystic neoplasm (Fig. 1). Endoscopic

ultrasound (EUS) showed a multilocular cyst with a larger cyst (120 mm × 70 mm) and a peripheral microcystic component (Fig. 2). EUS-guided fine-needle aspiration of 7 mL of serous cystic fluid was performed from the largest cyst under prophylactic IV antibiotics. The sample had no malignant or mucus-producing cells and CEA (<2.5 ng/mL) and amylase (41 U/L) were within the reference values, making a serous cystadenoma the most likely diagnosis. Due to persistent epigastric discomfort, a distal pancreatectomy and splenectomy was performed (Fig. 3). Macroscopic examination of the resected specimen showed a combination of large cysts with several small cysts. On microscopy, the cysts were lined with a single layer of cuboidal epithelial cells with clear cytoplasm, PAS positive (Fig. 4). Histopathological examination confirmed the diagnosis of a pancreatic serous oligocystic adenoma.

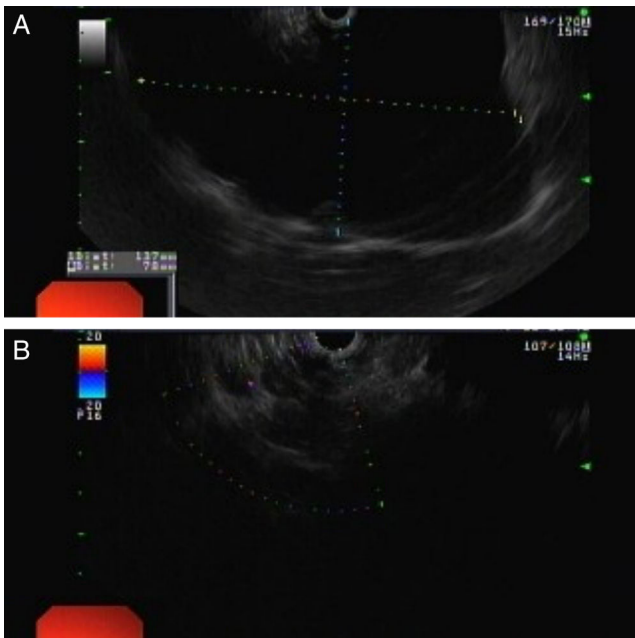
Serous oligocystic adenoma (SOA) is a rare benign pancreatic tumor which represent an atypical macroscopic morphologic variant of serous cystadenomas (SCA).<sup>1</sup> SOAs are characterized by a limited number of cysts with a diameter of >2 cm and share imaging features overlapping those of mucinous cystic neoplasm (MCN) and branch-duct intraductal papillary mucinous neoplasm (BD-IPMN), thus frequently making the radiologic diagnosis difficult.<sup>2</sup> Endoscopic ultrasound and cyst fluid aspiration have a role in distinguishing mucinous and serous lesions.<sup>3</sup> Management is determined by the presence of symptoms. Giant serous cystadenomas are also rare; this term usually refers to a multicystic tumor

\* Corresponding author.

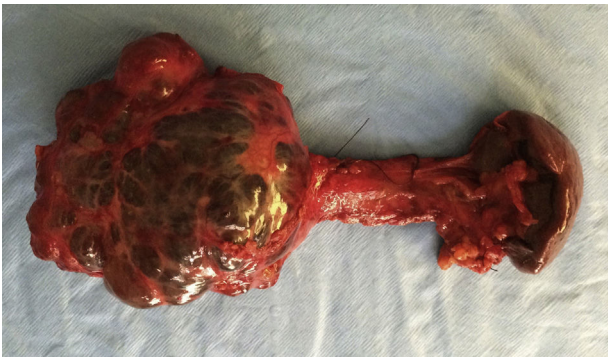E-mail address: [rita.vale.rodrigues@gmail.com](mailto:rita.vale.rodrigues@gmail.com) (R.V. Rodrigues).



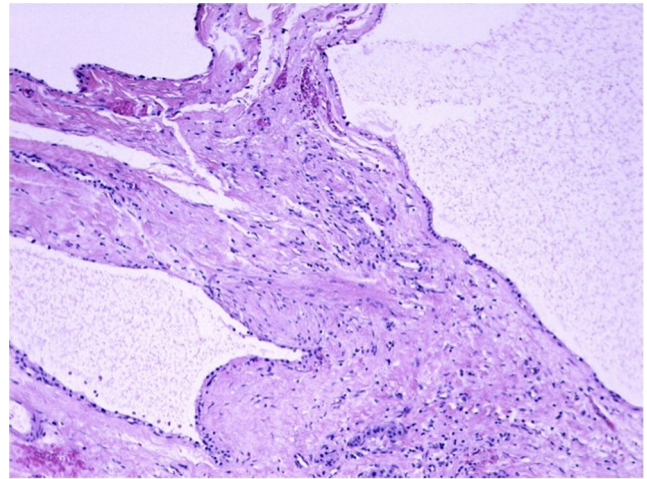
**Figure 1** Computed tomography: giant well-defined multiloculated cystic mass in the body of the pancreas.



**Figure 2** Endoscopic ultrasound: large multilocular cyst (A) with a microcystic pattern component (B).



**Figure 3** Macroscopic appearance of the resected pancreatic cyst.



**Figure 4** Microscopic appearance of the pancreatic cyst wall with a single layer of cuboidal epithelial cells with clear cytoplasm (H&E 100 $\times$ ).

larger than 10 cm in diameter in comparison with a described mean tumor diameter of 5 cm.<sup>4</sup>

### Ethical disclosures

**Protection of human and animal subjects.** The authors declare that no experiments were performed on humans or animals for this study.

**Confidentiality of data.** The authors declare that they have followed the protocols of their work center on the publication of patient data.

**Right to privacy and informed consent.** The authors declare that no patient data appear in this article.

### Conflicts of interest

The authors have no conflicts of interest to declare.

### References

1. Capella C, Solcia E, Kloppel G, Hruban RH. Serous cystic neoplasms of the pancreas. In: Hamilton SR, Aaltonen LA, editors. *World Health Organization classification of tumours: pathology and genetics of tumours of the digestive system*. Lyon: IARC Press; 2000. p. 231–3.
2. Lee JH, Kim JK, Kim TH, Park MS, Yu JS, Choi JY, et al. MRI features of serous oligocystic adenoma of the pancreas: differentiation from mucinous cystic neoplasm of the pancreas. *Br J Radiol*. 2012;85:571–6.
3. O'Toole D, Palazzo L, Hammel P, Ben Yaghlene L, Couvelard A, Felce-Dachez M, et al. Macrocystic pancreatic cystadenoma: the role of EUS and cyst fluid analysis in distinguishing mucinous and serous lesions. *Gastrointest Endosc*. 2004;59:823–9.
4. Galanis C, Zamani A, Cameron JL, Campbell KA, Lillemoen KD, Caparrelli D, et al. Resected serous cystic neoplasms of the pancreas: a review of 158 patients with recommendations for treatment. *J Gastrointest Surg*. 2007;11:820–6.