

Image in medicine

## Diagnosis of patients with suspected COVID-19: What is the role of chest CT? ☆



### Diagnóstico de pacientes con sospecha de COVID-19: ¿Cuál es el rol de la TC de tórax?

Diego Páez-Granda<sup>a,\*</sup>, Miriam Chicaiza Maldonado<sup>a</sup>, Gabriela Saritama Calle<sup>b</sup>,  
Carmen Ávalos García<sup>b</sup>, Henry Cabezas Tapia<sup>a</sup>, Jimena Andrade Herrera<sup>a</sup>

<sup>a</sup> Servicio de Radiodiagnóstico del Hospital de Especialidades de las Fuerzas Armadas, HE-1, Quito, Ecuador

<sup>b</sup> Sección de Radiología Torácica Hospital de Especialidades de las Fuerzas Armadas, HE-1, Quito, Ecuador

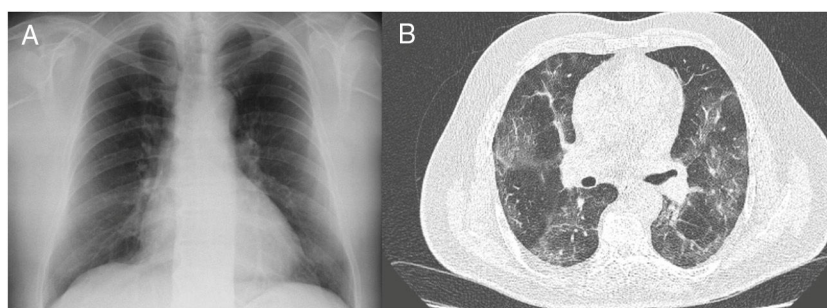


Figure 1.

A 46-year-old male patient with no history of interest presented with a two-day history of rising temperature, accompanied by a moderate “dry” cough. It was decided to perform a chest X-ray, which was reported as normal (Fig. 1A). Three days later, and with the persistence of fever and increased frequency of cough, he was seen again. In this admission, he reported the presence of dyspnoea, initially with moderate exertion, which later progressed to dyspnoea at rest. On physical examination, the patient was tachypnoeic, with an oxygen saturation of 93%. For this reason, it was decided to perform a chest CT, in which patchy, ground-glass infiltrates were observed, affecting both lungs (Fig. 1B). Given these findings, it was decided to perform a COVID-19 PCR, which was positive.

In the context of diagnosing patients with suspected COVID-19, chest X-ray has initially shown low sensitivity, reporting normal results. In early periods of the disease, CT has shown to identify pathological findings in suspected patients, making it an essential tool, especially in cases of unstable patients, with high COVID-19 suspicion, and with a normal plain chest X-ray. Obtaining the diagnosis by COVID-19 PCR takes approximately 24 h, as opposed to the 10 min used to perform a chest CT. This fact allows us to assess the relevance of this imaging technique in the diagnosis of certain patients with COVID-19.

☆ Please cite this article as: Páez-Granda D, Chicaiza Maldonado M, Saritama Calle G, Ávalos García C, Cabezas Tapia H, Andrade Herrera J. Diagnóstico de pacientes con sospecha de COVID-19: ¿Cuál es el rol de la TC de tórax? Med Clin (Barc). 2020;155:93.

\* Corresponding author.

E-mail address: [drdiegopaez@hotmail.com](mailto:drdiegopaez@hotmail.com) (D. Páez-Granda).