



CIRUGÍA y CIRUJANOS

Órgano de difusión científica de la Academia Mexicana de Cirugía
Fundada en 1933

www.amc.org.mx www.elsevier.es/circir



ORIGINAL ARTICLE

Interosseous electrostimulation in a model of lengthening with external fixation[☆]



Víctor Peña-Martínez^{a,*}, Jorge Lara-Arias^a, Félix Vilchez-Cavazos^a,
Eduardo Álvarez-Lozano^a, Roberto Montes de Oca-Luna^b, Óscar Mendoza-Lemus^a

^a Servicio de Ortopedia y Traumatología, Hospital Universitario Dr. José E. González, Universidad Autónoma de Nuevo León, Monterrey, Nuevo León, Mexico

^b Departamento de Histología, Facultad de Medicina, Universidad Autónoma de Nuevo León, Monterrey, Nuevo León, Mexico

Received 13 April 2016; accepted 3 July 2016

Available online 6 March 2017

KEYWORDS

Interosseous
electro-stimulation;
Bone elongation;
External fixation

Abstract

Background: A fracture repair involves complex cellular processes. However, despite optimal treatment, some fractures heal slowly or do not repair. These complications support the need for innovative therapies. Electromagnetic stimulation is a non-invasive technology that could have a direct impact on many cellular pathways.

Objective: To demonstrate the effectiveness of electro-stimulation by alternating current applied during bone elongation to accelerate the consolidation process for 30 days in an animal model.

Materials and methods: A device with closed circuit and graduated voltage was designed and kept in contact with the external fixator. Group A was elongated without electro-stimulation and group B was electro-stimulated since the beginning of the distraction. Radiographs were taken at 15 and 30 days post-surgical. Haematoxylin and eosin staining and Masson's trichrome stain were performed.

Results: No significant difference were observed in bone density of group A (4.05 ± 3.24 , $p = 0.163$). In group B there was a significant difference (61.06 ± 20.17 , $p = 0.03$) in bone density. Group A maintained a fibrous tissue repair, with areas of cartilage and bone matrix. Group B had more organised tissue in the stages of bone repair.

[☆] Please cite this article as: Peña-Martínez V, Lara-Arias J, Vilchez-Cavazos F, Álvarez-Lozano E, Montes de Oca-Luna R, Mendoza-Lemus O. Electroestimulación interósea en un modelo de elongación con fijación externa. Cir Cir. 2017;85:127–134.

* Corresponding author at: Servicio de Ortopedia y Traumatología, Hospital Universitario Dr. José E. González, Av. Madero y Gonzalitos s/n, C.P. 64460 Monterrey, Nuevo León, Mexico. Tel.: +52 81 8347 6698; fax: +52 81 8347 6698.

E-mail address: doctorviko@hotmail.com (V. Peña-Martínez).

PALABRAS CLAVE

Electroestimulación
interósea;
Elongación ósea;
Fijación externa

Conclusion: Because there is a significant difference in the growth and callus formation at 15 and 30 days between groups, electro-stimulation could be considered as an adjuvant during bone elongation.

© 2016 Academia Mexicana de Cirugía A.C. Published by Masson Doyma México S.A. This is an open access article under the CC BY-NC-ND license (<http://creativecommons.org/licenses/by-nc-nd/4.0/>).

Electroestimulación interósea en un modelo de elongación con fijación externa**Resumen**

Antecedentes: La reparación de una fractura implica procesos celulares complejos. Sin embargo, a pesar de un tratamiento óptimo, algunas fracturas curan lentamente o, simplemente, no se reparan. Estas complicaciones apoyan la necesidad de terapias innovadoras. La estimulación electromagnética es una tecnología no invasiva que pudiera tener un impacto directo sobre muchas vías celulares.

Objetivo: Demostrar la eficacia de la electroestimulación por corriente alterna, aplicada durante una elongación ósea para acelerar el proceso de consolidación, por 30 días en un modelo animal.

Materiales y métodos: Se diseñó un dispositivo de circuito cerrado y voltaje graduado, que se mantuvo en contacto con el fijador externo. El grupo A fue elongado sin electroestimulación y el grupo B fue electroestimulado desde el inicio de la distracción. Se tomaron radiografías a los 15 y 30 días posquirúrgicos, se realizaron tinciones de hematoxilina y eosina, y de tricrómico de Masson.

Resultados: No se observó una diferencia significativa en la densidad ósea del grupo A (4.05 ± 3.24 , $p = 0.163$). En el grupo B existe una diferencia significativa (61.06 ± 20.17 , $p = 0.03$), en la densidad ósea. El grupo A mantuvo un tejido de reparación fibroso, con zonas de cartílago y matriz ósea. El grupo B presentó un tejido más organizado en las fases de reparación ósea.

Conclusión: Debido a que existe una diferencia significativa en el crecimiento y formación del callo óseo a los 15 y 30 días entre ambos grupos, la electroestimulación podría considerarse como un adyuvante durante el proceso de elongación ósea.

© 2016 Academia Mexicana de Cirugía A.C. Publicado por Masson Doyma México S.A. Este es un artículo Open Access bajo la licencia CC BY-NC-ND (<http://creativecommons.org/licenses/by-nc-nd/4.0/>).

Background

A bone fracture is defined as the loss of normal continuity of bony tissues, resulting from a trauma or a pathological process which weakens its normal structure. In general, the primary cause is the result of applying force on the bone which surpasses its elastic resistance.^{1,2} A fracture repair involves complex processes of proliferation, cellular differentiation and several other factors such as growth, inflammatory cytokines, antioxidants, osteoclasts, osteoblasts, hormones, amino acids and several nutrients.³

It is difficult to establish a precise moment when a fracture should be rectified. Despite optimum treatment, however, several fractures repair slowly or simply do not repair.⁴ The majority of experts agree unless there is no clinical or radiological evidence of cure after at least 3 months the term "non union" should not be used to describe the fracture.⁵ Occasionally non unions occur with no apparent cause, but in many cases factors such as soft tissue damage, tissues associated with high energy open and closed fractures, infection, segmentary fractures, pathological fractures, fractures with soft tissue interposition, poor

local blood supply, systemic diseases, malnutrition, vitamin D deficiency, use of corticosteroids and a poor mechanical fixation, and iatrogenic interferences are involved.⁶

To understand the processes leading to bone lengthening, the terms osteodistraction osteogenesis should be analysed, as these refer to the production of new bone between vascular bony surfaces, generated by an osteotomy and separated by a gradual distraction⁷ and distraction epiphysiolysis, which refers to the mechanical compression and distraction forces in the growth platelet without an osteotomy but with the presence of an extra-articular fracture.^{8,9}

Ilizarov¹⁰ introduced the concept of callostasis, and was highly successful in achieving bone lengthening. His concepts were subsequently extended in accordance with Peña Martínez et al.¹¹

The Ilizarov method enables the surgeon to undertake complex and prolonged lengthening of both short extremities, either congenital or acquired, but the technique may be difficult and time is required to master this procedure, compared with methods which involve the use of a monolateral fixator.^{12,13} The De Bastiani et al.¹⁴ method has gained prestige among paediatric orthopaedists because

it is technically less demanding for the surgeon and the monolateral fixator tends to be more comfortable for the patient than a circumferential fixator. The method is based on a more conventional osteotomy, consisting of the opening of the periosteum, perforation of both cortices and in several directions, the interconnection of visible perforations with an osteotomy and the finalisation of the osteotomy with manual osteoclasts.¹⁴

With regard to the stimuli based on electric discharges or electro-stimulation, as stated by Boyer,¹⁵ background information on the treatment of non unions made by Birch in 1812 exists. After this Yasuda (1953) conducted studies which showed that there is an electric effect in the bone when it is submitted to lineal or angular charges, and a small current is applied to the bone, which is able to stimulate osteogenesis.¹⁶ Given that these electrical endogenous fields may change cellular activities in the bone, several systems for the therapeutic use of electro-stimulation were developed.^{17,18} Electro-stimulation equipment may be inductive in effect (like an electromagnetic pulsatile therapy), of training effect and direct current, currently accepted by the FDA for the treatment of non unions and vertebral fusions.^{19,20} However, efficacy in the use of callotaxis tissue has not been demonstrated, and our work therefore aims at demonstrating the efficacy of electro-stimulation for reducing bone lengthening time, corresponding with remodelling and corticalisation.

Materials and methods

Once previous authorisation from the Ethics Committee of the Faculty of Medicine and the Universidad Autónoma de Nuevo León had been obtained, 14 dogs of mixed breed were used and with weight and age averaging 10 kg and 3 years, respectively. 2 study groups were designed: Group A comprised 7 dogs treated with bone elongation without electro-stimulation and Group B comprised 7 dogs treated for bone elongation with electro-stimulation.

Electro-stimulator. A bone electro-stimulator was designed which was connected to an external fixator through a cathode receptor and an anode receptor. Kischner type 0.62 mm nails were designed for the drive with a polypropylene cover with a 5 mm drive area at both ends, to prevent an interface with soft tissues. The alternating current was 6 V to 20 μ A, with positive feed of dual 9 V source.

Surgical technique. The MiniRail System de Orthofix[®] was used for external fixation which consists of a fixator with 2 articulated bodies for fixing the screws and a central body with attachment for elongation of 0–8 cm. The De Bastiani screw insertion technique involved dissection of the flat bones up to the periosteum of the femoral diaphyseal bone. After this, a series of holes were made with the 2 mm drill bit throughout the whole diameter of the bone. These holes were joined together with a flat osteotome 0.5–1 cm wide until the coricotomy was completed.²¹ The periosteum was finally closed, as were the adjacent tissues and the skin with 3-0 (ETHICON[®] Johnson & Johnson S.A.) nylon sutures.

X-rays. The animals were sedated with xylazine so that x-rays in anteroposterior and lateral positions could be taken 15 and 30 days after surgery.

Euthanasia. This was performed in accordance with Official Mexican Regulation NOM-062-ZOO-1999, on technical specifications for the production, care and use of laboratory animals, with the administration of sodium pentobarbital at a dose of 120 mg/kg intravenously and xylazine at a dose of 2 mg/kg.

Histological staining. The samples were fixed with the Bouin solution and were decalcified with the Calci-Clear Rapid (Fisher Scientific, United Kingdom) solution. The tissue was then dehydrated and soaked in paraffin, to obtain the histological slices. Masson's trichrome stain and haematoxylin and eosin staining were used to observe cellular morphology, the amorphous matrix and the collagenous content.

Densitometry analysis. For analysis of radiographic images, the Image Pro Plus version 6 (Media Cybernetics, Inc. U.S.A.) software was used, to measure the amount of matter present in a material, measuring the amount of light passing through it.

Statistics. Statistical analysis was performed using the Student's *t*-test for both groups, comparing the bone density at 15 and 30 days, with the version 20 IBM SPSS (SPSS, Inc., Armon, NY, U.S.A.) software.

Results

For Group A (Fig. 1), in the cases where there had been no electrical stimulus, the slices stained with haematoxylin and eosin were analysed: in general we observed that the repair tissue had fibrous features. At other cut-off levels a transition from cartilaginous tissue to thick fibrous tissue was observed, up to the formation of the primary bone. Periosteum components were appreciated which gave way to fibroblasts and to thick-collagenous tissue, forming parallel bundles which interconnected with the primary bone, with the latter replacing the hyaline cartilaginous tissue. There was a presence of blood vessels in the fibrous, hyaline regions, in addition to a very thick fibrous scar. In the healthy bone, we observed bone trabeculae with flat osteoblasts, and the formation of new trabeculae with large, cuboid osteoblasts in free proliferation. The formation of loose connective tissue was detected in different areas, with fusiform, star-shaped cells, and abundant blood vessels of different calibres. Towards the lateral area bone trabeculae of varying thicknesses were observed and towards the inside of the bone, the connective tissue was thicker with collagen bundles. This part of the bone also contained mesenchymal cells, islet cells of hyaline cartilage with morphological changes caused by the condensing of the matrix towards a more compact fibrous tissue. In Masson's trichrome stains (Fig. 1) for the same Group we observed the presence of a large, fibrous scar between the newly forming bone trabeculae which was a continuation of pre-existing trabeculae. Collagen fibres were forming and integrating into the trabeculae. Loose fibrous cartilaginous tissue was detected, hypertrophying towards a thick tissue. There were numerous osteoclasts in the periphery of the new formation trabeculae which suggested restoration of the centre towards the periphery. In the endosteum region, macrophages and osteoclasts were observed which had migrated towards the newly

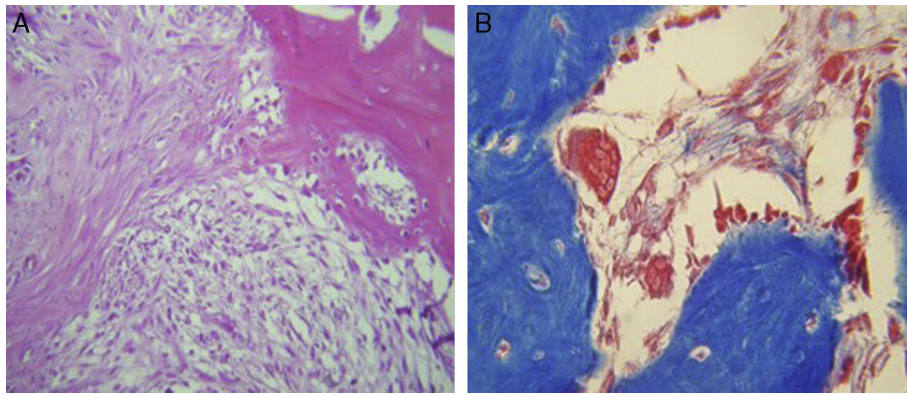


Figure 1 Histological staining with haematoxylin and eosin, and Masson's trichrome staining for group A. A non organised repair tissue is observed with fibrous features, with a large quantity of osteoclasts and cartilaginous areas (HE 20 \times , TM 40 \times).

formed bone trabeculae. At the scar site, bone breakdown was actively enabling bone tissue to develop.

For Group B, in the haematoxylin and eosin (Fig. 2) staining the general observation was larger areas of hyaline cartilage, and transitions of fibrous tissue to cartilaginous tissue until the tissue became osteo collagenous. A more organised tissue was clearly distinguished with regard to the bone repair phases in comparison with the Group A slices. The fibrous tissue was observed to be more consistent with regards to how the collagen fibres were arranged in their integration with the trabeculae. In all the Masson trichrome stained slices (Fig. 3), it was observed that there was profuse fibrous tissue which was very thick and compact. In general, presence of osteoclasts in the fibrin areas was low, and the fibrin was thinner. Few macrophages and osteoclasts were observed in the repair bone trabeculae ends. Towards the bone periphery, a more organised and fibrous periosteum was observed. In the central area of the bone there was a concentration of osteoclasts and thick, compact bundles, running perpendicularly to the collagen fibres.

The x-ray images of both groups were digitalised. The first x-rays were made 15 days after surgery and the second ones 30 days after surgery. For both groups, in the new growth area in general a predominant radio lucid area was observed with little presence in radio-opaque areas, which were selected for analysis and subsequently compared

between the different days. The mean of the values from the densitometric analysis was estimated at 15 days as 113.66 and at 30 as 117.71. When the paired samples were tested, we found a difference of 4.05 with a p value of 0.163, and there was therefore no statistical difference in the bone density from a radiographical viewpoint (Table 1). For the group which received stimulus (Group B), 15 days after treatment a mean of 65.60 was found and at 30 days a density mean of 126.66 was found. When data were paired, a difference of 61.06 was found with a p value of $p=0.03$, which indicates a significant difference (Table 2). On comparing both Groups with their respective p values, we found a statistically significant difference as equal variances had not been assumed (Table 3).

Discussion

Non unions continue to be the primary complication in fracture treatment.²² It is known that they affect from 5% to 10% of the 7.9 million fractures which occur annually in the United States.²³ The socio economic burden associated with fracture repair, including hospital costs and loss of salaries is considerable.^{24,25} These complications support the need for innovative therapies to optimise fracture healing. Electromagnetic stimulation is a non-invasive technology that improves fracture healing.²⁶⁻²⁸ The use of

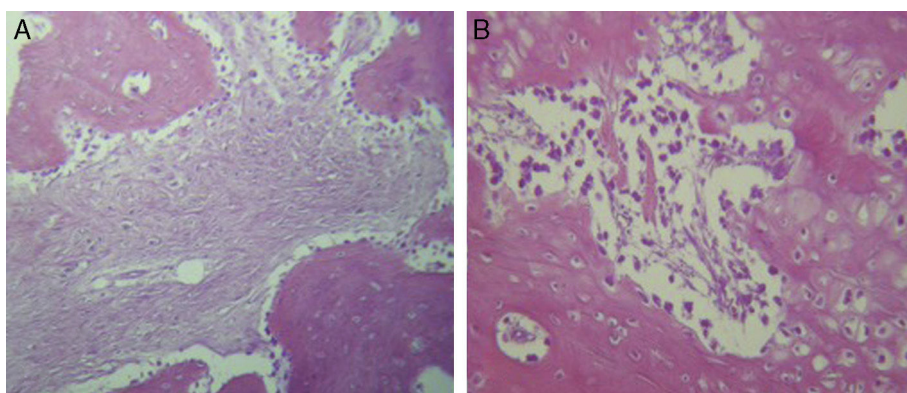


Figure 2 Histological staining with haematoxylin and eosin for group B. (A and B) The repair tissue is more organised and with extensive areas of cartilaginous tissue, and reduced presence of osteoclasts (HE 20 \times).

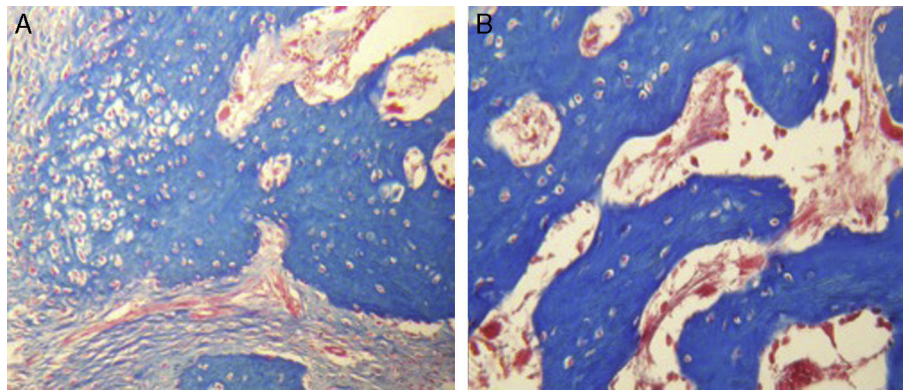


Figure 3 Histological staining with Masson's trichrome staining for group B. (A and B) the repair tissue contains thick, compact collagen fibres. At the end of the trabeculae in repair there are few macrophages and osteoclasts (TM 20 \times).

Table 1 Difference of paired samples for group A.

		Test of paired samples ^a					t	gl	Sig. (bilateral)
		Paired differences							
		Mean	Standard deviation	Standard error mean	95% of confidence interval of the difference				
				Inferior Superior					
Par 1	15 days–30 days	–4.053	3.24516	1.87359	–12.114	4.00808	–2.1	2	0.163

^a Without/with stimulus = without stimulus.

Table 2 Difference of paired samples for group B.

		Paired sample test ^a					t	gl	Sig. (bilateral)
		Paired differences							
		Mean	Standard deviation	Standard error mean	95% confidence interval of the difference				
				Inferior Superior					
Par 1	15 days–30 days	–61.060	20.17079	11.54561	–111.167	–10.95298	–5.24	2	0.035

^a Without/with stimulus = no stimulus.

electromagnetic stimulation in the treatment of fractures without sufficient union began in the mid 1800s.^{29,30} In 1957, Fukada and Yasuda³¹ demonstrated that there was a relationship between electricity and callus formation. Recent studies have shown that electromagnetic stimulation could have a direct impact on many cellular pathways, including the synthesis of growth factors,^{32–34} in proteoglycans, in the regulation of collagen^{35,36} and the production of cytokines.³⁷ These pathways allow the bone to respond to changes in the environment, and respond to the stimulation of the calcium-calmoduline pathways and thus promote bone consolidation.^{24,38} Several random trials have assessed the effect of electromagnetic stimulation in bone consolidation, but clinical findings vary.^{39,40}

The aim of our study was to demonstrate the efficacy of electro-stimulation, through the use of a direct alternating current applied with a closed circuit device with graduated voltage, in the maturing of a tissue obtained by distraction in bone lengthening, and thus accelerate the consolidation process (on average 30 days), specifically focused on elongation. Eyres et al.⁴¹ explored the use of electro-magnetic stimulation in lengthening procedures in the lower extremity and reported a statistically significant improvement in bone density, in the group who underwent surgery 12 months after treatment, in segments proximal to the osteotomy. Borsalino et al.⁴² reported an increase in the callus and in the trabecular bridge with electro-magnetic stimulation in the middle and lateral cortex at 40 and 90 days, and an improvement

Table 3 Student's *t*-test for equality of means.

	Independent sample test								
	Levene test of variance quality		Student's <i>t</i> -test for equality of means						
	<i>F</i>	Sig.	<i>t</i>	gl	Sig. (bilateral)	Difference of means	Difference of standard error	95% of confidence interval of the difference	
								Inferior	Superior
<i>Difference without stimulus</i>									
Equal variances are assumed	9.07	0.039	-4.8	4	0.008	-57.00667	11.79536	-89.7558	-24.25749
No equal variances are assumed			-4.8	2.10	0.036	-57.00667	11.79536	-105.439	-8.57407

in osseous callus density 90 days in patients who underwent a femoral intertrochanteric osteotomy.

In our experimental study with an animal model in dogs, the x-ray images corresponding to 15 and 30 days after surgery were analysed. For the group without any type of eclectic stimulus (Group A) it was found that there was no significant difference in bone density between the established analysis periods, with 4.05 ± 3.24 ($p = 0.163$). For the group where electro-stimulation had been applied (Group B), a significant difference was found between the 15 and 30 days of electric stimulus, with a value of 61.06 ± 20.17 ($p = 0.03$). On comparing the data from both groups (with and without electro-stimulation), statistical difference may be assumed due to the differences found between the variances (0.036).

Since the majority of studies based on electro-stimulation report clinical and radiographical findings, it was difficult to compare our study with others where histological slices of an animal model were used. Chen et al.⁴³ examined the evolution of an osteotomy histologically to determine the effect of postsurgical electric stimulation, in bone repair of a facial model in rats. They applied a $20 \mu\text{A}$ current at the osteotomy site, but subcutaneously. They analysed the histological slices to determine the healing process of the osteotomy. Their results did not show any statistically significant differences between the 3 groups of animals ($p > 0.005$).

In our study for the group which did not received electro-stimulation, when the histological slices were analysed, we observed that the repair tissues had fibrous features, areas of cartilage with transition towards the bone matrix, i.e. the primary bone structure. We also observed periosteum components which gave way to fibroblasts and to thick-collagenous tissue, forming parallel bundles which interconnected with the primary bone, with the latter replacing the hyaline cartilaginous tissue. In the Masson's trichrome staining we observed the presence of a fibrous scar between the new growth bone trabeculae which extended to the pre-existing trabeculae. There was also a large amount of osteoclasts in the periphery of the newly growing trabeculae, which indicated repair from the centre

outwards. In the group where a direct electric stimulation of $20 \mu\text{A}$ had been applied, better organised tissue was observed, for the bone repair stages, compared with the group A specimens, together with larger areas of hyaline cartilage, transitions of fibrous tissue which extended to an osteocollagenous one. There was little presence of osteoclasts in the fibrin areas.

Petersson and Johnell⁴⁴ described an experimental model in rabbit tibia, where a delayed union was established by using a silicon spacer on the site of the osteotomy for 48 days. When the spacer was removed, an electric transistor of continuous current regulated to $20 \mu\text{A}$ was applied through stainless steel electrodes, to stimulate the osteogenesis on the right-hand side for 62 days. A simulated operation was performed on the left-hand side, inserting stainless steel electrodes with no current: a well formed callus was formed on the stimulated side and on the control side there was synostosis between the ends of the fibula and tibia. Their end report was that there had been no significant difference in the formation of synostosis between the right and left side, and no adverse histological effect was provoked by the electric current.

Conclusions

Under the conditions of our study using the animal model, we observed a significant radiographic difference in the growth and formation of callus at 15 and 30 days. Histologically we observed more organised tissue when electro-stimulation was applied in the animal model of osteosynthesis at 15 and 30 days. A significance in consolidation time in the group with electro-stimulation (Group B) was demonstrated by x-ray and laboratory studies.

Ethical disclosures

Protection of human and animal subjects. The authors declare that the procedures followed were in accordance with the regulations of the relevant clinical research ethics

committee and with those of the Code of Ethics of the World Medical Association (Declaration of Helsinki).

Confidentiality of data. The authors declare that no patient data appear in this article.

Right to privacy and informed consent. The authors declare that no patient data appear in this article.

Conflict of interests

The authors have no conflict of interests to declare.

Acknowledgements

We would like to thank the staff of the Vivarium of the Department of Physiology of the Faculty of Medicine of the Autonomous University of Nuevo León, for their good care and management of the animals used for this study.

References

- Oestern HJ, Tscherne H. Fractures with soft tissue injuries. Pathophysiology and classification of soft tissue injuries associated with fractures. In: Orthopade. Berlin, Heidelberg: Springer-Verlag; 1983. p. 1–9. Online ISBN 978-3-642-69499-8.
- Gustilo RB, Mendoza RM. Results of treatment of 1,400 open fractures: 24 years experience at Hennepin County Medical Center, Minneapolis, Minnesota. *Iowa Orthop J.* 1982;2:76–9.
- Gruber R, Koch H, Doll BA, Tegtmeyer F, Einhorn TA, Hollinger JO. Fracture healing in elderly patients. *Exp Gerontol.* 2006;41:1080–93.
- Marsh JL, Buckwalter JA, Everts CM. Non-union, delayed union, malunion, and avascular necrosis. In: Epps CH, editor. *Complications in orthopaedic surgery.* Philadelphia: Lippincott; 1994. p. 183–211.
- Olson SA. Instructional course lectures, The American Academy of Orthopaedic Surgeons – open fractures of the tibial shaft. Current treatment. *J Bone Joint Surg Am.* 1996;78A:1428–37.
- Buckwalter JA. Effects of early motion on healing of musculoskeletal tissues. *Hand Clin.* 1996;12:13–24.
- Aronson J. The biology of distraction osteogenesis. In: Bianchi-Maiocchi A, Aronson J, editors. *Operative principles of Ilizarov: fracture treatment, nonunion, osteomyelitis, lengthening, deformity correction.* Baltimore: Williams & Wilkins; 1991. p. 42–52.
- Monticelli G, Spinelli R. Distraction epiphysiolysis as a method of limb lengthening: III. Clinical applications. *Clin Orthop Relat Res.* 1981;154:274–85.
- Paley D. Current techniques of limb lengthening. *J Pediatr Orthop.* 1988;8:73–92.
- Ilizarov GA. The tension-stress effect on the genesis and growth of tissues: Part I. The influence of stability of fixation and soft-tissue preservation. *Clin Orthop Relat Res.* 1989;238:249–81.
- Peña Martínez VM, Mendoza Lemus OF, Garay MD. Fracturas complejas de plañon tibial, evaluación de tratamiento con fijación externa. *Rev Fij Ext.* 2006;9:24–30.
- Dahl MT, Gulli B, Berg T. Complications of limb lengthening. A learning curve. *Clin Ortop.* 1994;301:10–8.
- Catagni MA, Bolano L, Cattaneo R. Management of fibular hemimelia using the Ilizarov method. *Orthop Clin North Am.* 1991;22:715–22.
- De Bastiani G, Apley G, Goldberg A. Orthofix external fixation. In: *Trauma and orthopaedics.* Springer; 1997. p. 518–20.
- Boyer A (Stevens AH, Trans.) *Traite des maladies chirurgicales [Treatise in surgical diseases and the operations].* NY: Swords T, Swords J, Pearl-Street; 1816. p. 86.
- Yoshida T, Kim WC, Kubo T. Bone fracture and the healing mechanisms. Fracture treatment using electrical stimulation. *Clin Calcium.* 2009;19:709–17.
- Kim IS, Song JK, Song YM, Cho TH, Lee TH, Lim SS, et al. Novel effect of biphasic electric current on in vitro osteogenesis and cytokine production in human mesenchymal stromal cells. *Tissue Eng Part A.* 2009;15:2411–22.
- Kim IS, Song JK, Zhang YL, Lee TH, Cho TH, Song YM, et al. Biphasic electric current stimulates proliferation and induces VEGF products in osteoblasts. *Biochim Biophys Acta.* 2006;1763:907–16.
- Hodges SD, Eck JC, Humphreys CS. Use of electrical bone stimulation in spinal fusion. *J Am Acad Orthop Surg.* 2003;11:81–8.
- Bozic KJ, Glazer PA, Zurakowski D, Simon BJ, Lipson SJ, Hayes WC. In vivo evaluation of coralline hydroxyapatite and direct current electrical stimulation in lumbar spinal fusion. *Spine.* 1999;24:2127–33.
- Morshed S, Corrales L, Genant H, Miclau T III. Outcome assessment in clinical trials of fracture-healing. *J Bone Joint Surg Am.* 2008;90:62–7.
- Megas P. Classification of non-union. *Injury.* 2005;36:30–7.
- Hamilton PT, Jansen MS, Ganesan S, Benson RE, Hyde-DeRuyscher R, Beyer WF, et al. Improved bone morphogenetic protein-2 retention in an injectable collagen matrix using bifunctional peptides. *PLoS ONE.* 2013;8:e70715.
- Nelson FR, Brighton CT, Ryaby J, Simon BJ, Nielson JH, Lorich DG, et al. Use of physical forces in bone healing. *J Am Acad Orthop Surg.* 2003;11:344–54.
- Heckman JD, Sarasohn-Kahn J. The economics of treating tibia fractures. The cost of delayed unions. *Bull Hosp Joint Dis.* 1997;56:63–72.
- Einhorn TA. Enhancement of fracture-healing. *J Bone Joint Surg Am.* 1995;77:940–56.
- Anglen J. The clinical use of bone stimulators. *J South Orthop Assoc.* 2003;12:46–54.
- Karamitros AE, Kalentzos VN, Soucacos PN. Electric stimulation and hyperbaric oxygen therapy in the treatment of nonunions. *Injury.* 2006;37:563–73.
- Hartshorne E. Monograph on the causes and treatment of pseudarthrosis and especially of that form of it sometimes called supranumery joint. *Am J Med Sci.* 1841;1:121–56.
- Lente RW. Cases of un-united fracture treated by electricity. *NY State J Med.* 1850;5:317–9.
- Fukada E, Yasuda I. On the piezoelectric effect of bone. *J Phys Soc Jpn.* 1957;12:1158–69.
- Aaron RK, Boyan BD, Ciombor DM, Schwartz Z, Simon BJ. Stimulation of growth factor synthesis by electric and electromagnetic fields. *Clin Orthop Relat Res.* 2004;419:30–7.
- Guerkov HH, Lohmann CH, Liu Y, Dean DD, Simon BJ, Heckman JD, et al. Pulsed electromagnetic fields increase growth factor release by nonunion cells. *Clin Orthop Relat Res.* 2001;384:265–79.
- Lohmann CH, Schwartz Z, Liu Y, Li Z, Simon BJ, Sylvia VL, et al. Pulsed electromagnetic fields affect phenotype and connexin 43 protein expression in MLO-Y4 osteocyte-like cells and ROS 17/2.8 osteoblast-like cells. *J Orthop Res.* 2003;21:326–34.
- Ciombor DM, Aaron RK. The role of electrical stimulation in bone repair. *Foot Ankle Clin.* 2005;10:579–93.
- Heermeier K, Spanner M, Träger J, Gradinger R, Strauss PG, Kraus W, et al. Effects of extremely low frequency electromagnetic field (EMF) on collagen type I mRNA expression and extracellular matrix synthesis of human osteoblastic cells. *Bioelectromagnetics.* 1998;19:222–31.
- Spadaro JA. Mechanical and electrical interactions in bone remodeling. *Bioelectromagnetics.* 1997;18:193–202.

38. Haddad JB, Obolensky AG, Shinnick P. The biologic effects and the therapeutic mechanism of action of electric and electromagnetic field stimulation on bone and cartilage: new findings and a review of earlier work. *J Altern Complement Med.* 2007;13:485–90.
39. Scott G, King JB. A prospective, double-blind trial of electrical capacitive coupling in the treatment of non-union of long bones. *J Bone Joint Surg Am.* 1994;76:820–6.
40. Betti E, Marchetti S, Cadossi R, Faldini C, Faldini A. Effect of stimulation by low-frequency pulsed electromagnetic fields in subjects with fracture of the femoral neck. In: Bersani F, editor. *Electricity and magnetism in biology and medicine.* New York: Kluwer Academic/Plenum; 1999. p. 853–5.
41. Eyres KS, Saleh M, Kanis JA. Effect of pulsed electromagnetic fields on bone formation and bone loss during limb lengthening. *Bone.* 1996;18:505–9.
42. Borsalino G, Bagnacani M, Bettati E, Fornaciari F, Rocchi R, Uluhogian S, et al. Electrical stimulation of human femoral intertrochanteric osteotomies. Double-blind study. *Clin Orthop Relat Res.* 1988;237:256–63.
43. Chen HL, Killiany DM, Waheed-Uz-Zaman RM. Bone healing with electric current: a histological assessment. *Clin Orthod Res.* 2000;3:123–31.
44. Petersson CJ, Johnell O. Electrical stimulation of osteogenesis in delayed union of the rabbit fibula. *Arch Orthop Trauma Surg.* 1983;101:247–50.