



# CIRUGÍA y CIRUJANOS

Órgano de difusión científica de la Academia Mexicana de Cirugía  
Fundada en 1933

[www.amc.org.mx](http://www.amc.org.mx) [www.elsevier.es/circir](http://www.elsevier.es/circir)



## CLINICAL CASE

### Role of care surgery in the treatment of pseudomembranous colitis<sup>☆</sup>



Luis Tallón-Aguilar\*, Pablo de la Herranz-Guerrero, José Antonio López-Ruiz, Laura Sánchez-Moreno, José López-Pérez, Francisco Javier Padillo-Ruiz

Unidad de Cirugía de Urgencias, Complejo Hospitalario Universitario de Sevilla Virgen Macarena – Virgen del Rocío, Seville, Spain

Received 17 July 2015; accepted 15 March 2016  
Available online 4 August 2017

#### KEYWORDS

Pseudomembranous colitis;  
*Clostridium difficile*;  
Surgery

#### Abstract

**Background:** Pseudomembranous colitis, caused by *Clostridium difficile*, has seen an increased incidence in recent years, driven mainly by the indiscriminate use of antibiotics. Although initial treatment is medical, the role of emergency surgery has gained ground due to high mortality and the emergence of increasingly virulent strains. In our country the prevalence is still low so that sometimes our experience in handling is limited.

**Aim:** To analyze our surgical experience in treatment of this disease and to remember the role of surgery as well as some technical aspects of it.

**Clinical cases:** We present 2 cases of patients who have suffered a fulminant pseudomembranous colitis unresponsive to initial medical treatment and requiring urgent surgical intervention with a good response to it.

**Conclusions:** It is important to keep in mind the surgical option in treatment of pseudomembranous colitis, especially when it presents as fulminant colitis, there are associated complications or failure to respond to medical treatment.

© 2016 Academia Mexicana de Cirugía A.C. Published by Masson Doyma México S.A. This is an open access article under the CC BY-NC-ND license (<http://creativecommons.org/licenses/by-nc-nd/4.0/>).

#### PALABRAS CLAVE

Colitis pseudomembranosa;  
*Clostridium difficile*;  
Cirugía

#### Papel de la cirugía en el tratamiento de la colitis pseudomembranosa

#### Resumen

**Antecedentes:** La colitis pseudomembranosa, producida por el *Clostridium difficile*, presenta una incidencia creciente en los últimos años, motivada principalmente por el uso indiscriminado de antibióticos. Aunque su tratamiento de inicio es médico, el papel de la cirugía de urgencias

<sup>☆</sup> Please cite this article as: Tallón-Aguilar L, de la Herranz-Guerrero P, López-Ruiz JA, Sánchez-Moreno L, López-Pérez J, Padillo-Ruiz FJ. Papel de la cirugía en el tratamiento de la colitis pseudomembranosa. Cir Cir. 2017;85:330–333.

\* Corresponding author at: c/ Asunción 26 2<sup>a</sup>, 41011 Seville, Spain.  
E-mail address: [ltallona@hotmail.com](mailto:ltallona@hotmail.com) (L. Tallón-Aguilar).

ha ido ganando terreno debido a una mortalidad elevada y a la aparición de cepas cada vez más virulentas. En nuestro medio su prevalencia aún es escasa, por lo que en ocasiones nuestra experiencia en su manejo es limitada.

**Objetivo:** Analizar nuestra experiencia quirúrgica en el tratamiento de esta dolencia y recordar el rol de la cirugía, así como alguno de sus aspectos técnicos.

**Casos clínicos:** Presentamos 2 casos clínicos de pacientes que han presentado un cuadro de colitis pseudomembranosa de presentación fulminante, sin respuesta al tratamiento médico inicial, por lo que se requiere una actuación quirúrgica urgente, con buena respuesta.

**Conclusiones:** Es importante siempre tener en mente la posibilidad quirúrgica en el tratamiento de la colitis pseudomembranosa, sobre todo cuando se presenta de manera fulminante, existen complicaciones asociadas o falla de respuesta al tratamiento médico.

© 2016 Academia Mexicana de Cirugía A.C. Publicado por Masson Doyma México S.A. Este es un artículo Open Access bajo la licencia CC BY-NC-ND (<http://creativecommons.org/licenses/by-nc-nd/4.0/>).

## Background

*Clostridium difficile* is a Gram-positive bacteria microorganism that forms part of normal intestinal flora in a few healthy individuals and hospitalised patients.<sup>1</sup> It was first described as a microbiota in neonates, but it was not until 1978 that it was identified as a cause of pseudomembranous colitis associated with the use of antibiotics.<sup>2,3</sup>

The spectrum of diseases caused by *C. difficile* ranges from uncomplicated diarrhoea to serious conditions such as fulminant pseudomembranous colitis or toxic megacolon. Although the initial treatment of choice is non-surgical, if this proves ineffective, surgery should be considered.<sup>4</sup>

The epidemiology of this disease has changed considerably in recent decades. It is even suggested that it will become a global pandemic due to the indiscriminate use of antibiotics, as prophylactic treatment in the form of broad-spectrum antibiotics, and with the appearance of hypervirulent strains (ribotype 027).<sup>5</sup>

Its prevalence in Spain in the period 1999–2007 increased from 39 to 122 cases, with an annual increase of 9%. This was put down to indiscriminate use of antibiotics, the ageing population and increased inpatient comorbidity. Even so, the incidence in our country is lower than other countries such as the United States, Canada or the United Kingdom and, as yet, no cases caused by hypervirulent strains have been described.<sup>6–8</sup>

Since the discovery of this hypervirulent strain, a trend towards more severe forms of colitis has been observed with poorer outcomes. This has placed the emphasis on establishing appropriate treatment regimens, especially for refractory infections. In mild to moderate cases, oral metronidazole is considered an appropriate first line of treatment but, in the absence of an appropriate clinical response, a switch to vancomycin is required. Thus, oral vancomycin should be used as the initial therapy in severe cases or in patients who are intolerant to metronidazole. The rectal route should be reserved for supplementary therapy in severe cases. Patients who cannot tolerate oral administration should be given intravenous metronidazole or rectal vancomycin. Surgical consultation should be prompt for patients presenting colitis that is refractory to treatment

or fulminant colitis, since they can require urgent surgical intervention in up to 1–3% of cases.<sup>9,10</sup>

## Clinical cases

### Case 1

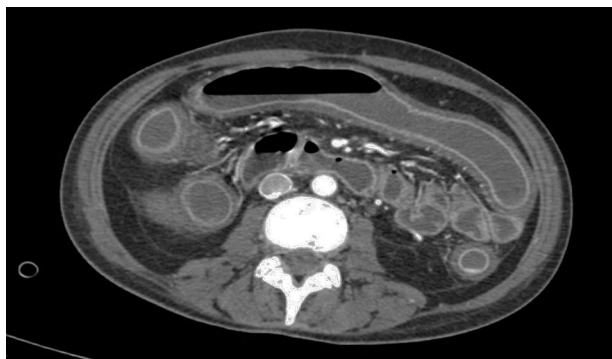
A 37-year-old woman with a history of acute lymphoblastic leukaemia under chemotherapy treatment. The patient started with symptoms of abdominal pain accompanied by vomiting, diarrhoea and fever which did not remit despite having been treated previously with amoxicillin/clavulanic acid, azithromycin and amphotericin. After testing positive for *C. difficile* toxin in her faeces, treatment was commenced with parenteral metronidazole. After an improvement in symptoms, the patient was discharged from hospital under treatment with oral vancomycin.

The patient returned a few days later with septic symptoms which required her to be admitted to the Intensive Care Unit, and treated with vaso-active drugs and orotracheal intubation. Due to the patient's failure to respond to treatment in the first 24 h, emergency surgery was decided. A subtotal colectomy and terminal ileostomy was performed. After surgery the patient improved significantly with progressive reduction of amines until they were withdrawn, orotracheal extubation, with negativisation of toxin in faeces (Figs. 1 and 2).

### Case 2

A 72-year-old woman admitted to the Neurology Department due to a subarachnoid haemorrhage. She had a history of treatment with amoxicillin/clavulanic acid prior to admission.

Her symptoms became worse with abdominal pain, diarrhoea and bradypsychia. Ischaemic colitis was suspected after abdominal tomography; however colonoscopy suggested a first possible diagnosis of pseudomembranous colitis. Despite medical treatment the patient did not improve and developed septic shock and multiple organ failure. Emergency surgical intervention was decided and subtotal colectomy and terminal ileostomy performed. After



**Figure 1** Axial computed tomography image of clinical case 1, showing oedema, thickening of the colonic wall, and loss of haustration, characteristic of this disease.

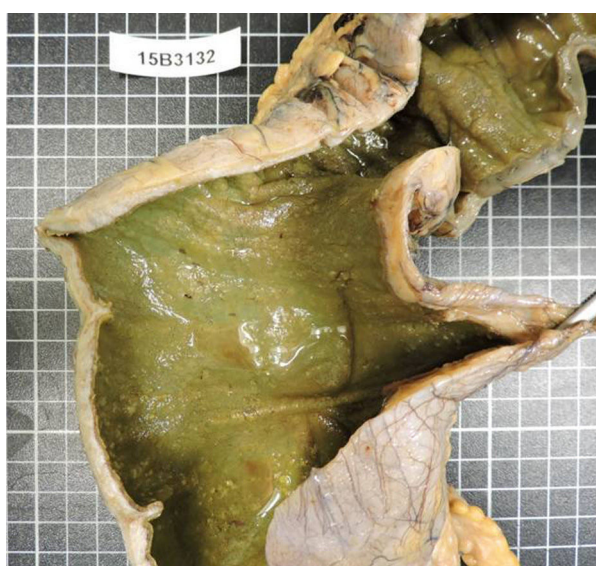surgery the patient presented clear improvement and was discharged a few days later (Fig. 3).

## Discussion

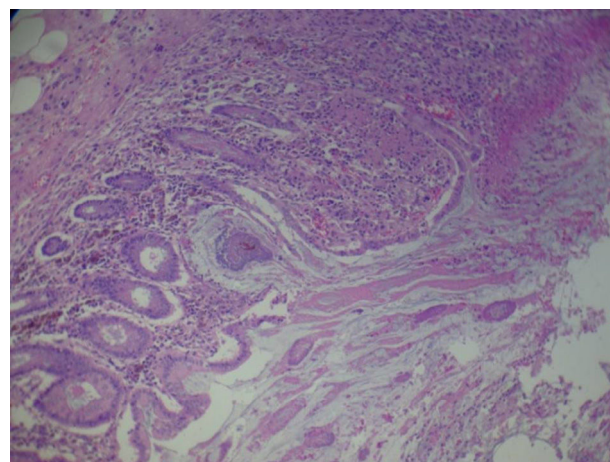
Fulminant colitis presents in 3–10% of cases. It involves concomitant systemic toxicity, organ malfunction with the need for vasoactive drugs or ventilatory support. Up to 20% of cases can require surgery; nevertheless there is a 35% and 80% mortality rate.<sup>11</sup>

Historically, surgery was seldom used due to the poor outcomes traditionally demonstrated. This was because the published series were small and there was no standard definition of fulminant colitis.<sup>12</sup>

It has currently been established that surgery can save lives in some cases, and that most patients require total or subtotal colectomy with terminal ileostomy. In terms of surgical technique, resection should include removal of the sigmoid colon, preserving the rectum and the pelvic tissues



**Figure 2** Image of the surgical specimen from clinical case 1, showing the pseudomembranes that are characteristic of this disease in the colonic wall.



**Figure 3** Microscopic image of the surgical specimen from clinical case 2, showing the histology of the pseudomembranes (haematoxylin and eosin staining).

to enable the hypothetical posterior reconstruction of the intestinal tract.<sup>13</sup>

By contrast, some authors currently suggest minimally invasive surgery, whereby the colon is preserved, as a surgical alternative. Thus a reduction in the morbidity and mortality associated with the surgical procedure is achieved. This technique is based principally on creating an ileostomy using the laparoscopic approach, colonic irrigation and topical administration of vancomycin. The authors put this efficacy down to less aggression being caused to the critical patient and the removal of any faecal bolus, which will prevent the influx of nutrients to the intestinal flora.<sup>14</sup> Although this technique had already been described in 1971 by Turnbull et al.,<sup>15</sup> in cases of toxic megacolon secondary to inflammatory bowel disease as a bridging procedure to achieve improved clinical symptoms before definitive elective surgery, it was seldom performed in the past.

Surgery is indicated in the case of any of the following factors: perforation or necrosis of the colon wall, the need for vasoactive drugs, signs of sepsis, changes in mental state, leukocytosis above 50,000, lactic acid greater than

**Table 1** Risk factor score for pseudomembranous colitis.

Criterion	Score
Immunosuppression	1 point
Abdominal pain or distension	1 point
Hypoalbuminaemia < 3 g/dl	1 point
Fever	1 point
Admission to Intensive Care Unit	1 point
Wall thickening or ascitis (CAT)	2 points
Leukocytes > 15,000 to <1500/mm <sup>3</sup>	2 points
Creatinine > 1.5 normal value	2 points
Peritoneal irritation	3 points
Need for amines	5 points
Need for ventilation	5 points
Confusion, disorientation	5 points

Pseudomembranous colitis score proposed by Neal et al.<sup>17</sup>

**Table 2** Severity of pseudomembranous colitis according to risk factors.

Level of severity	Score
Mild	1–3
Severe	4–6
Severe complicated	≥7

5 mmol/l, or if there has been no clinical improvement after 5 days of treatment.<sup>16</sup>

Similarly, Neal et al.<sup>17</sup> described a specific points system for this disorder, classifying it in terms of severity according to the total factors presented by the patient: mild is from 1 to 3 points, severe from 4 to 6 points, severe, complicated ≥7 (Tables 1 and 2). However, no specific indications have been established with regard to surgery, since the score necessary to indicate it has not yet been established.

## Conclusion

The treatment of choice for pseudomembranous colitis is medical, reserving surgery for specific cases. Surgery is being performed increasingly promptly for this disorder and therefore is less aggressive, which has achieved better outcomes. Therefore we consider it is important to bear in mind the possibility of surgery to treat the disorder, especially when the condition is fulminant, when there are associated complications or when there is failure to respond to medical treatment.

## Ethical disclosures

**Protection of human and animal subjects.** The authors declare that the procedures followed were in accordance with the regulations of the relevant clinical research ethics committee and with those of the Code of Ethics of the World Medical Association (Declaration of Helsinki).

**Confidentiality of data.** The authors declare that they have followed the protocols of their work center on the publication of patient data.

**Right to privacy and informed consent.** The authors have obtained the written informed consent of the patients or subjects mentioned in the article. The corresponding author is in possession of this document.

## Conflict of interests

The authors have no conflict of interests to declare.

## References

- Ryan KJ, Ray CG, editors. Sherris medical microbiology. 4th ed. McGraw Hill; 2004. p. 322–4.
- Bartlett JG. Historical perspectives on studies of *Clostridium difficile* and *C. difficile* infection. Clin Infect Dis. 2008;46 Suppl. 1:54–11.
- George WL, Goldstein EJ, Sutter VL, Ludwig SL, Finegold SM. Aetiology of antimicrobial-agent-associated colitis. Lancet. 1978;311:802–3.
- Abe I, Kawamura YJ, Sasaki J, Konishi F. Acute fulminant pseudomembranous colitis which developed after ileostomy closure and required emergent total colectomy: a case report. J Med Case Rep. 2012;6:130.
- Asensio Á, Bouza E, Grau S, Rubio-Rodríguez D, Rubio-Terréz C. Coste de la diarrea asociada a *Clostridium difficile* en España. Rev Esp Salud Pública. 2013;87:25–33.
- Asensio A, Monge D. Epidemiología de la infección por *Clostridium difficile* en España. Enferm Infecc Microbiol Clin. 2012;30:333–7.
- Asensio A, Vaque-Rafart J, Calbo-Torrecillas F, Gestal-Otero JJ, López-Fernández F, Trilla-García A, et al., EPINE Working Group. Increasing rates in *Clostridium difficile* infection (CDI) among hospitalised patients, Spain 1999–2007. Euro Surveill. 2008;13:350–3.
- Rodríguez Pardo D, Almirante B, Bartolomé RM, Pomar V, Mirelis B, Navarro F, et al. Epidemiology of *Clostridium difficile* infection and risk factors for unfavorable clinical outcomes: results of a hospital-based study in Barcelona, Spain. J Clin Microbiol. 2013;51:1465–73.
- Shen EP, Surawicz CM. Current treatment options for severe *Clostridium difficile*-associated disease. Gastroenterol Hepatol. 2008;4:134–9.
- Al-Abed YA, Gray EA, Rothnie ND. Outcomes of emergency colectomy for fulminant *Clostridium difficile* colitis. Surgeon. 2010;8:330–3.
- Markelov A, Livert D, Kohli H. Predictors of fatal outcome after colectomy for fulminant *Clostridium difficile* colitis: a 10-year experience. Am Surg. 2011;77:977–80.
- Klobuka AJ, Markelov A. Current status of surgical treatment for fulminant *Clostridium difficile* colitis. World J Gastrointest Surg. 2013;5:167–72.
- Koss K, Clark MA, Sanders DS, Morton D, Keighley MR, Goh J. The outcome of surgery in fulminant *Clostridium difficile* colitis. Colorectal Dis. 2006;8:149–54.
- Seltman AK. Surgical management of *Clostridium difficile* colitis. Clin Colon Rectal Surg. 2012;25:204–9.
- Turnbull RB Jr, Hawk WA, Weakley FL. Surgical treatment of toxic megacolon. Ileostomy and colostomy to prepare patients for colectomy. Am J Surg. 1971;122:325–31.
- Luciano JA, Zuckerbraun BS. *Clostridium difficile* infection: prevention, treatment, and surgical management. Surg Clin North Am. 2014;94:1335–49.
- Neal MD, Alverdy JC, Hall DE, Simmons RL, Zuckerbraun BS. Diverting loop ileostomy and colonic lavage. An alternative to total abdominal colectomy for the treatment of severe, complicated *Clostridium difficile* associated disease. Ann Surg. 2011;254:423–9.