




CIRUGÍA y CIRUJANOS

Órgano de difusión científica de la Academia Mexicana de Cirugía
Fundada en 1933

www.amc.org.mx www.elsevier.es/circir



CLINICAL CASE

Diagnosis and treatment of isolated pancreatic metastases from renal clear cell carcinoma: Report of a case and review of literature[☆]



Ricardo Lucas García-Mayor Fernández^{a,*}, María Fernández-González^b

^a Servicio de Cirugía General, Hospital do Salnés, Área de Gestión Integrada Pontevedra-Salnés, Vilagarcía de Arousa, Pontevedra, Spain

^b Servicio de Urgencias, Complejo Hospitalario Universitario de Orense, Orense, Spain

Received 30 November 2015; accepted 20 May 2016

Available online 1 December 2017

KEYWORDS

Pancreatic metastases;
Kidney cancer;
Distal pancreatectomy with splenectomy

Abstract

Background: The development of pancreatic metastases in renal carcinoma is very uncommon.

The aim of the paper is to present a clinical case of this disease and review the clinical presentation, diagnosis, and treatment.

Clinical case: A case is presented of a 72-year-old female, with a history of renal carcinoma in the right kidney treated by total nephrectomy. At follow-up, in a radiological control, a suspicious metastatic pancreatic lesion was detected. A distal pancreatectomy with splenectomy was performed, and histopathology confirmed the origin as metastatic renal cancer.

Conclusions: Pancreatic metastases from renal cancer are very rare, and are usually diagnosed in the monitoring the primary cancer (because most of them are asymptomatic). The treatment for isolated resectable pancreatic metastases without extra-pancreatic extension is surgical resection.

© 2016 Academia Mexicana de Cirugía A.C. Published by Masson Doyma México S.A. This is an open access article under the CC BY-NC-ND license (<http://creativecommons.org/licenses/by-nc-nd/4.0/>).

PII of original article: S0009-7411(16)30041-X

[☆] Please cite this article as: Fernández RL, Fernández-González M. Diagnóstico y tratamiento de una metástasis pancreática única de un cáncer renal de células claras: a propósito de un caso y revisión de la literatura. Cir Cir. 2017;85:436–439.

* Corresponding author at: C/ Conde de Torrecedeira No. 50, 1.º E, C.P. 36202, Vigo (Pontevedra), Spain. Tel.: +34 62629 9612.

E-mail address: lucasgarciamayor@gmail.com (R.L.G.-M. Fernández).

2444-0507/© 2016 Academia Mexicana de Cirugía A.C. Published by Masson Doyma México S.A. This is an open access article under the CC BY-NC-ND license (<http://creativecommons.org/licenses/by-nc-nd/4.0/>).

PALABRAS CLAVE

Metástasis
pancreática;
Cáncer de riñón;
Pancreatectomía
distal con
esplenectomía

Diagnóstico y tratamiento de una metástasis pancreática única de un cáncer renal de células claras: a propósito de un caso y revisión de la literatura

Resumen

Antecedentes: El desarrollo de metástasis pancreáticas de un cáncer de células renales es muy infrecuente.

El objetivo del trabajo es presentar un caso clínico de esta enfermedad y realizar una revisión de la presentación clínica, del diagnóstico y tratamiento.

Caso clínico: Paciente mujer de 72 años, con antecedentes de carcinoma renal derecho, tratado mediante nefrectomía total. En el seguimiento se detectó en un control radiológico una lesión pancreática, sospechosa de metástasis. Se realizó una pancreatectomía distal con esplenectomía. A través del estudio histopatológico se confirmó el origen metastásico del cáncer renal.

Conclusiones: La metástasis pancreática de un cáncer de riñón es muy rara y suele diagnosticarse en el seguimiento de la neoplasia primaria (ya que la mayoría son asintomáticos). El tratamiento de elección de una metástasis pancreática solitaria, reseccable sin extensión extrapancreática, es la resección quirúrgica.

© 2016 Academia Mexicana de Cirugía A.C. Publicado por Masson Doyma México S.A. Este es un artículo Open Access bajo la licencia CC BY-NC-ND (<http://creativecommons.org/licenses/by-nc-nd/4.0/>).

Background

Isolated pancreatic metastasis is exceptional and may be caused by several primary tumours.¹⁻³

The mechanism causing the production of isolated pancreatic metastases of renal carcinoma may be haematogenic or lymphatic.⁴ Clinical signs will depend on the site and are similar to those produced by a primary pancreatic tumour (obstructive jaundice, intestinal bleeding, abdominal pain, weight loss, pancreatitis, diabetes mellitus, etc.).² They are asymptomatic in up to 50% of cases and are usually diagnosed in the follow-up of primary neoplasia.^{1,5-10}

In computed tomography and magnetic resonance they present as highly vascularised lesions, usually very large in size, with well defined margins,^{1,2} which may be confused with a primary neuroendocrine tumour of the pancreas,¹⁻³ and complementary tests are therefore undertaken to establish a differential diagnosis.

The treatment of choice for isolated resectable pancreatic metastases without extra-pancreatic extension is resection. Site conditions the technique to employ, with corresponding oncological criteria, to obtain a safety margin.^{1,2,4}

There follows the clinical case of this rare entity and a review of the literature.

Clinical case

A case is presented of a 72-year-old female, with a history of high blood pressure and gynaeco-obstetric treatment for ovarian bleeding, 45 years ago, for which laparotomy was performed through appendectomy. She was operated on for clear cell renal cancer in the right kidney and was treated by total nephrectomy. Successive computed tomography controls were carried out, initially 6 months after surgery and subsequently each year. Three years after the right

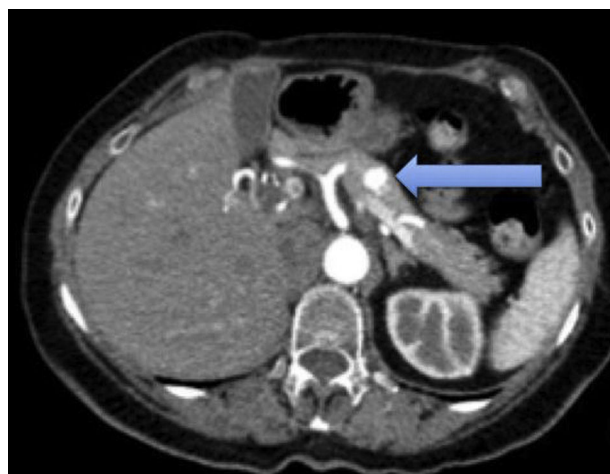


Figure 1 Axial slice of computed tomography of the abdomen without intravenous contrast in arterial phase. A hypervascular lesion of 11 mm diameter is observed in the body of the pancreas, which quickly presents contrast lavage.

nephrectomy a hypervascular nodule was detected in the pancreatic body, which suggested the differential diagnosis between a metastasis and a primary pancreatic neuroendocrine tumour (Figs. 1 and 2).

As a result of these findings, a study with complete hormonal markers and a scan were performed to rule out the primary pancreatic neuroendocrine tumour. The study of the tumour and hormonal markers tested normal. No abnormal accumulations of activity showed up in the scan to indicate the existence of lesions which express somatostatin receptors. On suspicion of pancreatic metastases due to the previous surgical background of the patient, a first diagnostic possibility was indicated to be the performing of a corporocaudal pancreatectomy with open splenectomy. During the operation and with use of a scan, a tumour of

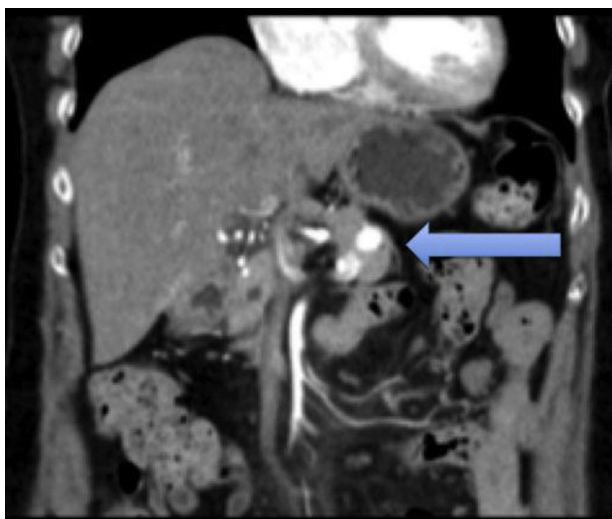


Figure 2 Coronal reconstruction of computed tomography of the abdomen, with intravenous contrast. A hypervascular lesion of 11 mm diameter is observed in the body of the pancreas, which quickly presents contrast lavage.

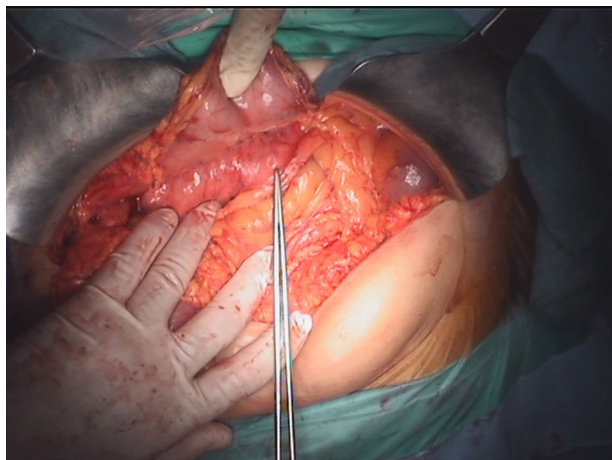


Figure 3 Intraoperative photo. The tumour lesion of soft consistency 1 cm in diameter is observed, situated in the pancreatic body.

approximately 1 cm in diameter was confirmed in the body of the pancreas (Fig. 3), which was later observed as a surgical specimen (Fig. 4).

The postoperative period was free from any complications and the patient was discharged 6 days after the operation. The histopathology report later confirmed metastases of renal clear cell carcinoma, with pancreatic surgical margins free from tumour infiltration. Immunohistochemical techniques were used and showed immunoreactivity in tumours cells to CD10, vimentin and CK AE1-3.

Discussion

Renal cell cancer affects patients in the sixth decade of life. The pancreas is a rare site for metastases of kidney cancer, as they are usually metachronous.^{5,11}

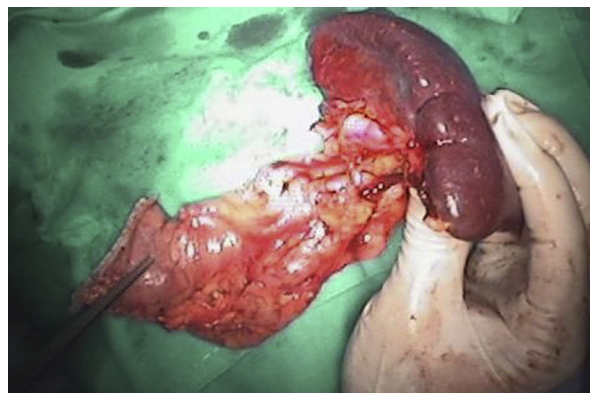


Figure 4 Photo. Part of the anterior part of the surgical specimen is shown, in which the tumour site may be observed.

There is some disagreement regarding which tumour of the body metastasises most frequently to the pancreas. Several data has been published on its distribution which are based on incidental findings during autopsies or during surgery. In one series of autopsies it was reported that the tumours which cause the most pancreatic metastases were: lung (42%), followed by gastrointestinal (24.7%) tract and kidney cancer (4%).¹² However, the most frequently found tumours during surgery were mainly secondary to kidney cancer.⁸ Pancreatic metastasis may be located in the head of the pancreas (41%), be multifocal (22%) or diffusely affect (15%), and are usually single and large.¹

The production mechanism of isolated pancreatic metastases of a renal carcinoma may be haematogenous, through porto-renal or lymphatic shunts but not for direct extension.⁴

Diagnosis of isolated pancreatic metastases is generally an incidental findings during follow-up of kidney cancer, since in up to 50% of cases it may be asymptomatic.^{1,5-10} The remainder may present as: weight loss, obstructive jaundice, abdominal pain or gastrointestinal bleeding.²

In an imaging study there are elements which may also guide diagnosis. The scan describes them as well-defined, hypoechoic nodules. Computed tomography and magnetic resonance are the techniques of choice for examining them^{1,3-5} and they are observed as highly vascularised tumours, the most representative of neuroendocrine or metastatic tumours, as may be appreciated in our case. In contrast, the adenocarcinoma of the pancreas is characteristically hypovascular. In our case, the main differential diagnosis within the imaging study was a tumour of neuroendocrine origin, despite there being no elements in the clinical anamnesis to warrant suspicion. Hormonal and scan tests for somatostatin receptors enable an approximation to diagnosing this type of tumours. Positron emission tomography is used to rule out extra-pancreatic disease, and may be of great use.

When the diagnosis is uncertain, percutaneous or endoscopic biopsy with fine needle aspiration is performed, a high performance method, but there is a high risk of bleeding during the procedure and for this reason it is not usually indicated and these patients must be operated on.^{1,10}

With the immunohistochemistry techniques these cells are immunoreactive to CD10, vimentin and CK AE1-3,¹ which in our case was positive and demonstrated the metastatic origin of the renal clear cells carcinoma.

Survival of patients with kidney cancer with metastasis is poor without resection, around 10% after 5 years. The treatment of choice in pancreatic metastasis from kidney cancer is therefore radical resection, since this considerably improves the patient's chances of survival.^{5,6} If isolated pancreatic metastasis without extra-pancreatic extension which may be technically resected presents, it should be resected.^{1,2,4} The type of technique (cephalic duodeno-pancreatectomy or corporocaudal pancreatectomy) should be adapted to each case, with preservation of a maximum quantity of pancreatic parenchyma as one of the objectives and good margin resection, based on oncological criteria. No adjuvant treatment is effective in kidney cancer metastases.¹

Survival rates published, after pancreatic metastases resection from kidney cancer oscillate between 12 months and 6 years with a mean of 1.3 years (the most favourable outcome is in patients with a primary pancreatic tumour).^{1,2}

Conclusions

Isolated pancreatic metastases of kidney cancer are rare and should be distinguished from primary pancreatic tumours, especially of the neuroendocrine type since they have implications in management and prognosis. Their treatment is surgical resection, which has been shown to significantly increase survival in these patients.

Conflict of interests

The authors have no conflict of interests to declare.

References

1. Thompson LD, Heffess CS. Renal cell carcinoma to the pancreas in surgical pathology material. *Cancer*. 2000;89:1076–88.
2. Z'graggen K, Fernández del Castillo C, Rattner DW, Sigala H, Warshaw AL. Metastases to the pancreas and their surgical extirpation. *Arch Surg*. 1998;133:413–7.
3. Sheth S, Fishman EK. Imaging of uncommon tumors of the pancreas. *Radiol Clin N Am*. 2002;40:1273–87.
4. Kassabian A, Stein J, Jabbour N, Parsa K, Skinner D, Parekh D, et al. Renal cell carcinoma metastatic to the pancreas: a single-institution series and review of the literature. *Urology*. 2000;56:211–5.
5. Ninan S, Prashant KJ, Alan P, Krishna VM. Synchronous pancreatic metastasis from asymptomatic renal cell carcinoma. *J Pancreas*. 2005;6:26–8.
6. Aimoto T, Uchida E, Yamahatsu K, Yoshida H, Hiroi M, Tajiri T. Surgical treatment for isolated multiple pancreatic metastases from renal cell carcinoma: report of a case. *J Nippon Med Sch*. 2008;75:221–4.
7. Maeda A, Uesaka K, Matsunaga K, Kanemoto H, Bando E, Furukawa H. Metastatic tumors of the pancreas. *Pancreas*. 2008;37:234–6.
8. Koide N, Yokoyama Y, Oda K, Nishio H, Ebata T, Abe T, et al. Pancreatic metastasis from renal cell carcinoma: results of the surgical management and pathologic findings. *Pancreas*. 2008;37:104–7.
9. Bassi C, Butturini G, Falconi M, Sargenti M, Mantovani W, Pederzoli P. High recurrence rate after atypical resection for pancreatic metastases from renal cell carcinoma. *Br J Surg*. 2003;90:555–9.
10. Faure JP, Tuech JJ, Richer JP, Pessaux P, Arnaud JP, Carretier M. Pancreatic metastasis of renal cell carcinoma: presentation, treatment and survival. *J Urol*. 2001;165:20–2.
11. Stankard CE, Karl RC. The treatment of isolated pancreatic metastases from renal cell carcinoma: a surgical review. *Am J Gastroenterol*. 1992;87:1658–60.
12. Adsay NV, Andea A, Basturk O, Kilinc N, Nassar H, Cheng JD. Secondary tumors of the pancreas: an analysis of a surgical and autopsy database and review of the literature. *Virchows Arch*. 2004;444:527–35.