



CIRUGÍA y CIRUJANOS

Órgano de difusión científica de la Academia Mexicana de Cirugía
Fundada en 1933

www.amc.org.mx www.elsevier.es/circir



LETTER TO THE EDITOR

Solitary primary splenic lymphangioma[☆]



Linfangioma solitario primario del bazo

We congratulate Dr. Rodríguez-Montes and colleagues for their interesting paper on splenic lymphangioma.¹ We share the attention they pay in particular to the clinical presentation of this rare disease, and present our experience in this regard.

A 43-year-old female Jehovah's Witness experienced a temporary dull pain in the upper left abdominal quadrant. Abdominal magnetic resonance imaging revealed splenomegaly (12 cm long) with a septated cystic lesion of 6 cm × 4 cm in diameter in the lower pole of the spleen that was displacing the remaining parenchyma. The lesion was hypointense on T1 and hyperintense on T2, consistent with a diagnosis of solitary primary splenic lymphangioma (Fig. 1). In light of her being asymptomatic, her refusal of blood transfusion due to her faith and the insignificant risk of developing malignant tumours, the patient preferred radiological monitoring to surgery.

Solitary primary splenic lymphangioma of the spleen is extremely rare, comprising 0.007% of all the splenic tumours identified.^{1,2} The first description was by Frink in 1885 and only 95 cases have been described since 2015 in the entire world.³ Most of the lesions occur in children; they are asymptomatic and discovered incidentally. If present, splenomegaly can be either painless or painful: the latter is generally associated with fever after increased intralesional pressure caused by internal haemorrhage or infection.² More rare presentations are vague urinary symptoms and respiratory or gastrointestinal problems resulting from displacement of the left kidney, left hemidiaphragm and stomach, respectively.⁴ Since it is pathognomonic, splenic lymphangioma appears hyperintense and hypointense on T2- and T1-weighted magnetic resonance imaging, respectively.⁴ A conservative approach is recommended for small, asymptomatic cases. Historical treatment such as aspiration, drainage and sclerosis have been replaced by splenectomy due

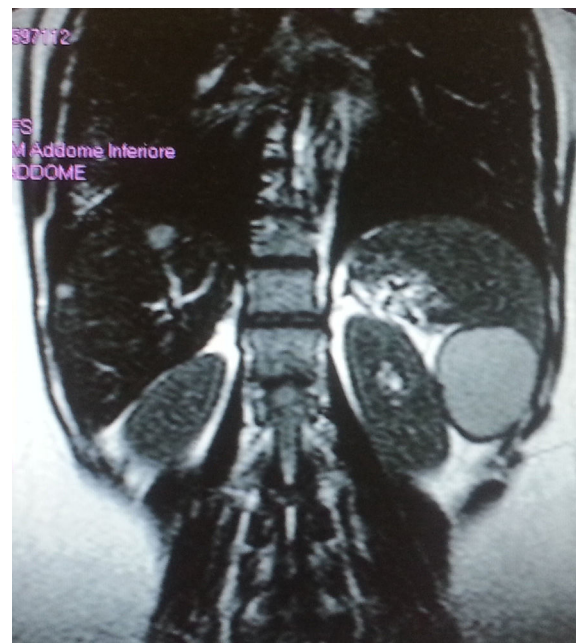


Figure 1 Magnetic resonance imaging of the abdomen (coronal reconstruction) revealed a septated cyst occupying the lower pole of the spleen. The lesion was 6 m × 4 cm in diameter and appeared hyperintense on T2-weighted images, displacing the remaining splenic parenchyma (termed bird-beak sign).

to the high risk of recurrence.^{1–5} At present, laparoscopic splenectomy and partial laparoscopic splenectomy have become the treatment standard for splenic lymphangiomas and large and symptomatic lymphangioma, respectively.⁵

References

- Rodríguez-Montes JA, Collantes-Bellido E, Marín-Serrano E, Prieto-Nieto I, Pérez-Robledo JP. Linfangioma esplénico. Un tumor raro. Presentación de 3 casos y revisión de la bibliografía. *Cir Cir.* 2016;84:154–9.
- Marwah N, Sangwan M, Ralli M, Verma R, Samal S. Cystic lymphangioma of spleen: a case report. *Int J Sci Stud.* 2014;2:40–2.
- Patti R, Iannitto E, Di Vita G. Splenic lymphangiomas showing rapid growth during lactation: a case report. *World J Gastroenterol.* 2010;16:1155–7.

PII of original article: S0009-7411(16)30125-6

[☆] Please cite this article as: Virgilio E, Samra SA, Tallerini A. Linfangioma solitario primario del bazo. *Cir Cir.* 2017;85:562–563.

4. Kwon AH, Inui H, Tsuji K, Takai S, Imamura A, Kamiyama Y. Laparoscopic splenectomy for a lymphangioma of the spleen: report of a case. *Surg Today*. 2001;31:258–61.
5. Wang X, Wang M, Zhang H, Peng B. Laparoscopic partial splenectomy is safe and effective in patients with focal benign splenic lesion. *Surg Endosc*. 2014;28:3273–8.

^b *Servicio de Obstetricia y Ginecología, Hospital San Pedro, Roma, Italy*

*Corresponding author at: Via di Grottarossa 1035-39, Rome, Italy. Tel.: +39 0633775989.

E-mail address: aresedo1992@yahoo.it (E. Virgilio).

Edoardo Virgilio^{a,*}, Sara Abu Samra^b, Anna Tallerini^a

^a *Servicio de Ciencias Médicas y Quirúrgicas y Medicina Traslacional, Facultad de Medicina y Psicología Sapienza, Hospital Sant'Andrea, Roma, Italy*