



REVIEW IN GASTROENTEROLOGY

Role of *Helicobacter pylori* coccoid forms in infection and recrudescence[☆]



Muhannad Sarem^{a,*}, Rodolfo Corti^b

^a Instituto Universitario de Ciencias de la Salud, Facultad de Medicina, Fundación H. A. Barceló, Ciudad Autónoma de Buenos Aires, Argentina

^b Unidad de Esófago y Estómago, Hospital Bonorino Udaondo, Ciudad Autónoma de Buenos Aires, Argentina

Received 1 March 2015; accepted 29 April 2015

Available online 23 December 2015

KEYWORDS

Helicobacter pylori coccoid forms;
Virulence of coccoid forms;
Recrudescence

Abstract *Helicobacter pylori* is a spiral Gram-negative bacillus, which colonizes the human stomach and plays a key role in the pathogenesis of a number of gastroduodenal diseases. However, when exposed to environmental stressed conditions, such as increased oxygen tension, extended incubation and exposure to antibiotics, *H. pylori* is able to enter the viable but nonculturable state, in which the bacterium modifies its morphology from a spiral to coccoid form, as a manifestation of cell adaptation to these adverse conditions. In gastric tissues, viable coccoid forms may remain latent for long time and retain virulence factors, so these forms possibly contribute to the treatment failures and recurrence of *H. pylori* infection and gastroduodenal diseases as well. In this review, we will discuss several aspects of cellular adaptation and survival of *H. pylori*, antibiotic susceptibility and virulence of coccoid forms and its involvement with recrudescence.

© 2015 Elsevier España, S.L.U. and AEEH y AEG. All rights reserved.

PALABRAS CLAVE

Formas cocoides de *Helicobacter pylori*;
Virulencia de las formas cocoides;
Recrudescencia

Rol de las formas cocoides de *Helicobacter pylori* en la infección y la recrudescencia

Resumen *Helicobacter pylori* es un bacilo espiral gramnegativo que coloniza el estómago humano y desempeña un papel clave en la patogénesis de diferentes enfermedades gastroduodenales. Sin embargo, cuando se expone a condiciones de estrés ambientales, tales como el aumento de la tensión de oxígeno, la incubación prolongada o la exposición a antibióticos, *Helicobacter pylori* entra en un estado viable pero no cultivable, en el cual la bacteria

[☆] Please cite this article as: Sarem M, Corti R. Rol de las formas cocoides de *Helicobacter pylori* en la infección y la recrudescencia. Gastroenterol Hepatol. 2016;39:28–35.

* Corresponding author.

E-mail address: msarem@hotmail.com (M. Sarem).

modifica su morfología de una forma bacilar a una cocoide como manifestación de adaptación celular a estas condiciones adversas. En el tejido gástrico, las formas cocoides viables pueden permanecer latentes durante mucho tiempo y retener factores de virulencia, por lo que estas formas posiblemente puedan contribuir a los fracasos del tratamiento y la recurrencia de la infección y de las enfermedades gastroduodenales también. En esta revisión se discutirán varios aspectos de la adaptación celular y supervivencia de *Helicobacter pylori*, la susceptibilidad a los antibióticos y la virulencia de las formas cocoides y su participación en la recrudescencia. © 2015 Elsevier España, S.L.U. and AEEH y AEG. Todos los derechos reservados.

Introduction

Helicobacter pylori (*H. pylori*) is a Gram-negative microaerophilic bacterium, whose natural habitat is the stomach. Although it typically has a bacillary form with several flagella at one end, it adopts a coccoid appearance in unfavourable environmental conditions.^{1,2}

H. pylori is a major aetiological factor in active chronic gastritis, peptic ulcer, gastric mucosa-associated lymphoid tissue (MALT) lymphoma and gastric cancer. Although the bacterium is estimated to be present in the gastric mucosa of half the world's population, these diseases only develop in approximately 15–20% of colonized individuals.^{2,3}

The most common treatment regimens have resulted in an eradication rate of around 85% in many geographical areas,^{4–6} but efficacy has been compromised, especially in recent years, by the rapid emergence of antibiotic-resistant strains and poor treatment adherence.^{5,7}

It is important to consider that the cure (as well as prevention of complications) for active chronic gastritis and peptic ulcer and for some low-grade forms of gastric MALT lymphoma depends on the success of *H. pylori* eradication. Furthermore, ensuring and sustaining successful eradication of this microorganism in all its biological forms would prevent recrudescence of the infection and, therefore, disease relapses.

The aim of this review is to present a general overview of the coccoid form of *H. pylori*, highlighting its microbiological profile, antibiotic susceptibility and virulence. Its involvement in gastric disease will also be analyzed, and the extent to which it is associated with infection recrudescence and disease relapse will be examined.

Survival and cellular adaptation of *H. pylori*

General considerations

All living organisms are equipped with mechanisms that enable them to survive in adverse environments. For some, their response implies (in addition to metabolic adaptations) changes to cell morphology.^{8,9} Several microorganisms have the ability to differentiate into a viable but non-culturable (VBNC) state in response to environmental conditions that are unfavourable to survival and growth. This strategy is

widely used by microorganisms such as *Salmonella*, *Campylobacter* and *Escherichia*.^{10,11}

In the VBNC state, bacteria generally decrease their size and change shape to become small spherical bodies. They reduce their respiration rate and nutrient transport and change gene expression and molecular synthesis. In this state they cannot be detected using conventional culture techniques. However, changes in environmental conditions may lead these microorganisms to either “revive” (and reconvert to their active state) or degenerate.^{10–13}

Similarly, *H. pylori*, when it experiences harmful environmental conditions (in or outside its natural habitat), changes its classic bacillary form and enters a VBNC state that leads to morphological and metabolic changes as well as modifications in growth behaviour.^{14,15}

Viable but non-culturable state of *H. pylori*

Although some authors initially tried to demonstrate that the conversion from bacillary to coccoid form was a passive process that resulted in cell death and, therefore, that the coccoid forms were the degenerated remains of dead bacteria,^{16,17} three forms of *H. pylori* are presently considered to exist, namely (in order of most to least virulent), the viable, culturable bacillary form, the VBNC coccoid form and the non-viable degenerative form.^{18–20}

Morphologically, conversion from the bacillary to the coccoid form occurs through intermediate V- and U-forms^{13,14} (Figs. 1 and 2), in which cell structures like the cytoplasm and cell membrane remain intact,^{15,21} while the flagella tend to wrap around the coccoid cellular structure, thereby becoming near invisible. Other ultrastructural modifications to the coccoid form result in two sub-types. Type A has irregular edges with a rough surface and is considered to be a dead cell, while type B has a smoother surface, is smaller and is considered to be a living cell.^{21,22}

In scanning electron microscope (SEM) analyses of the surface mucous gel layer of gastric cancer patients infected with *H. pylori*, Ogata et al.²³ observed the co-existence of both bacillary and coccoid forms. Other authors have confirmed the presence of the coccoid form in both the human stomach and duodenum,^{24–26} although it seems that the percentage of coccoid forms is higher in the duodenum than in the stomach, to the point where only the coccoid form is

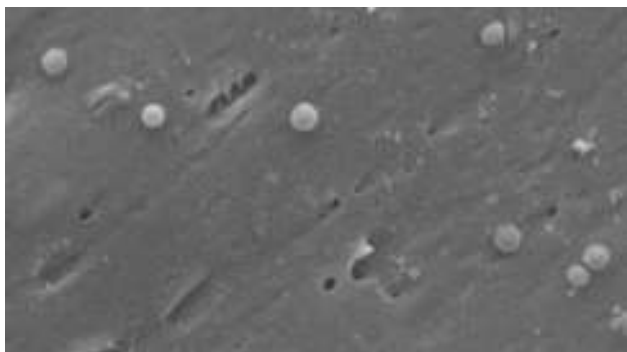


Figure 1 Images of the coccoid form of *Helicobacter pylori*. Scanning electron microscope image courtesy of Dr. Nuno F. Azevedo. LEPABE-Chemical Engineering Department of the Faculty of Engineering at the University of Oporto (Portugal).

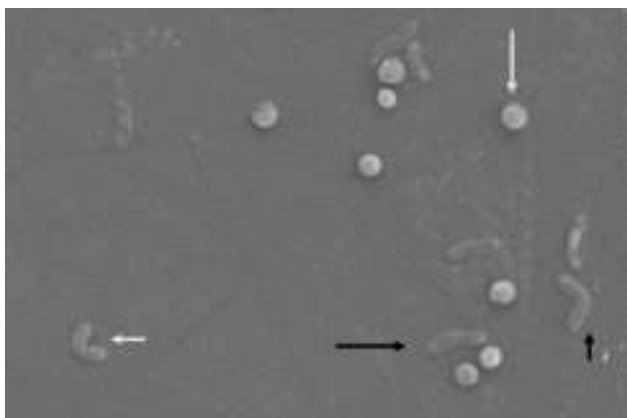


Figure 2 Morphological changes in *Helicobacter pylori*. Spiral form (long black arrow), V-form (short black arrow), U-form (short white arrow) and coccoid form (long white arrow). Scanning electron microscope image courtesy of Dr. Nuno F. Azevedo. LEPABE-Chemical Engineering Department of the Faculty of Engineering at the University of Oporto (Portugal).

observed in some duodenal biopsies.^{26,27} This fact suggests either that *H. pylori* is forced to adapt to biological conditions in the duodenum or that these conditions are ideal for *H. pylori* to take refuge there in the VBNC state.

In vitro and *in vivo* experiments have shown that, in unfavourable conditions like aerobiosis,^{28,29} alkaline pH,^{29,30} high temperature,³¹ lengthy incubation periods,^{29,32} prolonged incubation in water³³ or treatment with proton pump inhibitors³² or antibiotics,³⁴ the coccoid phenotype can maintain a certain level of metabolic activity, as it expresses a wide variety of genes present in the bacillary form,³⁵ maintains detectable levels of urease activity,³⁶ continues synthesizing proteins, albeit in smaller quantities (less than 1% of the quantity of proteins synthesized by the bacillary form)³⁷ and produces small amounts of DNA, maintained even after 3 months storage in physiological saline solution at 4 °C.^{29,38} All these data underline the fact that the biological changes in *H. pylori* in response to harmful stimuli

reflect its powerful ability, during its useful life, to preserve the species.

Biofilm formation

As with other bacteria, the ability of *H. pylori* to persist as an infectious entity and resist the arsenal of antimicrobial agents aimed at eradicating it is due to the genetic variability that enables it to develop bacterial resistance. Its survival strategy is further enhanced when bacterial cells form what are called biofilms.²⁰ Biofilms are a kind of microbial "community" in which the bacteria adhere firmly to biotic or abiotic surfaces by means of a self-produced matrix. This matrix, composed of extracellular polymeric substances,^{39,40} creates an environment that is very tolerant of antimicrobial agents and strongly resistant to phagocytosis. Various host defence mechanisms are therefore evaded, making eradication difficult. Biofilms are considered to be truly complex, dynamic systems that facilitate horizontal gene transfer between bacteria. They thus confer bacterial populations with new modified genomes that contribute significantly to bacterial resistance, strain variability and adaptability.^{41–43}

In a study of 21 biopsies from patients in whom the bacterium had previously been eradicated, *H. pylori* was isolated by culture in 7 of the biopsies, whilst gene expression techniques detected viable *H. pylori* cells in most of the biopsies. SEM, meanwhile, showed clustered coccoid bacteria arranged in a microbial biofilm, suggesting that the coccoid forms could facilitate bacterial persistence and antibiotic resistance.⁴⁴

Susceptibility to antibiotics of the coccoid form

Many studies have shown that *H. pylori* can change from the bacillary to coccoid form on exposure (*in vitro*) to various antimicrobial agents. Different concentrations of amoxicillin, clarithromycin, metronidazole and erythromycin (to mention just a few of the antibiotics available) can induce this morphological transformation.^{34,35,45} The greatest induction effect has been observed with amoxicillin,^{27,34,46} known to be highly effective *in vitro* against *H. pylori*; however, morphological observations of the cultures show that bacillary forms decrease in number in favour of coccoid forms.^{34,46} Faghri et al.,⁴⁷ achieved bactericidal effects for the coccoid forms, at over 60% with metronidazole at twice the minimum inhibitory concentration (MIC), and at 80–90% with clarithromycin at the MIC; however, amoxicillin treatment with MIC and MIC × 2 did not inhibit viable coccoid forms. Similarly, Berry et al.³⁴ observed that while amoxicillin at MIC × 10 eliminated bacillary forms of *H. pylori*, it also induced the formation of coccoid forms. Perkins et al.⁴⁸ observed, in a study of cats infected naturally with *H. pylori*, that 6 weeks after eradication treatment, gastric juices were positive for *H. pylori* in just one cat, yet polymerase chain reaction (PCR) analysis identified *H. pylori* genetic material in all the cats in the study. Even though *H. pylori* was detected in a single cat, the histological lesions were consistent with chronic

gastritis and were marked by the presence of lymphoid follicles.

Bearing in mind these microbiological and basic research data, in a previous study conducted in patients infected with *H. pylori*—where sensitivity of the isolated strains to amoxicillin was previously determined—dual therapy (proton pump inhibitors and amoxicillin) obtained a cure rate for amoxicillin-sensitive strains of only 66%. This outcome demonstrates the presence of important additional independent bacterial resistance factors related to the successful use of this antibiotic.⁴⁹ This is especially so if we consider that it seems impossible that coccoid forms could be sensitive to β -lactam antibiotics, because coccoid forms have different penicillin-binding protein profiles from bacillary forms.⁵⁰ It is therefore likely that not all *H. pylori* organisms are completely eliminated following eradication treatment; rather, some are likely to be converted to coccoid forms and so become resistant to antibacterial drugs. This would explain treatment failure and recrudescence.^{13,34,45}

It is worth highlighting that some very recent studies have demonstrated that free fatty acids, such as linolenic acid and liposomal linolenic acid, have a bactericidal effect on both *H. pylori* forms, regardless of their resistance to antibiotics.^{51,52} These molecules could therefore have a potentially effective antimicrobial effect in treating infection with *H. pylori*, especially in its coccoid form.

Virulence and pathogenicity of the coccoid form

The virulence factors for the bacillary form of *H. pylori* and the mechanisms by which this bacterium is involved in the development of gastrointestinal diseases have been extensively studied.^{1,3,4} However, little is known about the virulence and pathogenicity of the coccoid form. Below we review the most relevant findings on this subject.

Like the bacillary form, the coccoid form expresses major virulence genes, such as *ureA*, *ureB*, *hpaA*, *vacA* and *cagA*, *cagE* and *BabA*.^{35,53,54} This expression, which occurs over a lengthy period, probably plays an important role in chronic severe stomach disorders.

Adherence of *H. pylori* to the gastroduodenal epithelium is known to be an important step in the induction of active chronic inflammation of the mucosal layer. SEM studies have found that the coccoid form of *H. pylori* can present on the plasma membrane surface of the gastric epithelial cells and, like the bacillary form, has the ability to invade these cells.^{15,55} If cell invasion occurs, the coccoid forms are enclosed in double-layer membrane vesicles and the gastric epithelial cells appear swollen and lytic, showing erosion of the mucosal layer.⁵⁶ Given that the coccoid form is less susceptible to antibiotics, it is believed that these latent plasma membrane forms can spread and infect other neighbouring epithelial cells in the absence of an effective concentration of antibiotics.⁵⁷

H. pylori infection is also known to induce a local immune response that fails to eradicate the bacteria, thereby permitting the gastric disease to become chronic. The immune response can be determined by antibody detection using serological methods developed using the bacillary form of

H. pylori.⁵⁸ In fact, the presence of these specific antibodies can be used as an epidemiological indicator of infection and to confirm the success of treatment. There are, however, no serological methods that detect coccoid forms. In order to determine whether coccoid forms had any effect on the immune response in colonized individuals, Figueroa et al.⁵⁹ devised a specific enzyme-linked immunosorbent assay (ELISA) technique to evaluate and compare the immune response to coccoid and bacillary forms against a panel of sera from symptomatic and asymptomatic infected individuals. The coccoid forms of *H. pylori* were shown to induce a humoral immune response similar to that induced by the bacillary forms in infected individuals. In another study conducted in children with epigastric pain, the possible role of the coccoid form in *H. pylori* infection was examined using an ELISA technique and antigens prepared from bacillary and coccoid cell forms. It was found that 13.3% and 55.8% of cells were seropositive for antigens of the bacillary form and the coccoid form, respectively, whereas seropositivity values for asthmatic children were only 7.0% and 26.5%, respectively. This roughly four-fold difference in seropositivity between the coccoid- and bacillary-form antigens in symptomatic and asymptomatic patients could suggest a possible infective role of the coccoid form of *H. pylori*.⁶⁰

Cellini et al.⁶¹ intragastrically inoculated concentrated suspensions of *H. pylori* in coccoid form in a BALB/c mouse model. *H. pylori* was isolated 2 weeks later, histopathological changes occurred 1 month later and all the colonized mice showed a systemic antibody response to *H. pylori*. In other experiments with BALB/c mice, animals inoculated with coccoid forms developed significant pathological changes in the stomach, including erosive lesions and inflammatory cell infiltration of the gastric mucosa.³⁶ She et al.,⁵³ in order to compare virulence and infectivity, intragastrically inoculated BALB/c mice with *H. pylori*, one group with the bacillary form and a second group with the coccoid form. In the SEM examination of samples from the 2 groups, they observed adherence of both bacillary and coccoid forms to the epithelial cells of the gastric wall and the presence of flagella in the coccoid forms. Histological examination showed different grades of lesions in the gastric mucosa, from mild inflammatory cell infiltration to erosions and ulcers. The mucosal lesion was milder in the mice infected by the coccoid form, while a positive result was not obtained in the control group that received sterile water.⁵³ Rabelo-Gonçalves et al.⁶² showed that coccoid forms of *H. pylori* induced an acute inflammatory response in the stomach of mice from the earliest stages of the infection. The above results highlight the ability of coccoid forms to colonize and infect the gastric mucosa *in vivo*.

Several studies have revealed the presence of the coccoid form in water.^{33,63} One such study—by our group—compared 2 groups of weaned Wistar mice, one administered well water and tap water for a prolonged period of time and the other administered sterile distilled water, finding that the study group mice developed a chronic inflammatory process with formation of lymphocytic plaques and the presence of bacilli consistent with *H. pylori*.⁶⁴

As previously mentioned, it would be logical to suppose that, in unfavourable conditions, *H. pylori* enters a

“quiescent” state, modifying its classic bacillary form to the coccoid form without producing degenerative changes in its genome and retaining the ability to revert to the bacillary form once environmental or natural habitat conditions improve.

Participation of the coccoid form in recrudescence

Recurrence of *H. pylori* following successful eradication is rare in developed countries compared to developing countries, with annual recurrence rates of 2.67% and 13%, respectively.^{65,66}

There are two types of recurrence of *H. pylori* infection: recrudescence, when the bacterial strain responsible for the recurrence is genetically identical to that isolated prior to eradication; and re-infection, when recurrence is caused by a different strain.⁶⁷ Differentiating recrudescence from re-infection requires PCR or genetic polymorphism analysis to identify bacterial strains.^{67,68} Since these methods are not routinely applied, it is often impossible to differentiate between recrudescence and re-infection in routine clinical practice.

H. pylori recurrence is clinically relevant, since peptic ulcer relapse can be observed in a considerable proportion of infected patients, whereas the reappearance of microorganisms could explain some MALT lymphoma recurrences following treatment.⁶⁹ Factors such as drinking tap water, dental and gum disease, recurrent tonsillitis, hospitalization, dental and medical equipment and contact with family members are believed to affect *H. pylori* recurrence.^{70–72} Other factors associated with infection recurrence are younger age, diabetes in young patients, low annual income and long-term inhibition of gastric acid following eradication.^{73–76}

Recrudescence is considered the most likely reason for recurrence in the first year following eradication, while re-infection can occur after a longer period.^{68,77} Many cases of recurrence in developed countries are in reality due to recrudescence. Re-infection is more common in developing countries, since people are apparently constantly exposed to *H. pylori*.^{65,78}

Using polyacrylamide gel protein electrophoresis techniques, Costas et al.⁷⁹ found that patients with recurrence 4 weeks after eradication treatment were not in fact infected with another strain of *H. pylori*; rather, the strain that had caused the original infection had not been completely eradicated by the treatment, leading to recrudescence of the infection. Therefore, it is important to take into account the efficacy of the therapeutic regimen: *H. pylori* recurrence is frequent in patients treated with low-efficacy therapies, but is rare when high-efficacy therapies are used. This was demonstrated by a study on the incidence of *H. pylori* recurrence in Spain by Gisbert et al.,⁸⁰ who found that *H. pylori* recurrence 6 months after eradication was 8.2% in patients treated with low-efficacy therapies but only 1.7% in patients treated with high-efficacy therapies.

In a study conducted in Korea from 2007 to 2010, *H. pylori* recurrence rates were analyzed after 6 months of successful first- and second-line eradication therapies, with

annual follow-up—to the end of the study period—based on breath tests, stomach biopsy and rapid urease tests.⁸¹ It was found that the annual recurrence rates within and after the 2-year follow-up were 9.3% and 2.0%, respectively, after the first-line therapy, and 4.5% and 2.9% respectively, after the second-line therapy. The authors concluded that annual *H. pylori* recurrence rates for patients who received eradication treatment showed a sharp drop after the 2-year follow-up period. This was considered sufficient time after treatment to confirm eradication, and also sufficient time to enable a distinction to be made between recurrence and recrudescence of *H. pylori* strains.⁸¹

Final considerations and conclusions

Given the ability of *H. pylori* to enter a VBNC state when subjected to unfavourable conditions within or outside its habitat, it is reasonable to suppose that antibiotic treatment regimens used to eradicate the bacillary form of *H. pylori* may induce VBNC coccoid forms capable of surviving for lengthy periods in the gastroduodenal environment. From here they may have direct and indirect pathogenic potential that leads to recrudescence of the infection and, as a result, treatment failures, infection relapses and recurrence of gastroduodenal disease. Successful eradication may therefore require not only eradication of the bacillary forms but also of the coccoid forms, or ensuring that coccoid forms are not induced.

Bearing in mind that, since routine methods currently implemented in clinical practice to confirm *H. pylori* eradication cannot detect coccoid forms, hosts may be incorrectly diagnosed as free of infection; furthermore, these methods may not be able to provide complete evidence of the clinical potential of the drugs used to eradicate *H. pylori*. Thus, for eradication to be considered successful, annual follow-up is recommended—using non-invasive techniques or, if available, molecular methods—to determine whether bacteria have been completely eliminated, most especially in high-prevalence areas and in patients at risk of recurrence.

Finally, further studies are necessary of the coccoid VBNC form of *H. pylori*, its pathogenic potential, its involvement in infection and recrudescence and its role in forming biofilms in the stomach and other locations within the host. Such studies would enable the development both of more effective diagnostic protocols that avoid underestimating colonization by *H. pylori* and of novel therapeutic strategies aimed at eliminating coccoid forms and “disarming” biofilms.

Conflict of interests

The authors declare that they have no conflict of interests.

Acknowledgements

The authors would like to thank Dr. Nuno F. Azevedo of the Chemical Engineering Department of the Faculty of

Engineering at the University of Oporto (Portugal) for providing the images published in this article.

References

- Kalali B, Mejías-Luque R, Javaheri A, Gerhard M. *H. pylori* virulence factors: influence on immune system and pathology. *Mediators Inflamm.* 2014;2014:426309, <http://dx.doi.org/10.1155/2014/426309>.
- Calvet X. *Helicobacter pylori* eradication treatment in non-ulcerous disease. *Gastroenterol Hepatol.* 2005;28:40–6.
- Höcker M, Hohenberger P. *Helicobacter pylori* virulence factors – one part of a big picture. *Lancet.* 2003;362:1231–3.
- Corti RE. *Helicobacter pylori*: some epidemiological questions in Latin America after twenty-five years. *Acta Gastroenterol Latinoam.* 2009;39:175–6.
- Papastergiou V, Georgopoulos SD, Karatapanis S. Treatment of *Helicobacter pylori* infection: past, present and future. *World J Gastrointest Pathophysiol.* 2014;5:392–9, <http://dx.doi.org/10.4291/wjgp.v5.i4.392>.
- Gisbert JP. *Helicobacter pylori*-related diseases. *Gastroenterol Hepatol.* 2012;35:12–25, [http://dx.doi.org/10.1016/S0210-5705\(12\)70030-4](http://dx.doi.org/10.1016/S0210-5705(12)70030-4).
- Gené E, Sánchez-Delgado J, Calvet X, Azagra R. Management of *Helicobacter pylori* infection in primary care in Spain. *Gastroenterol Hepatol.* 2008;31:327–34.
- Cabrera CE, Gómez RF, Zúñiga AD. La resistencia de bacterias a antibióticos, antisépticos y desinfectantes una manifestación de los mecanismos de supervivencia y adaptación. *Colomb Med.* 2007;38:149–58.
- Ang JY, Ezike E, Asmar BI. Antibacterial resistance. *Indian J Pediatr.* 2004;71:229–39.
- Ozçakir O. Viable but non-culturable form of bacteria. *Mikrobiyol Bul.* 2007;41:477–84.
- Li L, Mendis N, Trigui H, Oliver JD, Faucher SP. The importance of the viable but non-culturable state in human bacterial pathogens. *Front Microbiol.* 2014;5:258, <http://dx.doi.org/10.3389/fmicb.2014.00258>.
- Fakruddin M, Mannan KS, Andrews S. Viable but nonculturable bacteria: food safety and public health perspective. *ISRN Microbiol.* 2013;2013:703813, <http://dx.doi.org/10.1155/2013/703813>.
- Citterio B, Casaroli A, Pierfelici L, Battistelli M, Falcieri E, Baffone W. Morphological changes and outer membrane protein patterns in *Helicobacter pylori* during conversion from bacillary to coccoid form. *N Microbiol.* 2004;27:353–60.
- Azevedo NF, Almeida C, Cerqueira L, Dias S, Keevil CW, Vieira MJ. Coccoid form of *Helicobacter pylori* as a morphological manifestation of cell adaptation to the environment. *Appl Environ Microbiol.* 2007;73:3423–7.
- Bai H, Li Q, Liu X, Li Y. Characteristics and interactions of *Helicobacter pylori* and *H. pylori*-infected human gastroduodenal epithelium in peptic ulcer: a transmission electron microscopy study. *Dig Dis Sci.* 2010;55:82–8, <http://dx.doi.org/10.1007/s10620-008-0697-9>.
- Kusters JG, Gerrits MM, van Strijp JA, Vandenbroucke-Grauls CM. Coccoid forms of *Helicobacter pylori* are the morphological manifestation of cell death. *Infect Immun.* 1997;65:3672–9.
- Nilius M, Ströhle A, Bode G, Malfertheiner P. Coccoid like forms (CLF) of *Helicobacter pylori*. Enzyme activity and antigenicity. *Zentralbl Bakteriol.* 1993;280:259–72.
- Andersen LP, Rasmussen L. *Helicobacter pylori*-coccoid forms and biofilm formation. *FEMS Immunol Med Microbiol.* 2009;56:112–5.
- Percival SL, Suleman L. Biofilms and *Helicobacter pylori*: dissemination and persistence within the environment and host. *World J Gastrointest Pathophysiol.* 2014;5:122–32, <http://dx.doi.org/10.4291/wjgp.v5.i3.122>.
- Cellini L. *Helicobacter pylori*: a chameleon-like approach to life. *World J Gastroenterol.* 2014;20:5575–82, <http://dx.doi.org/10.3748/wjg.v20.i19.5575>.
- Sato F. *Helicobacter pylori* in culture: an ultrastructural study. *Hokkaido Igaku Zasshi.* 2000;75:187–96.
- Sato F, Saito N, Konishi K, Shoji E, Kato M, Takeda H, et al. Ultrastructural observation of *Helicobacter pylori* in glucose-supplemented culture media. *J Med Microbiol.* 2003;52:675–9.
- Ogata M, Araki K, Ogata T. An electron microscopic study of *Helicobacter pylori* in the surface mucous gel layer. *Histol Histopathol.* 1998;13:347–58.
- Goldstein NS. Chronic inactive gastritis and coccoid *Helicobacter pylori* in patients treated for gastroesophageal reflux disease or with *H. pylori* eradication therapy. *Am J Clin Pathol.* 2002;118:719–26.
- Chan WY, Hui PK, Leung KM, Chow J, Kwok F, Ng CS. Coccoid forms of *Helicobacter pylori* in the human stomach. *Am J Clin Pathol.* 1994;102:503–7.
- Noach LA, Rolf TM, Tytgat GN. Electron microscopic study of association between *Helicobacter pylori* and gastric and duodenal mucosa. *J Clin Pathol.* 1994;47:699–704.
- Bode G, Malfertheiner P, Ditschuneit H. Pathogenetic implications of ultrastructural findings in *Campylobacter pylori* related gastroduodenal disease. *Scand J Gastroenterol.* 1988;23:25–39.
- Catrenich CE, Makin KM. Characterization of the morphologic conversion of *Helicobacter pylori* from bacillary to coccoid forms. *Scand J Gastroenterol Suppl.* 1991;181:58–64.
- Tominaga K, Hamasaki N, Watanabe T, Uchida T, Fujiwara Y, Takaishi O, et al. Effect of culture conditions on morphological changes of *Helicobacter pylori*. *J Gastroenterol.* 1999;34:28–31.
- Hua J, Ho B. Is the coccoid form of *Helicobacter pylori* viable? *Microbios.* 1996;87:103–12.
- Mizoguchi H, Fujioka T, Nasu M. Evidence for viability of coccoid forms of *Helicobacter pylori*. *J Gastroenterol.* 1999;34:32–6.
- Cellini L, Allocati N, di Campli E, Dainelli B. *Helicobacter pylori*: a fickle germ. *Microbiol Immunol.* 1994;38:25–30.
- Shahamat M, Mai U, Paszko-Kolva C, Kessel M, Colwell RR. Use of autoradiography to assess viability of *Helicobacter pylori* in water. *Appl Environ Microbiol.* 1993;59:1231–5.
- Berry V, Jennings K, Woodnutt G. Bactericidal and morphological effects of amoxicillin on *Helicobacter pylori*. *Antimicrob Agents Chemother.* 1995;39:1859–61.
- Sisto F, Brenciaglia MI, Scaltrito MM, Dubini F. *Helicobacter pylori*: *ureA*, *cagA* and *vacA* expression during conversion to the coccoid form. *Int J Antimicrob Agents.* 2000;15:277–82.
- Wang X, Sturegård E, Rupar R, Nilsson HO, Aleljung PA, Carlén B, et al. Infection of BALB/c A mice by spiral and coccoid forms of *Helicobacter pylori*. *J Med Microbiol.* 1997;46:657–63.
- Mizoguchi H, Fujioka T, Kishi K, Nishizono A, Kodama R, Nasu M. Diversity in protein synthesis and viability of *Helicobacter pylori* coccoid forms in response to various stimuli. *Infect Immun.* 1998;66:5555–60.
- Benaissa M, Babin P, Quellard N, Pezennec L, Cenatiempo Y, Fauchère JL. Changes in *Helicobacter pylori* ultrastructure and antigens during conversion from the bacillary to the coccoid form. *Infect Immun.* 1996;64:2331–5.
- Donlan RM, Costerton JW. Biofilms: survival mechanisms of clinically relevant microorganisms. *Clin Microbiol Rev.* 2002;15:167–93.
- Lewis K. Riddle of biofilm resistance. *Antimicrob Agents Chemother.* 2001;45:999–1007.
- Saito N, Konishi K, Kato M, Takeda H, Asaka M, Ooi HK. Coccoid formation as a mechanism of species-preservation in *Helicobacter pylori*: an ultrastructural study. *Hokkaido Igaku Zasshi.* 2008;83:291–5.

42. Madsen JS, Burmølle M, Hansen LH, Sørensen SJ. The interconnection between biofilm formation and horizontal gene transfer. *FEMS Immunol Med Microbiol*. 2012;65:183–95.
43. Watnick P, Kolter R. Biofilm, city of microbes. *J Bacteriol*. 2000;182:2675–9.
44. Cellini L, Grande R, di Campli E, Traini T, Giulio MD, Lannutti SN, et al. Dynamic colonization of *Helicobacter pylori* in human gastric mucosa. *Scand J Gastroenterol*. 2008;43:178–85.
45. Roe IH, Son SH, Oh HT, Choi J, Shin JH, Lee JH, et al. Changes in the evolution of the antigenic profiles and morphology during coccoid conversion of *Helicobacter pylori*. *Korean J Intern Med*. 1999;14:9–14.
46. Bode G, Mauch F, Malfertheiner P. The coccoid forms of *Helicobacter pylori*. Criteria for their viability. *Epidemiol Infect*. 1993;111:483–90.
47. Faghri J, Poursina F, Moghim S, Zarkesh Esfahani H, Nasr Esfahani B, Fazeli H, et al. Morphological and bactericidal effects of different antibiotics on *Helicobacter pylori*. *Jundishapur J Microbiol*. 2014;7:e8704, <http://dx.doi.org/10.5812/jjm.8704>.
48. Perkins SE, Yan LL, Shen Z, Hayward A, Murphy JC, Fox JG. Use of PCR and culture to detect *Helicobacter pylori* in naturally infected cats following triple antimicrobial therapy. *Antimicrob Agents Chemother*. 1996;40:1486–90.
49. Dore MP, Piana A, Carta M, Atzei A, Are BM, Mura I, et al. Amoxicillin resistance is one reason for failure of amoxicillin-omeprazole treatment of *Helicobacter pylori* infection. *Aliment Pharmacol Ther*. 1998;12:635–9.
50. DeLoney CR, Schiller NL. Competition of various beta-lactam antibiotics for the major penicillin-binding proteins of *Helicobacter pylori*: antibacterial activity and effects on bacterial morphology. *Antimicrob Agents Chemother*. 1999;43:2702–9.
51. Obonyo M, Zhang L, Thamphiwatana S, Pornpattananangkul D, Fu V, Zhang L. Antibacterial activities of liposomal linolenic acids against antibiotic-resistant *Helicobacter pylori*. *Mol Pharm*. 2012;9:2677–85, <http://dx.doi.org/10.1021/mp300243w>.
52. Desbois AP, Smith VJ. Antibacterial free fatty acids: activities, mechanisms of action and biotechnological potential. *Appl Microbiol Biotechnol*. 2010;85:1629–42.
53. She FF, Su DH, Lin JY, Zhou LY. Virulence and potential pathogenicity of coccoid *Helicobacter pylori* induced by antibiotics. *World J Gastroenterol*. 2001;7:254–8.
54. Wang XF, Wang KX. Cloning and expression of *vacA* gene fragment of *Helicobacter pylori* with coccoid form. *J Chin Med Assoc*. 2004;67:549–56.
55. Amieva MR, Salama NR, Tompkins LS, Falkow S. *Helicobacter pylori* enter and survive within multivesicular vacuoles of epithelial cells. *Cell Microbiol*. 2002;4:677–90.
56. Ozbek A, Ozbek E, Dursun H, Kalkan Y, Demirci T. Can *Helicobacter pylori* invade human gastric mucosa?: an in vivo study using electron microscopy, immunohistochemical methods, and real-time polymerase chain reaction. *J Clin Gastroenterol*. 2010;44:416–22, <http://dx.doi.org/10.1097/MCG.0b013e3181c21c69>.
57. Chu YT, Wang YH, Wu JJ, Lei HY. Invasion and multiplication of *Helicobacter pylori* in gastric epithelial cells and implications for antibiotic resistance. *Infect Immun*. 2010;78:4157–65, <http://dx.doi.org/10.1128/IAI.00524-10>.
58. Suarez G, Reyes VE, Beswick EJ. Immune response to *H. pylori*. *World J Gastroenterol*. 2006;12:5593–8.
59. Figueroa G, Faúndez G, Troncoso M, Navarrete P, Toledo MS. Immunoglobulin G antibody response to infection with coccoid forms of *Helicobacter pylori*. *Clin Diagn Lab Immunol*. 2002;9:1067–71.
60. Ng BL, Quak SH, Aw M, Goh KT, Ho B. Immune responses to differentiated forms of *Helicobacter pylori* in children with epigastric pain. *Clin Diagn Lab Immunol*. 2003;10:866–9.
61. Cellini L, Allocati N, Angelucci D, Iezzi T, di Campli E, Marzio L, et al. Coccoid *Helicobacter pylori* not culturable in vitro reverts in mice. *Microbiol Immunol*. 1994;38:843–50.
62. Rabelo-Gonçalves EM, Nishimura NF, Zeitune JM. Acute inflammatory response in the stomach of BALB/c mice challenged with coccoidal *Helicobacter pylori*. *Mem Inst Oswaldo Cruz*. 2002;97:1201–6.
63. Fan XG, Chua A, Li TG, Zeng QS. Survival of *Helicobacter pylori* in milk and tap water. *J Gastroenterol Hepatol*. 1998;13:1096–8.
64. Sarem M, Macías M, Amendola R, Bori J, Corti R. Transmisión de la bacteria *Helicobacter pylori* a partir del agua. *Acta Gastroenterol Latinoam*. 2011;41:17.
65. Niv Y. *H. pylori* recurrence after successful eradication. *World J Gastroenterol*. 2008;14:1477–8.
66. Parsonnet J. What is the *Helicobacter pylori* global reinfection rate? *Can J Gastroenterol*. 2003;17:46B–8B.
67. Van der Ende A, van der Hulst RW, Dankert J, Tytgat GN. Reinfection versus recrudescence in *Helicobacter pylori* infection. *Aliment Pharmacol Ther*. 1997;11:55–61.
68. Xia HX, Talley NJ, Keane CT, O'Morain CA. Recurrence of *Helicobacter pylori* infection after successful eradication: nature and possible causes. *Dig Dis Sci*. 1997;42:1821–34.
69. Gisbert JP, Luna M, Gómez B, Herrerías JM, Monés J, Castro-Fernández M, et al. Recurrence of *Helicobacter pylori* infection after several eradication therapies: long-term follow-up of 1000 patients. *Aliment Pharmacol Ther*. 2006;23:713–9.
70. Niv Y, Hazazi R. *Helicobacter pylori* recurrence in developed and developing countries: meta-analysis of ¹³C-urea breath test follow-up after eradication. *Helicobacter*. 2008;13:56–61, <http://dx.doi.org/10.1111/j.1523-5378.2008.00571.x>.
71. Sheu BS, Cheng HC, Yang YJ, Yang HB, Wu JJ. The presence of dental disease can be a risk factor for recurrent *Helicobacter pylori* infection after eradication therapy: a 3-year follow-up. *Endoscopy*. 2007;39:942–7.
72. Bouziane A, Ahid S, Abouqal R, Ennibi O. Effect of periodontal therapy on prevention of gastric *Helicobacter pylori* recurrence: a systematic review and meta-analysis. *J Clin Periodontol*. 2012;39:1166–73, <http://dx.doi.org/10.1111/jcpe.12015>.
73. Candelli M, Rigante D, Schiavino A, Gabrielli M, Crea F, Minguell del Lungo L, et al. High reinfection rate of *Helicobacter pylori* in young type 1 diabetic patients: a three-year follow-up study. *Eur Rev Med Pharmacol Sci*. 2012;16:1468–72.
74. Gómez Rodríguez BJ, Rojas Feria M, García Montes MJ, Romero Castro R, Hergueta Delgado P, Pellicer Bautista FJ, et al. Incidence and factors influencing on *Helicobacter pylori* infection recurrence. *Rev Esp Enferm Dig*. 2004;96, 620–623, 424–427.
75. Manes G, Domínguez-Muñoz JE, Uomo G, Labenz J, Hackelsberger A, Malfertheiner P. Increased risk for *Helicobacter pylori* recurrence by continuous acid suppression: a randomized controlled study. *Ital J Gastroenterol Hepatol*. 1998;30:28–33.
76. Moya DA, Crissinger KD. *Helicobacter pylori* persistence in children: distinguishing inadequate treatment, resistant organisms, and reinfection. *Curr Gastroenterol Rep*. 2012;14:236–42, <http://dx.doi.org/10.1007/s11894-012-0251-y>.
77. Gisbert JP. The recurrence of *Helicobacter pylori* infection: incidence and variables influencing it. A critical review. *Am J Gastroenterol*. 2005;100:2083–99.
78. Ramirez-Ramos A, Gilman RH, Leon-Barua R, Recavarren-Arce S, Watanabe J, Salazar G, et al. Rapid recurrence of *Helicobacter pylori* infection in Peruvian patients after successful eradication. *Gastrointestinal Physiology Working Group of the Universidad Peruana Cayetano Heredia and The Johns Hopkins University*. *Clin Infect Dis*. 1997;25:1027–31.
79. Costas M, Owen RJ, Bickley J, Morgan DR. Molecular techniques for studying the epidemiology of infection by *Helicobacter pylori*. *Scand J Gastroenterol*. 1991;26:20–32.

80. Gisbert JP, Pajares JM, García-Valriberas R, Abaira V, Boixeda D, García-Grávalos R, et al. Recurrence of *Helicobacter pylori* infection after eradication: incidence and variables influencing it. *Scand J Gastroenterol.* 1998;33: 1144–51.
81. Kim SY, Hyun JJ, Jung SW, Koo JS, Yim HJ, Lee SW. *Helicobacter pylori* recurrence after first- and second-line eradication therapy in Korea: the problem of recrudescence or reinfection. *Helicobacter.* 2014;19:202–6, <http://dx.doi.org/10.1111/hel.12117>.