

3. Crosignani P, De Stefani A, Fara GM, Isidori AM, Lenzi A, Liverani CA, et al. Towards the eradication of HPV infection through universal specific vaccination. *BMC Public Health*. 2013;11:642.

Lisette Batista, Yamile Zabana\*, Montserrat Aceituno, Maria Esteve

Inflammatory Bowel Disease Unit, Gastroenterology Department, Hospital Universitari Mútua Terrassa, Terrassa, Catalonia, Spain

\* Corresponding author.

E-mail address: [yzabana@gmail.com](mailto:yzabana@gmail.com) (Y. Zabana).

## Fulminant *Clostridium difficile* colitis<sup>☆</sup>



### Colitis fulminante por *Clostridium difficile*

To the Editor,

Fulminant *Clostridium difficile* colitis (FCDC) is characterised by the development of severe acute inflammation of the colon, associated with systemic toxicity. It is a clinical entity with high mortality that requires intensive medical treatment and early surgery in non-responders. The incidence of *C. difficile* infection—as well as its severity and mortality—has increased significantly in recent years.<sup>1</sup> It is a common cause of infectious diarrhoea in hospitalised patients, and the main cause of antibiotic-induced diarrhoea. Symptoms vary from mild diarrhoea to potentially fatal fulminant disease; its diagnosis is based on the detection of toxins in faeces.

We present 2 clinical cases of FCDC. The first case was a 77-year-old man, immunocompromised as a result of chemotherapy and on treatment with metronidazole for *C. difficile* colitis for 12 days, who presented with acute abdominal pain, changes in his general condition, septic state and persistent diarrhoea. He also had haemodynamic instability, elevated blood lactate levels and Quick index of 57%. Abdominal examination was remarkable for diffuse pain with signs of peritoneal irritation. Plain abdominal X-ray revealed pneumoperitoneum and double wall sign (Fig. 1); urgent surgery was indicated, in which a perforated megacolon was found. Subtotal colectomy was performed, with ileostomy and mucous fistula. He was admitted to the intensive care unit for multiple organ dysfunction syndrome (MODS), remaining there for 7 days. He was treated with intravenous metronidazole and oral vancomycin, and made satisfactory progress. Macroscopic analysis of the surgical specimen showed signs of pseudomembranous colitis (Fig. 2). He is currently awaiting intestinal passage reconstruction.

The second patient was a 57-year-old man who had been admitted to the surgery department following a right hemicolectomy for caecal cancer. He was admitted for febrile syndrome, treated with intravenous ertapenem 10 days prior to the intervention. On the first postoperative day,

he passed a melaena stool with no analytical or haemodynamic effects. Hours later he presented a bloody stool with coffee ground vomitus and a drop in blood pressure. Urgent laboratory tests showed a fall in the Quick index and the red and white cell count. Emergency gastroscopy was normal, but following a new episode of massive rectorrhagia, the patient underwent urgent surgery. Intraoperative colonoscopy ruled out bleeding of the anastomosis, but found abundant traces of blood and a greyish mucosa, which detached easily (Fig. 3). Suspecting fulminant pseudomembranous colitis, subtotal colectomy was performed with ileostomy and distal mucous fistula. Faecal samples were taken, where the diagnosis of *C. difficile* was confirmed after detecting toxin A and B by enzyme immunoassay, and the toxin B gene by polymerase chain reaction (PCR). Recovery was favourable and months later the intestinal passage was reconstructed.

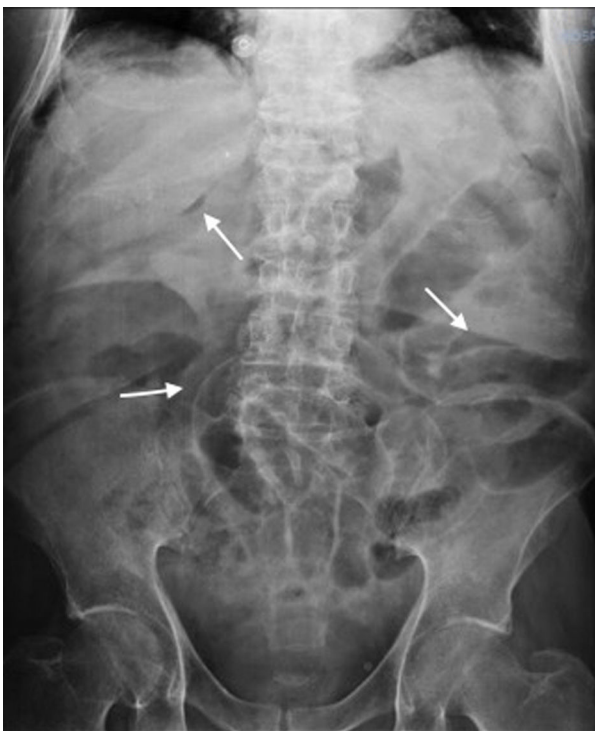In addition to antibiotic treatment, other factors such as advanced age, chronic diseases, hospital stays or treatments with immunosuppressants, antacids and anti-peristaltics have been related with the development of *C. difficile*-associated disease.<sup>2,3</sup> Another factor traditionally associated with this pathology is surgery and/or manipulation of the gastrointestinal tract,<sup>4</sup> although in a recent study, only preoperative stent placement was identified as an independent factor in the multivariate analysis<sup>3</sup>, while the use and duration of oral vs intravenous antibiotics did not affect the incidence of colitis.

Evolution to FCDC develops in between 3% and 8% of infected patients. Although predicting the clinical course of the disease is difficult, factors predisposing to progression to FCDC have been identified, such as age, neoplastic disease, chronic obstructive pulmonary disease, immunosuppression or history of inflammatory bowel disease.<sup>5</sup> Identification of these factors may help select those patients who require intensive follow-up.

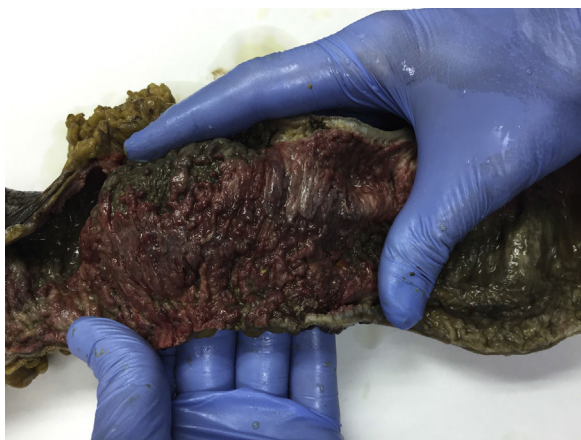
The timing of the surgical intervention is unquestionably a key factor in survival. Although there are clear situations that indicate urgent surgery, the exact moment is not defined and continues to be empirical to a large extent. Some authors<sup>6</sup> have proposed a scoring system to identify patients who would benefit from an early surgical approach, jointly assessing clinical, analytical, radiological and therapeutic criteria.

All studies highlight the importance of surgery before the development of MODS.<sup>1,7</sup> Subtotal colectomy with ileostomy provides the best outcomes.<sup>8</sup> Different studies have suggested increased lactate, decreased serum albumin, age, need for vasopressors or immunosuppression as predictive factors of postoperative mortality.<sup>9</sup> Perera et al.,<sup>10</sup> after

<sup>☆</sup> Please cite this article as: Torrijo Gómez I, Uribe Quintana N, Catalá Llosa J, Raga Vázquez J, Sellés Dechent R, Martín Dieguez MC, et al. Colitis fulminante por *Clostridium difficile*. *Gastroenterol Hepatol*. 2016;39:567–569.



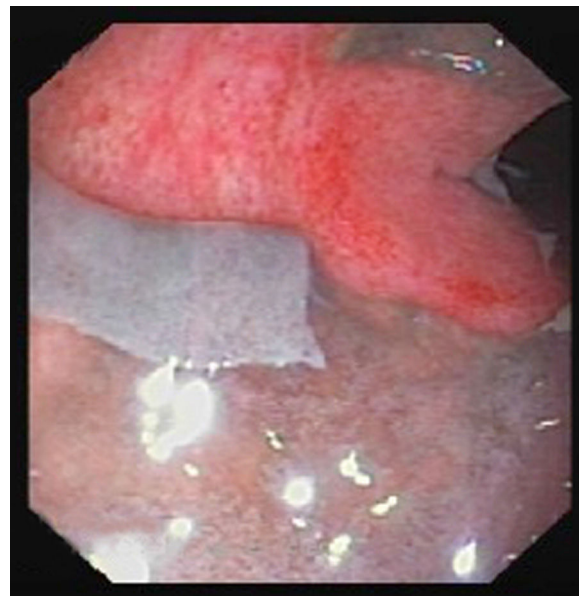
**Figure 1** Plain abdominal X-ray: the double wall sign and pneumoperitoneum can be seen.



**Figure 2** Subtotal colectomy specimen with pseudomembranes.

analysing multiple variables, concluded that only MODS is a predictive factor of mortality.

Our first patient presented predisposing factors to fulminant progression as a result of myeloma treatment. In the second, the symptoms of bleeding in the early postoperative period following colon surgery led us to suspect a surgical complication. It was only after the intraoperative endoscopy that the possibility of pseudomembranous colitis was considered, later confirmed by laboratory tests and biopsies. Pathological review of the surgical specimen from the first intervention did not show any signs of infectious colitis. It should be highlighted that ertapenem has been associated with an increased risk of *C. difficile* infection.<sup>11</sup>



**Figure 3** Sigmoid colon wall, showing detachment of the ischaemic mucosa, revealing a bloody wall.

In conclusion, FCDC is a severe entity that requires high clinical suspicion and intensive therapeutic management. Multidisciplinary assessment is essential to establish the therapeutic measures and choose the best time for surgery.

## References

1. Nogareda F, Soler P, Ll acer A. Increases in *Clostridium difficile* related mortality rates in Spain (1999–2006). *Enferm Infecc Microbiol Clin*. 2009;27:484–5.
2. Karmali S, Laffin M, de Gara C. CAGS Clinical Practice Committee report: the science of *Clostridium difficile* and surgery. *Can J Surg*. 2013;56:367–71.
3. Yeom CH, Cho MM, Baek SK, Bae OS. Risk factors for the development of *Clostridium difficile*-associated Colitis after Colorectal Cancer Surgery. *J Korean Soc Coloproctol*. 2010;26:329–33.
4. Kent KC, Rubin MS, Wroblewski L, Hanff PA, Silen W. The impact of *Clostridium difficile* on a surgical service: a prospective study of 374 patients. *Ann Surg*. 1998;227:296–301.
5. Greenstein AJ, Byrn JC, Zhang LP, Swedish KA, Jahn AE, Divino CM. Risk factors for the development of fulminant *Clostridium difficile* colitis. *Surgery*. 2008;143:623–9.
6. Van der Wilden GM, Chang Y, Cropano C, Subramanian M, Schipper IB, Yeh DD, et al. Fulminant *Clostridium difficile* colitis: prospective development of a risk scoring system. *J Trauma Acute Care Surg*. 2014;76:424–30.
7. Wang MF, Ding Z, Zhao J, Jiang CQ, Liu ZS, Qian Q. Current role of surgery for the treatment of fulminant *Clostridium difficile* colitis. *Chin Med J*. 2013;126:949–56.
8. Koss K, Clark MA, Sanders DS, Morton D, Keighley MR, Goh J. The outcome of surgery in fulminant *Clostridium difficile* colitis. *Colorectal Dis*. 2006;8:149–54.
9. Lamontagne F, Labb e AC, Haeck O. Impact of emergency colectomy on survival of patients with fulminant *Clostridium difficile* colitis during an epidemic caused by a hypervirulent strain. *Ann Surg*. 2007;245:267–72.
10. Perera AD, Akbari RP, Cowher MS, Read TE, McCormick JT, Medich DS, et al. Colectomy for fulminant *Clostridium difficile* colitis: predictors of mortality. *Am Surg*. 2010;76:418–42.
11. Lee S, Prasad P, Lin M, Garritson S, Nichols S, Liu C. Ertapenem prophylaxis associated with an increased risk of *Clostridium*

*difficile* infection among surgical patients. *Infect Control Hosp Epidemiol.* 2015;36135:1–4.

Inmaculada Torrijo Gómez<sup>a,\*</sup>, Natalia Uribe Quintana<sup>a</sup>,  
Jesús Catalá Llosa<sup>a</sup>, Juan Raga Vázquez<sup>a</sup>,  
Rafael Sellés Dechent<sup>a</sup>, M. Carmen Martín Dieguez<sup>a</sup>,  
Gloria Báguena Requena<sup>b</sup>, Francisco Asencio Arana<sup>a</sup>

<sup>a</sup> *Servicio de Cirugía General, Hospital Arnaude Vilanova, Valencia, Spain*  
<sup>b</sup> *Servicio de Cirugía General, Hospital La Fe, Valencia, Spain*

\* Corresponding author.

E-mail address: [inmatg89@hotmail.com](mailto:inmatg89@hotmail.com) (I. Torrijo Gómez).