

with macroscopic bleeding, anaemia or even dysphagia.<sup>5</sup> Capsule endoscopy may be very helpful in its diagnosis, although its final diagnosis is histological; this lesion consists of a proliferation of capillaries with stromal oedema and mixed inflammatory infiltrate.<sup>7</sup> Although endoscopic polypectomy, embolisation and treatment with a laser have been reported, surgical treatment may be required,<sup>8,9</sup> as bleeding is often repeated and profuse, and surgery prevents recurrences.

## Funding

This article does not have any funding.

## Conflicts of interest

The authors declare that they have no conflicts of interest.

## References

- Mills SE, Cooper PH, Fechner RE. Lobular capillary hemangioma: the underlying lesion of pyogenic granuloma. A study of 73 cases from the oral and nasal mucous membranes. *Am J Surg Pathol.* 1980;4:470.
- Giblin AV, Clover AJ, Athanassopoulos A, Budny PG. Pyogenic granuloma – the quest for optimum treatment: audit of treatment of 408 cases. *J Plast Reconstr Aesthet Surg.* 2007;60:1030.
- Harris MN, Desai R, Chuang TY, Hood AF, Mirowski GW. Lobular capillary hemangiomas: an epidemiologic report, with emphasis on cutaneous lesions. *J Am Acad Dermatol.* 2000;42:1012.
- Moffatt DC, Warwryko P, Singh H. Pyogenic granuloma: an unusual cause of massive gastrointestinal bleeding from the small bowel. *Can J Gastroenterol.* 2009;23:261.
- Pennazio M, Spada C, Eliakim R, Keuchel M, May A, Mulder CJ, et al. Small-bowel capsule endoscopy and device-assisted enteroscopy for diagnosis and treatment of smallbowel disorders: European Society of Gastrointestinal Endoscopy (ESGE) Clinical Guideline; 2015.
- Pons Beltrán V. Obscure gastrointestinal bleeding and obscure capsule. May we switch on any lights? *Rev Esp Enferm Dig.* 2015;107:711–3.
- Kuzu I, Bicknell R, Harris AL, Jones M, Gatter KC, Mason DY. Heterogeneity of vascular endothelial cells with relevance to diagnosis of vascular tumours. *J Clin Pathol.* 1992;45:143.
- Kusakabe A, Kato H, Hayashi K, Igami T, Hasegawa H, Tsuzuki T. Pyogenic granuloma of the stomach successfully treated by endoscopic resection after transarterial embolization of the feeding artery. *J Gastroenterol.* 2005;40:530–5.
- Hirakawa K, Aoyagi K, Yao T, Hizawa K, Kido H, Fujishima M. A case of pyogenic granuloma in the duodenum: successful treatment by endoscopic snare polypectomy. *Gastrointest Endosc.* 1998;47:538–40.

Marta Magaz Martínez\*, José Luis Martínez Porras, César Barrios, Luis Abreu

*Hospital Universitario Puerta de Hierro-Majadahonda, Majadahonda, Madrid, Spain*

\* Corresponding author.

E-mail address: [martamagazm@gmail.com](mailto:martamagazm@gmail.com)

(M. Magaz Martínez).

2444-3824/

© 2016 Elsevier España, S.L.U., AEEH and AEG. All rights reserved.

## First case report of oesophageal actinomycosis in a patient with active eosinophilic oesophagitis<sup>☆</sup>



### Primer caso clínico de actinomycosis esofágica en un paciente con esofagitis eosinofílica activa

Actinomycetes are Gram-positive, anaerobic bacteria that are part of the usual flora of the gastrointestinal tract, bronchial tree and female genital tract. Despite this, they sometimes act as pathogens. Chronic cervicofacial suppurative infections are common. Disruption of the mucosal barrier may promote penetration of the micro-organism into any organ in the body.<sup>1,2</sup> Oesophageal involvement is rare and usually occurs in immunodepressed patients,

although it has also been reported in people with no known immunological abnormalities.<sup>3</sup> Other predisposing conditions such as alcoholism, malnutrition, diabetes mellitus and chronic pulmonary disease are found in other cases.<sup>4</sup>

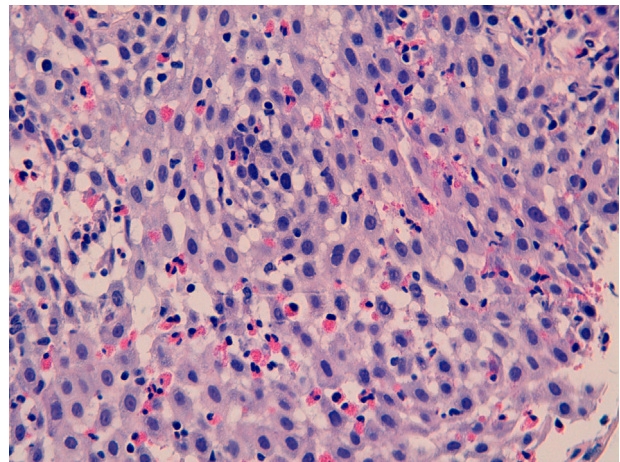
We report the case of a 30-year-old patient assessed due to dysphagia to solids. His history was limited to allergic asthma and hyperuricaemia. He was also an active smoker. In prior years, he had received inhaled budesonide 200–400 µg/day for periods of up to 2 consecutive years. This treatment had been discontinued more than 3 years ago. Currently, he only used inhaled terbutaline as needed. He worked in ventilation duct maintenance. His physical examination showed no abnormalities. His laboratory tests did not show any significant abnormalities either. A gastroscopy was performed and revealed thin longitudinal striations, as well as faint rings in the distal third. All this was suggestive of eosinophilic oesophagitis. He also had a small sliding hiatal hernia. Biopsy findings were consistent with eosinophilic oesophagitis (>20 eosinophils per high-power field [Eo/HPF]) in addition to surface colonies of *Actinomyces* (Figs. 1 and 2). He was treated with doxycycline 100 mg/12 h for 4 weeks. Immunodeficiencies associated with normal immunoglobulins, complete blood count, antinuclear antibodies, anti-neutrophil cytoplasmic antibodies and C3/C4 were ruled out. HIV serology was negative.

<sup>☆</sup> Please cite this article as: Rodríguez-Lago I, Calderón Á, Cazaillas J, Camino ME, Barredo I, Cabriada JL. Primer caso clínico de actinomycosis esofágica en un paciente con esofagitis eosinofílica activa. *Gastroenterol Hepatol.* 2017;40:404–406.

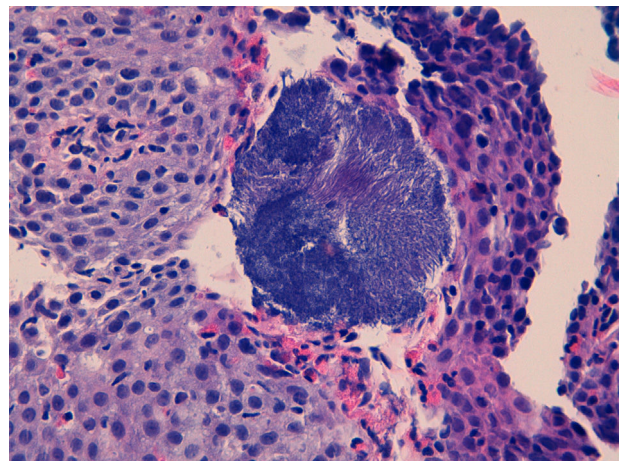
Following antibiotic treatment, his signs and symptoms of dysphagia clearly improved, although they did not entirely resolve. In a gastroscopy performed 5 months later, endoscopic signs of eosinophilic oesophagitis persisted with concentric rings and whitish exudate. The biopsy confirmed their presence (>20 Eo/HPF) and showed no colonies of *Actinomyces*. An allergy study revealed only positivity for aeroallergens (mites, grasses, *Plantago* and cats). It did not detect any food allergies. The patient was treated with omeprazole 20 mg/12 h for 8 weeks, and a solution of swallowed fluticasone 400 µg/12 h for one month, which was decreased to 400 µg per day for another month. When he failed to respond, he was switched to inhaled fluticasone 500 µg/12 h for 8 weeks. Histological remission was not confirmed following treatment. Despite clinical improvement with treatment, he had isolated, self-limiting episodes of dysphagia. Consequently, another endoscopic examination was performed a year later. That examination revealed endoscopic signs of eosinophilic oesophagitis (whitish exudate and longitudinal striae). The increased eosinophils (>15 Eo/HPF), characteristic of this disorder, persisted on biopsy. When he did not improve, despite treatment with proton pump inhibitors and topical corticosteroids, he started an empirical elimination diet.

We report the first case of oesophageal actinomycosis associated with eosinophilic oesophagitis. Other infections such as candidiasis, mainly following treatment with corticosteroids, and herpes simplex virus infection have been reported in these patients.<sup>5,6</sup> Oesophageal actinomycosis is a rare disorder, but should be considered in the differential diagnosis of cases of infectious oesophagitis. *A. israelii* is the most common type of infectious oesophagitis in humans, although there are other species (*A. naeslundii*, *A. viscosus*, *A. odontolyticus* and *A. bovis*).<sup>1,2,4</sup> In general, they have a low pathogenic potential, although any mucosal disruption contributes to the development of the infection.<sup>1,2</sup> It is commonly found in immunosuppressed patients and patients with neoplastic processes, and rare in immunocompetent patients.<sup>3,7</sup> Certain diseases may predispose immunocompetent patients to its development. It has even been postulated that a hiatal hernia may play a role in its pathogenesis.<sup>3</sup> The most common signs and symptoms are dysphagia and odynophagia. Progressive deep tissue involvement may be seen on X-ray.<sup>8</sup> Imaging studies usually show non-specific findings, although they contribute to detecting associated complications, such as fistulas.<sup>8</sup> Diagnosis consists of demonstrating the micro-organism on biopsy or culture. The histology study usually also reveals typical sulphur granules. The culture has low sensitivity and requires a long incubation time in enriched media. The usual empirical treatment consists of penicillin G for a prolonged period. It is also possible to use tetracyclines, erythromycin or clindamycin.

Oesophageal actinomycosis in a patient with eosinophilic oesophagitis had not been reported previously. Not only did it occur in an immunocompetent patient, but also there were no macroscopic mucosal disruptions promoting infection with *Actinomyces*. However, in active eosinophilic oesophagitis, it is known that there is an abnormality in the epithelial barrier, as well as inflammatory proliferation.<sup>9,10</sup> Moreover, the immune and oesophageal motor disorders associated with this disorder may have contributed to



**Figure 1** Oesophageal mucosa with squamous epithelium with eosinophilic infiltrate (>20 eosinophils per high-power field).



**Figure 2** Oesophageal epithelium with eosinophilic infiltrate and surface colonies of *Actinomyces*.

superinfection with this micro-organism. Prolonged treatment with corticosteroids may also have altered the oral microbiota and contributed to the proliferation of *Actinomyces*. However, it is not known whether eosinophilic oesophagitis *per se* predisposes the patient to a higher risk of local infections. As this is the first report of this association between eosinophilic oesophagitis and oesophageal actinomycosis, clinicians should watch for the onset of new cases to accurately delimit risk factors, whether inherent to the disease or to its treatment with corticosteroids, that may predispose patients to local infection with *Actinomyces*.

## References

1. Burden P. Actinomycosis. *J Infect.* 1989;19:95–9.
2. Wong VK, Turmezei TD, Weston VC. Actinomycosis. *BMJ.* 2011;343:d6099.
3. Korkmaz H, Kutluana U, Bugdaci MS, Kucukosmanoglu I. A rare presentation of esophageal actinomycosis in an immunocompetent patient. *Endoscopy.* 2013;45 Suppl. 2:E181–2.

4. Valour F, Sénéchal A, Dupieux C, Karsenty J, Lustig S, Breton P, et al. Actinomycosis: etiology, clinical features, diagnosis, treatment, and management. *Infect Drug Resist.* 2014;7:183–97.
5. Liacouras CA, Furuta GT, Hirano I, Atkins D, Attwood SE, Bonis PA. Eosinophilic esophagitis: updated consensus recommendations for children and adults. *J Allergy Clin Immunol.* 2011;128:2–3.
6. Machicado JD, Younes M, Wolf DS. An unusual cause of odynophagia in a patient with eosinophilic esophagitis. *Gastroenterology.* 2014;147:37–8.
7. Kim HS, Cheon JW, Kim MS, Jung CK, Kim KR, Choi JW, et al. A case of esophageal actinomycosis in a patient with normal immunity. *Korean J Gastroenterol.* 2013;61:93–6.
8. Welling RD, Cardona DM, Thompson WM. Esophageal actinomycosis: a case report and review of radiographic findings. *J Radiol Case Rep.* 2009;3:44–8.
9. Katzka DA, Ravi K, Geno DM, Smyrk TC, Iyer PG, Alexander JA, et al. Endoscopic mucosal impedance measurements correlate with eosinophilia and dilation of intercellular spaces in patients with eosinophilic esophagitis. *Clin Gastroenterol Hepatol.* 2015;13, 1242–8.e1.
10. Simon D, Radonjic-Hösl S, Straumann A, Yousefi S, Simon HU. Active eosinophilic esophagitis is characterized by epithelial

barrier defects and eosinophil extracellular trap formation. *Allergy.* 2015;70:443–52.

Iago Rodríguez-Lago<sup>a,\*</sup>, Ángel Calderón<sup>b</sup>, Juan Cazallas<sup>c</sup>, María Eulalia Camino<sup>d</sup>, Inmaculada Barredo<sup>e</sup>, José Luis Cabriada<sup>a</sup>

<sup>a</sup> Servicio de Digestivo, Hospital de Galdakao, Usansolo, Vizcaya, Spain

<sup>b</sup> Servicio de Digestivo, Hospital Universitario de Basurto, Bilbao, Vizcaya, Spain

<sup>c</sup> Servicio de Enfermedades Infecciosas, Hospital de Galdakao, Usansolo, Vizcaya, Spain

<sup>d</sup> Servicio de Alergología, Hospital de Galdakao, Usansolo, Vizcaya, Spain

<sup>e</sup> Servicio de Anatomía Patológica, Hospital de Galdakao, Usansolo, Vizcaya, Spain

\* Corresponding author.

E-mail address: [iago.r.lago@gmail.com](mailto:iago.r.lago@gmail.com) (I. Rodríguez-Lago). 2444-3824/

© 2016 Elsevier España, S.L.U., AEEH and AEG. All rights reserved.

## Colitis cystica profunda: A report of 2 cases with a 15-year follow-up



### Colitis quística profunda: informe de 2 casos con 15 años de seguimiento

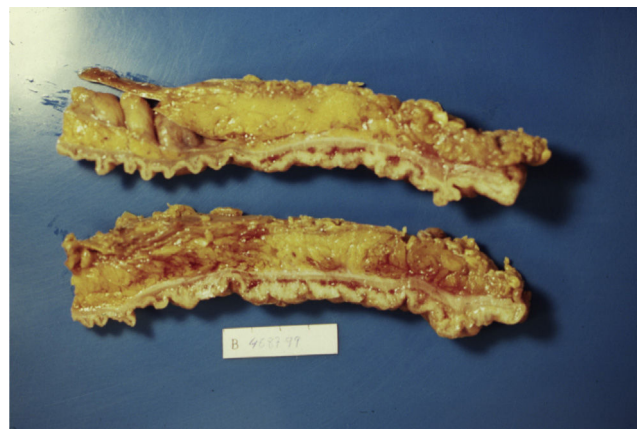
Colitis cystica profunda is a rare benign condition characterized by mucoid cysts in the colonic submucosal layer. The most frequent form is localized, typically located on the anterior rectal wall 6–7 cm from the anal verge, although segmental and diffuse forms affecting only one part of the colon or the whole colon have been documented. The disease usually presents as a polypoid mass in the rectum associated with bloody or mucoid diarrhea and rectal tenesmus. This clinical presentation associated with the microscopic finding of mucus cysts in the submucosa has led to the mistaken diagnosis of adenocarcinoma and unnecessarily radical operative procedures. Attention to the completely normal cellular architecture provides the key to the correct diagnosis.

We here report two cases of colitis cystica profunda in one of which the initial misdiagnosis of rectosigmoid neoplasm caused unnecessary anterior resection of the rectum. In the other case, treatment with systemic and topical corticosteroids was necessary to control rectal bleeding. Both patients have remained asymptomatic for 7 and 10 years, respectively, after successful response to treatment with mesalamine and corticosteroid therapy.

#### Case 1

A 45-year-old man with family history of ulcerative colitis (one brother) was admitted in 1999 because of

post-defecation rectal bleeding, rectal tenesmus and mucus discharge of one month's duration. He was a current smoker (30 pack-years) and reported daily alcohol consumption of 40 g of ethanol. A firm rectal mass was palpated about 6 cm from the anal verge. Barium enema showed a large infiltrating stenotic lesion with an extraluminal mass compatible with rectosigmoid neoplasm. A colonoscopy was performed revealing a 15-cm lobulated and ulcerated mass at 7 cm from the anal verge suggestive of malignant neoplasm affecting the rectosigmoid area. Biopsies showed inflammatory changes without tumor infiltration. The abdominal computerized tomography (CT) showed rectosigmoid wall thickening of malignant appearance without lymph nodes or distant metastasis. A tentative diagnosis of rectal neoplasm was established and the patient underwent a low anterior resection and prophylactic appendectomy. Histopathological examination of the resected specimen (Figs. 1 and 2)



**Figure 1** The resected rectosigmoid segment revealed lobulated and polypoid lesions involving full of the circumference.