

Endoscopic resection of large gastrointestinal lipomas: Loop-and-let-go technique with some twists



Resección endoscópica de lipomas gastrointestinales de gran tamaño: técnica de ligadura endoscópica "loop-and-let go" con algunas peculiaridades

Lipomas are benign subepithelial tumors occurring throughout the gastrointestinal tract, most commonly in the colon and rarely in the duodenum.¹⁻⁴ The majority are asymptomatic and found incidentally.^{3,4} Nevertheless, lipomas may cause symptoms as abdominal pain, change in bowel habits or bleeding.²⁻⁴ This case series, of which 2 cases were previously published as single case reports,^{5,6} aims to describe endoscopic resection of large gastrointestinal lipomas (Table 1). In all cases, endoloop (MAJ-254, Olympus) ligation was performed and, in all but one, complemented with unroofing of the lesion to allow a sample for histological analysis. Slightly different technical aspects detailed in each case were adopted to adjust to the characteristics of the lesion.

A 46-year-old man was referred for endoscopic resection of a large lipoma diagnosed incidentally in a computed tomography (CT). Although asymptomatic, the patient asked for resection regarding the dimension of the lesion. Upper endoscopy revealed a pseudopedunculated lesion measuring 20 mm, in the duodenum. With a double-channel endoscope, an endoloop was previously placed externally to a foreign body forceps which grasp and retract the lesion, while the endoloop was subsequently tightened around the base of the lesion. A second endoloop was positioned using the "loop-over-loop" technique, in which the first endoloop was mobilized with a foreign body forceps guiding the placement of the second endoloop in the base of the lesion, immediately beneath the first endoloop. After endoscopic ligation, a snare was used to unroof the top of the lesion. A follow-up endoscopy performed one month later revealed a regular scar with no residual lesion.

A 72-year-old man was referred to our department with a chronic history of episodic abdominal pain and vomiting. A CT enterography was performed and revealed a large pedunculated lesion resembling a lipoma in the distal ileum. The patient underwent retrograde single-balloon enteroscopy⁶ that revealed a yellowish pedunculated subepithelial lesion covered with normal mucosa in the distal ileum, which was ligated with an endoloop around the false pedicle of the lesion. The patient underwent a follow-up enteroscopy one month later, which revealed complete resection of the lesion. After a year of follow-up the patient remained asymptomatic.

A 51-year-old woman presented with a 6-month history of episodic abdominal pain and chronic diarrhea, which was presumed to be caused by the ball-valve effect of a large lipoma in the terminal ileum. As the manipulation of the lipoma resulted in consecutive retractions to the terminal ileum, a grasp-to-retract technique was employed using a 2-channel therapeutic colonoscope.⁷ While a forceps pulled

and stabilized the lipoma at the ascending colon, a detachable snare, previously positioned over the forceps, was placed around the base of the pseudopedunculated lesion. The endoloop ligation was complemented with unroofing of the lesion. Two months after resection, the patient was asymptomatic and a regular scar was confirmed.

A 67-year-old woman underwent an endoscopic resection of a large asymptomatic lipoma of 30 mm at the ileocecal valve (Video 1), due to the dimensions of the lesion and patient's informed request. With a 2-channel therapeutic colonoscope, the lesion was stabilized with a foreign body forceps while an endoloop was applied and tightened around its base. Subsequently, a second endoloop was positioned using the "loop-over-loop" technique. Finally, unroofing through resection of the top of the lesion with a snare was performed. A follow-up endoscopy performed one month later revealed a regular scar with no residual lesion.

A 57-year-old man underwent endoscopic resection of a pseudopedunculated subepithelial lesion of 25 mm at the sigmoid colon, regarding the dimensions of the lesion and preference of the patient to remove the lesion. With a double-channel colonoscope, a detachable snare was a tightly applied around the base of the lesion (Fig. 1) and another endoloop was further placed around the base of lesion using the "loop-over-loop" technique. Finally, unroofing was performed. Endoscopic follow-up assessment performed a month after the resection, revealed a regular scar with no residual lesion.

The main reasons described in previous case series for resection of gastrointestinal lipomas include symptomatic lesions or asymptomatic lesions larger than 20 mm which may develop symptoms or complications, namely intestinal obstruction, invagination, perforation or bleeding.^{4,7} Nevertheless, larger asymptomatic lesions may be removed after discussion of the risks and benefits with the patient.

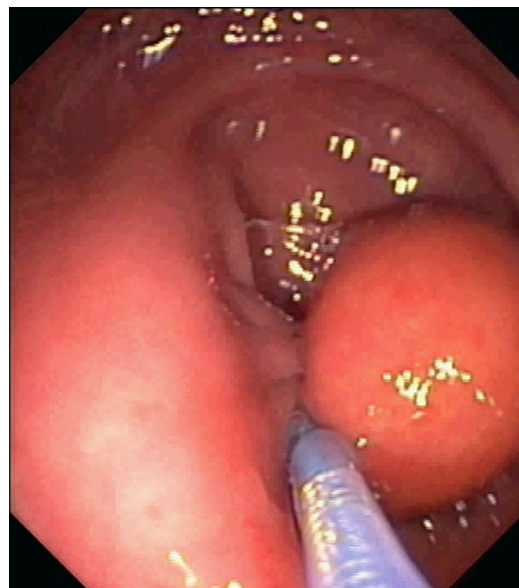


Figure 1 Endoscopic image showing the placement of the first endoloop at the pseudopedunculated base of the lipoma.

Table 1 Summary of the characteristics of the patients, lesions and techniques performed.

Patient No.	Gender	Age	Location	Size (mm)	Equipment	No. endoloops	Unroofing	Complete resection
1	Male	46	2nd part of duodenum	20	2-Channel endoscope (GIF-2T160, Olympus)	2	Yes	Yes
2	Male	72	Distal ileum	20	Balloon-assisted enteroscope (SIF-Q180, Olympus)	1	No	Yes
3	Female	51	Terminal ileum	30	2-Channel colonoscope (CF-2T160L, Olympus)	1	Yes	Yes
4	Female	67	Ileocecal valve	30	2-Channel colonoscope (CF-2T160L, Olympus)	2	Yes	Yes
5	Male	57	Sigmoid colon	25	2-Channel colonoscope (CF-2T160I, Olympus)	2	Yes	Yes

Endoscopic resection of lipomas using cautery snare polypectomy is associated with a high risk of bleeding and perforation, as fat tissue conducts electrosurgical current less efficiently and higher amounts of energy are necessary to resect lesions.^{2,4,7} Conversely, endoloop ligation has a neglectable risk of perforation by promoting slow mechanical transection of large pseudopedunculated lipomas.^{2,4-6,8,9} Moreover, careful selection of the lesions is crucial to ensure a safe resection, as endoscopic ligation should not be performed on broad based or sessile lipomas.⁷ In our series, all the lipomas were pseudopedunculated and no complications were recorded.

The main drawbacks of endoloop ligation are the difficulty in catching the lipoma with the detachable snare, the potential need of further procedures to remove the lesion and lack of a specimen for histological diagnosis. These difficulties may be obviated using a grasping forceps to place the lipoma deep inside the endoloop, using two endoloops to reinforce the ligation and performing the unroofing technique, respectively.^{2-4,8,10} All patients were successfully treated with only one endoscopic session. Moreover, despite the impossibility of confirm complete resection of the lesion, unroofing allowed partial histological evaluation of the specimen corroborating the endoscopic diagnosis.

Conflict of interests

Authors declare no conflict of Interests for this article.

Appendix A. Supplementary data

Supplementary data associated with this article can be found, in the online version, at [doi:10.1016/j.gastrohep.2016.06.001](https://doi.org/10.1016/j.gastrohep.2016.06.001).

References

- Kim CY, Bandres D, Tio TL, Benjamin SB, Al-Kawas FH. Endoscopic removal of large colonic lipomas. *Gastrointest Endosc.* 2002;55:929–31.
- Raju GS, Gomez G. Endoloop ligation of a large colonic lipoma: a novel technique. *Gastrointest Endosc.* 2005;62:988–90.
- Dultz LA, Ullery BW, Sun HH, Huston TL, Eachempati SR, Barie PS, et al. Ileocecal valve lipoma with refractory hemorrhage. *JLS.* 2009;13:80–3.
- Huang WH, Peng CY, Yu CJ, Chou JW, Feng CL. Endoloop-assisted unroofing for the treatment of symptomatic duodenal lipomas. *Gastrointest Endosc.* 2008;68:1234–6.
- Veloso R, Pinho R, Rodrigues A, Pais T, Fernandes C, Carvalho J, et al. Endoloop ligation (loop-and-let-go) of a large ileal lipoma by balloon-assisted enteroscopy. *Endoscopy.* 2012;44 Suppl. 2. UCTN:E176.
- Ponte A, Pinho R, Vale S, Fernandes C, Ribeiro I, Silva J, et al. Resection of a large ileal lipoma exhibiting ball-valve prolapse into the cecum with a grasp-to-retract, ligate, unroof and let-go technique. *Endoscopy.* 2015;47 Suppl. 1: E215–6.
- Ivekovic H, Rustemovic N, Brkic T, Ostojic R, Monkemuller K. Endoscopic ligation (loop-and-let-go) is effective treatment for large colonic lipomas: a prospective validation study. *BMC Gastroenterol.* 2014;14:122.
- Binmoeller KF, Shah JN, Bhat YM, Kane SD. Retract-ligate-unroof-biopsy: a novel approach to the diagnosis and therapy of large nonpedunculated stromal tumors (with video). *Gastrointest Endosc.* 2013;77:803–8.
- Pinho R, Oliveira M, Mascarenhas-Saraiva M. Endoscopic full-thickness resection of an inverted colonic diverticulum with intraepithelial neoplasia using the ligate-and-let-go technique. *Clin Gastroenterol Hepatol.* 2015;13:A33–4.
- Pinho R, Silva J, Ponte A, Rodrigues J, Ribeiro I, Lucas MC, et al. Grasp-to-retract modification of the tulip-bundle technique in forward and retroflexed position for difficult hemostatic therapy in the sigmoid colon. *Endoscopy.* 2015;47 Suppl. 1:E554–5.

Ana Ponte^{a,*}, Rolando Pinho^a, Adélia Rodrigues^a,
Sílvia Vale^b, Cassilda Cidade^b, Joana Silva^a,
Jaime Rodrigues^a, Mafalda Sousa^a, João Carvalho^a

^a Department of Gastroenterology, Centro Hospitalar Vila Nova de Gaia, Espinho, Portugal

^b Department of General Surgery, Centro Hospitalar Vila Nova de Gaia, Espinho, Portugal

*Corresponding author.

E-mail address: ana.ilponte@gmail.com (A. Ponte).

0210-5705/

© 2016 Elsevier España, S.L.U., AEEH y AEG. All rights reserved.

Mastocytic enterocolitis: Increase of mast cells in the gastrointestinal tract of patients with chronic diarrhea



Enterocolitis mastocítica: aumento de los mastocitos en el tracto gastrointestinal de pacientes con diarrea crónica

Two subpopulations of mast cells (MC) are found in the gut: the mucosal reactive MC (T lymphocytes dependent) and the submucosal constitutive MC (unrelated to the immune system).¹ The former act in the regulation of immune host defence (food allergy, infections, inflammatory bowel disease (IBD)), tissue homeostasis (epithelial secretion and permeability), neuronal functions (peristalsis and pain) and brain–gut interaction.^{2,3} Submucosal MC are related to blood vessel growth and tissue remodeling.¹

Activated mucosal MC release inflammatory mediators (histamine, serotonin, proteases and cytokines) direct to the enteric nervous system (ENS) and its effector motor response, causing diarrhea and abdominal pain.^{1,2}

In healthy subjects, intestinal MC are less than 20 per high-power field (HPF).¹ Higher values have been reported for IBD,³ irritable bowel syndrome (IBS),⁴ food allergy,⁵ idiopathic constipation⁶ and colonic diverticular disease.⁷

We describe two case reports of *mastocytic enterocolitis*, a recently defined condition, characterized by dense MC infiltrate within the mucosa of the gastrointestinal tract.¹

A 21-year-old female presented to our Unit with a six months history of non-bloody diarrhea, abdominal pain and weight loss; she denied recent use of drugs. A previous colonoscopy revealed hyperaemia of the descending colon, with histological examination showing moderate lymphoplasmacellular infiltration of the lamina propria with an increased number of eosinophils (over 60 × 10 HPF). Mesalazine 800 mg tid was administered for 2 months, without benefit.

Laboratory tests showed normal levels of blood count, acute phase reactants, anti-tissue transglutaminase antibodies (AbtTG) and serum tryptase; fecal calprotectine, stool culture and parasitologic examination also proved negative.

A further ileocolonoscopy showed no lesions. Histology of the colorectal biopsies, however, revealed MC colitis, with diffuse positivity for CD117 (18, 33 and 34 MCs per HPF, in the right colon, the left colon and the rectum, respectively) and an increased number of eosinophils (Fig. 1).

Upper endoscopy was negative for macroscopic lesions; histological examination, however, revealed MC infiltration in the duodenum, antrum and fundus of the stomach, and distal esophagus (43, 24, 25 and 43 MC per HPF, respectively). Systemic mastocytosis was ruled out by normal histological findings for the bone marrow biopsy, as was any abdominal or pelvic alteration by a CT scan. Dermatological examination found no evidence of cutaneous lesions.

The patient was first treated with histamine H1 and H2 receptor antagonist (Ranitidine 150 mg bid and Cetirizine 250 mg bid) and a granule membrane stabilizing agent (chromoglycate sodium 200 mg qid). This resulted in some benefit. Treatment with metilprednisolone 16 mg bid was then started and led to a prompt resolution of the symptoms. One year later she suffered a relapse and was treated with a cycle of beclomethasone dipropionate 10 mg/day for 6 weeks which resolved the symptoms.

A 57 year-old woman presented to our Unit for episodic bloody stools for 2 months. She had undergone a kidney transplant operation 22 years before as treatment of polycystic kidney disease and she suffered from hypertension. She had been taking cyclosporine 100 mg/day, prednisone 5 mg/day, beta-blocker, calcium-channel blockers, furosemide, aspirin and omeprazole. A previous colonoscopy revealed hyperaemia of the right colon and diverticula of the left colon, with histological examination showing mild chronic inflammation with lymphoplasmacellular cells, eosinophils and superficial epithelial erosions.

She was treated with mesalazine 1600 mg bid and rifaximin 400 mg bid. Results of screenings for bacterial, viral and parasitological infections were negative; serum levels of acute-phase reactants, AbtTG and fecal calprotectine were normal. Histological examination following an upper endoscopy revealed a mild chronic inflammation without *H. pylori* infection or MC infiltration.

Colonoscopy was repeated, confirming the presence of the diverticula, without any other macroscopic lesions. Histological examination of the colorectal biopsies revealed edema and inflammatory infiltration of the lamina propria, an increased number of eosinophils and MC infiltration of the muscularis mucosa and the submucosa in both the left and right colon (35 and 20 MC per HPF, respectively) (Fig. 2). Histological examination of a bone marrow biopsy ruled out systemic mastocytosis. An abdominal and pelvis CT scan, carried out two months before, detected the presence of diverticula in the left colon with mild thickening of the sigmoid wall, hypoplasia of both kidneys, and an ectopic transplanted normal kidney in the right iliac fossa; no other lesions were found.