



## IMAGE OF THE MONTH

## Acquired double pylorus: An unusual complication of duodenal ulcer



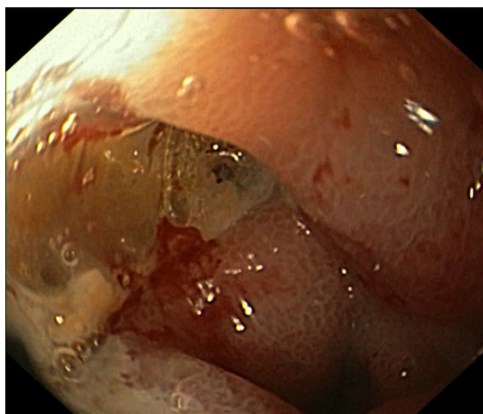
### Doble piloro adquirido: una complicación poco usual de úlcera duodenal

Flávio Pereira\*, Cátia Leitão, Richard Azevedo, José Tristan, António Banhudo

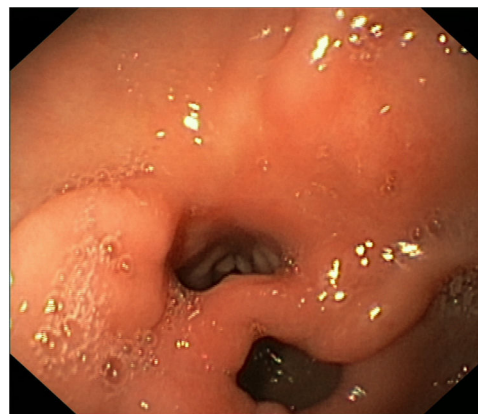Department of Gastroenterology, Amato-Lusitano Hospital, Castelo Branco, Portugal

A 52-year-old man presented with epigastric pain and melena. He had a history of alcohol and tobacco abuse, and he had taken nonsteroidal anti-inflammatory drugs (NSAIDs) for low back pain.

Upper endoscopy showed a deep ulcer with elevated borders and about 15 mm of diameter (Fig. 1) on the anterior wall of the duodenal bulb. The patient was treated with a proton-pump inhibitor.



**Figure 1** A deep ulcer with elevated borders and about 15 mm of diameter on the anterior wall of the duodenal bulb.



**Figure 2** Two openings connecting the lesser curvature of the gastric antrum and the duodenal bulb, consistent with a double pylorus.

Endoscopic follow-up two months later showed two openings connecting the gastric antrum and the duodenal bulb (Fig. 2), separated by a tissue septum. The scope could enter the bulb through both openings. The findings were consistent with an acquired double pylorus from a duodenal ulcer complication. *Helicobacter pylori* colonisation was not found on histology of gastric biopsies.

Double pylorus is a rare condition characterised by the presence of a double communication between the gastric antrum and the duodenal bulb.<sup>1</sup> It may occur as a congenital abnormality or as an acquired complication of a penetrating ulcer.<sup>2</sup> It can be found incidentally or present with epigastric

\* Corresponding author.  
E-mail address: [pereiraflavio14@gmail.com](mailto:pereiraflavio14@gmail.com) (F. Pereira).

pain, dyspepsia or gastrointestinal bleeding.<sup>1,2</sup> The diagnosis is typically made based on endoscopic findings.<sup>1</sup> Treatment is mostly conservative, including proton-pump inhibitors, avoidance of NSAIDs and *Helicobacter pylori* eradication.<sup>1-3</sup>

### Disclosure statement

No conflicts of interest to declare.

### References

1. Lei J, Zhou L, Liu Q, Xu C. Acquired double pylorus: Clinical and endoscopic characteristics and four-year follow-up observations. *World J Gastroenterol*. 2016;22:2153–8.
2. Hu TH, Tsai TL, Hsu, et al. Clinical characteristics of double pylorus. *Gastrointest Endosc*. 2001;54:464–70.
3. Lee TH, Park SH. Double pylorus secondary to recurrent ulcer: serial endoscopy follow-up. *Endoscopy*. 2008;40 Suppl 2:E226.