



## ORIGINAL ARTICLE

# Systematic review of case reports of oropharyngeal dysphagia following the use of antipsychotics



Marta Miarons<sup>a,b,\*</sup>, Laia Rofes<sup>b</sup>

<sup>a</sup> Pharmacy department, Mataró Hospital, Spain

<sup>b</sup> Centro de Investigación Biomédica en Red de enfermedades hepáticas y digestivas (CIBERehd), Instituto de Salud Carlos III, Barcelona, Spain

Received 27 June 2018; accepted 7 September 2018

### KEYWORDS

Antipsychotic agents;  
Deglutition;  
Deglutition disorders;  
Systematic review

### Abstract

**Objective:** The purpose of this systematic review was to examine the effect of antipsychotic medication on dysphagia based on clinical case reports.

**Patients and methods:** Literature searches were performed using the electronic databases PubMed and Embase. In PubMed, we used the MeSH terms “antipsychotic agents” OR “tranquilizing agents” combined with “deglutition disorders” OR “deglutition”. In Embase, we used the Emtree terms “neuroleptic agents” combined with “swallowing” OR “dysphagia”. Two reviewers assessed the eligibility of each case independently.

**Results:** A total of 1043 abstracts were retrieved, of which 36 cases met the inclusion criteria; 14 cases were related to typical antipsychotics and 22 to atypical antipsychotics. Dysphagia occurred together with extrapyramidal symptoms in half of the cases and was the only prominent symptom in the other half. The most common strategy against dysphagia was changing to another antipsychotic ( $n = 13$ , 36.1%).

**Conclusions:** The data from this review indicate that antipsychotics can increase the prevalence of dysphagia.

© 2018 Elsevier España, S.L.U. All rights reserved.

### PALABRAS CLAVE

Agentes antipsicóticos;  
Deglución;  
Alteraciones de la  
deglución;  
Revisión sistemática

### Revisión sistemática de los casos clínicos que relacionan la disfagia orofaríngea con el uso de antipsicóticos

#### Resumen

**Objetivo:** El propósito de esta revisión sistemática fue examinar el efecto de los fármacos antipsicóticos en la disfagia según los casos clínicos reportados.

**Pacientes y métodos:** La búsqueda bibliográfica se realizó utilizando las bases de datos electrónicas PubMed y Embase. En PubMed, utilizamos los términos MeSH «agentes antipsicóticos»

\* Corresponding author.

E-mail address: [mmiarons@cscdm.cat](mailto:mmiarons@cscdm.cat) (M. Miarons).

o «agentes tranquilizantes» combinados con «trastornos de deglución» o «deglución». En Embase, utilizamos los términos de Emtree «agentes neurolépticos» combinados con «deglutir» o «disfagia». Dos revisores evaluaron la elegibilidad de cada caso de forma independiente.

**Resultados:** Se obtuvieron un total de 1.043 resúmenes, de los cuales 36 casos cumplieron los criterios de inclusión; 14 casos estuvieron relacionados con antipsicóticos típicos y 22 con antipsicóticos atípicos. La disfagia se produjo junto con síntomas extrapiramidales en la mitad de los casos, y fue el único síntoma prominente en la otra mitad. La estrategia más común contra la disfagia fue cambiar a otro antipsicótico (n = 13; 36,1%).

**Conclusiones:** Los datos de esta revisión sistemática indican que los antipsicóticos pueden aumentar la prevalencia de la disfagia.

© 2018 Elsevier España, S.L.U. Todos los derechos reservados.

## Background

Dysphagia is a symptom that refers to difficulty or discomfort during the progression of the alimentary bolus from the mouth to the stomach.<sup>1</sup> From an anatomical standpoint, dysphagia may result from oropharyngeal or esophageal dysfunction and, from a pathophysiological viewpoint, from other structure-related or functional causes.<sup>1</sup> The prevalence of oropharyngeal dysphagia in patients with dementia ranges from 13% to 84%, depending on subject selection and method, and being higher in more severe phases of the disease.<sup>2-4</sup> Its prevalence in Parkinson's disease is 52–82%; it affects up to 84% of patients with Alzheimer's disease, and more than 60% of elderly institutionalized in mental health services.<sup>5-7</sup>

Dysphagia, or swallowing impairment, can be a result of behavioral, sensory, or motor problems (or a combination).<sup>8-10</sup> Medication can also cause dysphagia. It is particularly critical to establish the causality of drug reactions in patient groups at risk of swallowing dysfunctions, such as older people or patients with pre-existing anatomical or functional changes.<sup>11</sup> Between medications causing dysphagia, antipsychotic drugs are often misused and overused,<sup>12</sup> and in recent years, the inappropriate use of antipsychotics has resulted in several safety concerns.<sup>13</sup> To determine the possible association between antipsychotics and the development of swallowing disorders is highly relevant as dysphagia may play a role in antipsychotic-induced pneumonia associated with high mortality rates.<sup>14</sup> In recent years, several observational studies have explored the association between antipsychotic use, both typical and atypical, and the risk of community-acquired pneumonia (CAP), mainly in older patients.<sup>15</sup> Current scientific evidence supports an association between use of antipsychotics in community-dwelling older people and development of CAP in a dose-dependent manner soon after the beginning of treatment.<sup>16</sup>

Postulated mechanisms of antipsychotic-induced dysphagia include that it can occur as an extrapyramidal adverse reaction, because dopamine blockade can cause dysphagia or laryngospasm.<sup>17,18</sup> Moreover, some patients may experience dysphagia in combination with other extrapyramidal

symptoms (EPS), whereas in others dysphagia may be the only EPS experienced.<sup>17</sup>

Populations at risk of drugs causing dysphagia include individuals with neurologic degenerative diseases, dementia, stroke, Parkinson disease, myasthenia gravis and in some mental health patients.<sup>18,19</sup> Furthermore, elderly patients may be at increased risk of dysphagia secondary to muscle atrophy, structural changes in the oropharynx, reduced esophageal peristalsis, or cognitive impairment.<sup>18-20</sup> Although this group may be more susceptible to the complications associated with dysphagia, it can impact any age group treated with antipsychotics.

The aim of this current systematic literature review is to critically revise the current scientific evidence based on case reports concerning the relationship between antipsychotic use and occurrence of swallowing problems, presenting an overview of the different types of antipsychotics in terms of their negative effects on swallowing function.

## Methods

### Search strategy

The systematic review was conducted in accordance with PRISMA guideline.<sup>21</sup> A comprehensive literature search of the electronic databases PubMed and Embase was conducted. All available inclusion studies up to the date of the review (January 2017) were obtained.

Electronic databases were searched using the respective Thesaurus (MeSH or Emtree terms) to link the concept of dysphagia with the concepts of antipsychotics (Table 1). To identify the most recent publications not yet assigned MeSH or Emtree terms, the search was supplemented by using free-text words (truncated) in Embase and PubMed, for the period after January 2015: *deglut\** or *swallow\** or *dyspha\** were combined with *neuroleptic\** or *antipsychotic\** (Table 1). The reference lists of all the included articles were searched for additional literature.

The search was limited to publications dealing with human adults and in English, German, French and Spanish languages.

**Table 1** Search strategy for Pubmed and Embase.

	Database	Search terms	Limits	Results
Mesh terms	Pubmed	(“Deglutition Disorders”[Mesh] OR “Deglutition”[Mesh]) AND (“Antipsychotic Agents”[Mesh] OR “Tranquilizing agents” [Mesh])	Adult: 19+ years Humans; English or French or German or Spanish	82
Emtree terms	Embase	(“Dysphagia/OR Swallowing/ ) AND (Neuroleptic Agent)	Humans; English or French or German or Spanish	950
Free text words	Pubmed	(Swallow* OR dysphag* OR deglut*) AND (neuroleptic* OR antipsychotic*)	Yr= ‘‘2015–Current’’	4
Free text words	Embase	As per Pubmed Free Text	Yr= ‘‘2015–Current’’	7

**Table 2** Inclusion/exclusion criteria.

Inclusion criteria	Exclusion criteria
Adults	Children
OD caused by AP treatment	Drug-interactions
Oral- and/or pharyngeal-stage dysphagia	Esophageal dysphagia
Case reports	Original articles, Conference abstracts, review studies, non-peer-reviewed literature
English, Spanish, French, German language articles	Articles in other languages

## Study selection

The two authors independently assessed the eligibility of the abstracts in accordance with the inclusion/exclusion criteria described in Table 2. Briefly, all case reports assessing the relationship between antipsychotic treatment and OD in adults and published in English, Spanish, German or French were considered. There were no limitations on disease duration, disease severity or treatment duration.

The full text of the clinical case reports considered potentially eligible was acquired and the two authors reapplied the inclusion and exclusion criteria independently.

## Data extraction

A data extraction form was created, piloted, and refined by the first author. The second author reviewed and confirmed extracted data. Data extracted included first author and year of publication, antipsychotic causing the swallowing impairment (including dose and route of administration), neurological and swallowing features, treatment or measures taken to solve the swallowing impairment and clinical outcome. Moreover, data was classified according to whether the antipsychotic was typical or atypical.

## Results

### Studies Selection

A total of 957 articles were selected from Embase and 86 from PubMed. Following application of inclusion criteria regarding article titles and abstracts, consensus was reached on 114 potential articles of which 72 met the inclusion criteria following full text review. Removal of duplicate articles resulted in a total of 33. Three more case reports were added using reference lists resulting in a total of 36 articles. The rest (132) did not meet the inclusion/exclusion criteria, did not present enough information on study outcomes or the full text was not available. Fig. 1 presents the flow diagram of the reviewing process according to PRISMA.

### Characteristics of the clinical case reports included

An overview of the characteristics of the 36 case reports included (one of the articles include two cases) that reflect the effect of antipsychotic medication on deglutition is given in Table 3

. The following data are summarized (if reported) for each case report: patient characteristics, antipsychotics causing dysphagia, neurological and dysphagia features, dysphagia assessment method, treatment and clinical outcome.

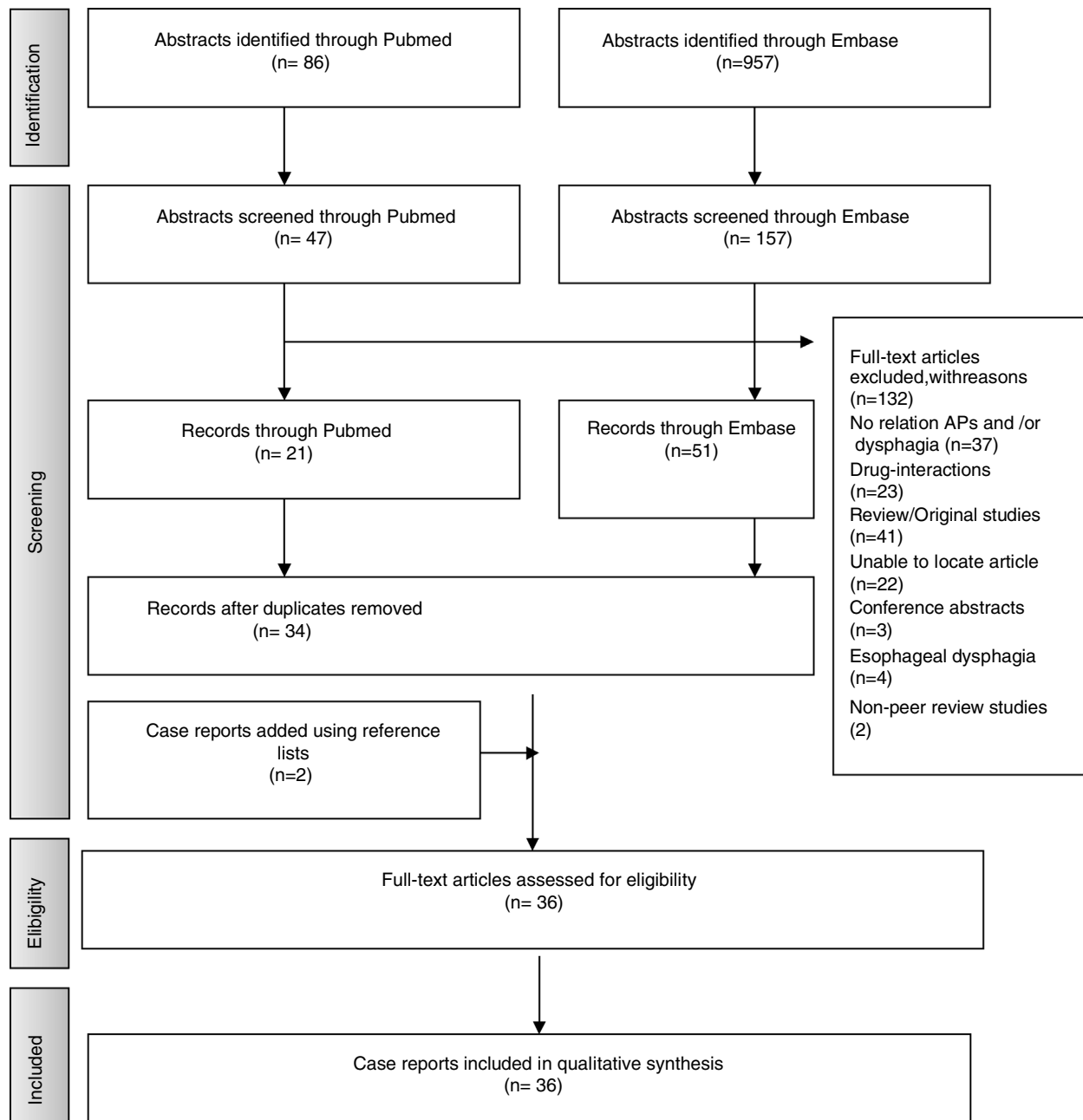
### Patient characteristics

Age range of cases included was 18–89 years, with a mean age of  $48 \pm 19.48$  years.

Antipsychotic-related dysphagia was reported in patients with psychiatric disorders (9 in patients with schizophrenia,<sup>31,35,37,39,45,48,52,54,56</sup> 4 in patients with bipolar disorder<sup>41,44,50,55</sup> 4 in patients with depression,<sup>24,25,28,30</sup> 3 in patients with psychosis,<sup>23,44,51</sup> 2 in patients with schizoaffective disorder,<sup>36,49</sup> 2 in patients with behavioral disorder<sup>26,42</sup> and 1 in a patient with delirium),<sup>42</sup> in patients with dementia (2 in patients with Alzheimer disease<sup>33,53</sup> and 3 in other dementia disorders),<sup>34,38,53</sup> in 2 patients with insomnia,<sup>22,27</sup> in 1 patient with Huntington’s disease<sup>47</sup> and in 1 with severe mental retardation.<sup>46</sup>

### Antipsychotic drugs related to dysphagia

We found 14 cases of OD related to typical antipsychotics and 22 related to atypical.



**Figure 1** Flow-diagram of the number of studies screened, included and excluded at each stage.

Among typical antipsychotics, in 6 of the cases OD was considered related with haloperidol,<sup>25,27–29,31,32</sup> 2 with flupenthixol,<sup>22,35</sup> 2 with trifluoperazine,<sup>24,30</sup> 2 with loxapine,<sup>26,33</sup> 1 with chlorpromazine,<sup>23</sup> 1 with fluspirilene<sup>34</sup> and 1 with fluphenazin;<sup>52</sup> and, among atypical antipsychotics, 9 of the cases of OD were considered related with risperidone<sup>38,39,46,48,51–54,56</sup> but also with quetiapine,<sup>36,40,41,55</sup> olanzapine,<sup>37,43,50</sup> aripiprazole,<sup>42,43</sup> ziprasidone (two cases),<sup>44</sup> paliperidone<sup>45</sup> and clozapine.<sup>49</sup>

#### Neurological and dysphagia features

Dysphagia occurred together with other parkinsonian features in 14 of the cases<sup>24,28–31,34,35,37,40,41,44,47,53,56</sup> while it

was the only prominent manifestation of EPS in other 14<sup>13,23,25–27,32,36,39,42,45,50–52,54</sup> The onset of symptoms after initiation of antipsychotic drug was variable and ranged from a few days to three months, with the majority of patients (65%) complaining of disturbed swallowing within the first month.

As in patients with Parkinson's disease, EPS-related dysphagia affected all stages of swallowing. Thus, in the majority of patients reported so far, oral dysfunction and pharyngeal dysfunction were observed, and aspiration, the most dangerous consequence of dysphagia, was reported in 8 of the cases.<sup>24,25,28,33,35,41,51,52</sup>

**Table 3** Case-reports of antipsychotic-induced dysphagia. DA: dysphagia assessment; ENT: ear, nose and throat examination; FOIS: Function Oral Intake Scale Score; MBS: modified barium swallow; NE: neurologic examination; NE: Neurological examination; NMS: neuroleptic malignant syndrome.

Author	Patient characteristics	Antipsychotics related to dysphagia	Neurological and dysphagia features	Dysphagia assessment method	Treatment	Clinical outcome
<i>Typical antipsychotics</i>						
Agarwal et al. <sup>22</sup>	61-year-old man with insomnia	Flupenthixol 0.5 mg	NE: involuntary flexion of all fingers of his left hand and developed involuntary, forceful closure of both eyes. No other focal dystonia or parkinsonism, and the rest of the neurological examination was normal. DA: involuntary orolingual movements causing slurring of speech. Intermittent opening of his mouth that cause spillage of food while eating. Difficulty in swallowing solid food. He could swallow only semi-solids or liquids. Three months later, he was completely unable to swallow solids and liquids, necessitating placement of a nasogastric tube.	Clinical assessment	Flupenthixol was tapered and discontinued over 2 weeks. Then started tetrabenazine 50 mg (increased 100 mg/daily over two weeks), trihexyphenidyl 10 mg and clonazepam 1 mg daily.	Dysphagia had reduced and he was able to swallow liquids and solids without any difficulty. Dystonia and orobucolingual dyskinesia also improved significantly.
Baheshree et al. <sup>23</sup>	28-year-old lady with psychotic symptoms	Chlorpromazine	NE: no abnormalities DA: mild difficulty in swallowing, which progressively worsened up to the point where she had severe dysphagia for both solids and liquids.	Self-reported, ENT evaluation, barium swallow test.	A dose of promethazine did not bring about any improvement. Then, she shifted to risperidone 8 mg daily and trihexyphenidyl 2 mg daily.	The patient slowly started taking oral fluids. After 2 weeks, she did not have any swallowing difficulty and was able to take food normally.

Table 3 (Continued)

Author	Patient characteristics	Antipsychotics related to dysphagia	Neurological and dysphagia features	Dysphagia assessment method	Treatment	Clinical outcome
Bashford et al. <sup>24</sup>	A 74-year-old woman with a major depressive episode.	Trifluoperazine hydrochloride 2 mg twice a day on day 1, and then increased to 5 mg twice a day.	NE: Parkinson's disease-like tremor. DA: bedside feeding examination: increased transit time in the oral phase of the swallow, but no delay in reflex swallowing. Normal laryngeal elevation, weak cough reflex. Videofluoroscopic evaluation: the oral phase revealed disorganized oral movements, with reduced bolus formation. Oral transit time was increased to greater than 5 seconds. A significant lingual tremor was noted, which impaired this patient's oropharyngeal phase coordination and worsened with solid consistencies. Marked tongue pumping was noted at rest and during lingual propulsion. The swallow reflex was delayed, being triggered at the level of the velum and valleculae. Multiple swallows were required to clear moderate pooling in the valleculae. Pooling was also observed in the pyriform sinuses. Fluid was observed to pass into the pharynx and laryngeal vestibule during oral phase preparation before the swallow reflex was triggered. Laryngeal penetration was observed with the swallowing of puree consistencies. This resulted in silent aspiration, which was not cleared by either involuntary or voluntary cough.	Bedside feeding examination. Videofluoroscopic evaluation (modified barium swallow)	She had modification of consistencies, training in supraglottic swallow, and head positioning. Change or stopping the medication was not possible.	Not provided

Table 3 (Continued)

Author	Patient characteristics	Antipsychotics related to dysphagia	Neurological and dysphagia features	Dysphagia assessment method	Treatment	Clinical outcome
Bulling et al. <sup>25</sup>	76-year-old man with recurrent depression.	Haloperidol 6 mg daily, lithium	NE: no involuntary movements or abnormalities of tone. DA: difficulty starting a swallow with the bolus only reaching as far as the pharynx and then causing cough and expectoration. Impaired pharyngeal peristalsis with significant pooling of barium in the vallecula and piriform fossa and subsequent gross aspiration. Endoscopy showed a non-inflamed segment of Barrett's mucosa 3 cm in length and a 1 cm slightly fibrotic stricture through which the scope could be easily advanced.	Videofluoroscopy Endoscopy	Cessation of all antipsychotic and antidepressant medication and naso-enteric feeding.	Re-evaluation of his swallowing three weeks after admission showed a marked improvement with no overt signs of audible aspiration. Repeat video barium swallow confirmed that considerable improvement.
Chau-martin et al. <sup>26</sup>	28-year-old man with behavioral disorder with homicide on the street.	Loxapine 300 mg Increase of loxapine treatment of 450 mg/day to 700 mg/day	NE: no extrapyramidal syndrome. DA: dysphagia to solids with choking and regurgitation, aggravated by the increase of loxapine dose. Upper gastrointestinal endoscopy shows no anatomical lesion.	Endoscopy. No functional assessment of swallowing was done.	Treatment with loxapine was stopped, and aripiprazole 15 mg daily was introduced.	The patient had a very rapid clinical improvement and dysphagia did not reoccur.
González et al. <sup>27</sup>	82-year-old woman with insomnia.	Haloperidol 2.5 mg daily.	NE: normal DA: dysphagia to solids and liquids. When she attempted to swallow, the liquids would come out through her nose. Oropharyngeal exam revealed an edentulous oral cavity, with no ulcers, lesions or thrush. No gag reflex. No eliciting a response when the physician inserted his index finger and touched the glottis.	Clinical assessment	Administration of subcutaneous injection of diphenhydramine 25 mg.	Resolved within 30 min of injection. She was able to eat bread and drink water. Continue haloperidol at the same dose with no problems since then.

Table 3 (Continued)

Author	Patient characteristics	Antipsychotics related to dysphagia	Neurological and dysphagia features	Dysphagia assessment method	Treatment	Clinical outcome
Hugues et al. <sup>28</sup>	41-year-old woman with agitated depression with some psychotic features and discoid lupus.	Haloperidol 1.5 mg, flupenthixol 20 mg every 2 weeks.	NE: cogwheel rigidity and some bradykinesia in the limbs but no other neurological signs. DA: 8-weeks history of worsening, intermittent, painless dysphagia for solids and liquids. Complete failure of laryngeal elevation and closure, and failure of cricopharyngeal opening. Pooling occurred in the pyriform fossae and above the cricopharyngeus, and there was aspiration of contrast into the larynx and trachea.	Videofluoroscopy	Haloperidol was stopped.	Two weeks later she was able to swallow clear fluids. On discharge videofluoroscopy showed normal elevation of the larynx and normal opening of the cricopharyngeus without pooling or aspiration.
Lee et al. <sup>29</sup>	55-year-old man with a history of traumatic brain injury.	Haloperidol 5 mg orally every hour as needed, haloperidol 2 mg intravenously every 12 h, risperidone 0.25 mg orally	NE: EPS, he developed mild rigidity and cogwheeling of his extremities. DA: 5 days after starting haloperidol, development of acute dysphagia, he was unable to ingest oral medications.	Not specified	Haloperidol and risperidone were discontinued, and diphenhydramine 25 mg intravenously twice daily was started for extrapyramidal symptoms.	His rigidity and dysphagia improved within a few days of stopping haloperidol.



Table 3 (Continued)

Author	Patient characteristics	Antipsychotics related to dysphagia	Neurological and dysphagia features	Dysphagia assessment method	Treatment	Clinical outcome
Leopold et al. <sup>30</sup>	38-year-old woman with depression.	Trifluoperazine 5 mg daily (11 days treatment)	NE: alert, attentive, slowed hypophonic, monotonic, dysarthric speech. Obvious parkinsonian features including moderately severe bradykinesia, akinesia, rigidity of all limbs, and slight postural instability. DA: abnormalities during the pre-esophageal stages of ingestion included a severe reduction of lip and tongue movements, minimal chewing of solids, segmented lingual transfer with moderate posterior lingual leakage for all test substance, decreased velar retraction which delayed bolus transfer, and slow vocal cord adduction with no aspiration or penetration.	Videofluoroscopy using liquids and foods of varying consistence	All medications were withdrawn.	Within 24 h, slight improvement of mastication was noted. Also, a daily rapid relief of both parkinsonism and dysphagia, particularly mastication and transfer functions were observed. Three month after discharge no parkinsonism was observed.
Nishikawa et al. <sup>31</sup>	42 year-old female with schizophrenia.	Haloperidol 5 mg daily.	NE: slight rigidity of her arms. No signs of parkinsonian gait or finger tremor CDA: dysphagia, difficulty in opening her mouth	Not specified	Haloperidol was reduced and an antidepressant was started.	Her EPS persisted for 45 days. Gradually, both her EPS and psychotic symptoms lessened. During 5-year follow-up, she has not shown any sign of oral dyskinesia, psychotic symptoms or parkinsonism.
Shinno et al. <sup>32</sup>	75-year old male with adenocarcinoma of the colon and delirium.	Haloperidol 5 mg daily (4 days).	NE: over-sedation DA: dysphagia (no more details provided)	Not specified	Haloperidol was discontinued and quetiapine 25 mg daily was prescribed.	After quetiapine treatment no adverse effects were present.

Table 3 (Continued)

Author	Patient characteristics	Antipsychotics related to dysphagia	Neurological and dysphagia features	Dysphagia assessment method	Treatment	Clinical outcome
Sokoloff et al. <sup>33</sup>	79-year-old man with Alzheimer disease.	Loxapine 5 mg two times daily (1 week).	NE: not provided DA: choking on medication. Wet voice. Moderate to severe oral-pharyngeal dysphagia characterized by reduced chewing ability, tongue pumping, defective tongue movements, and reduced base of tongue movement (reduced oral control). Delay in initiating a swallow, pooling of residue in the valleculae and pyriform sinuses, penetration of residue and silent aspiration of thin liquid.	Clinical assessment and Videofluoroscopy	Loxapine was discontinued and chlorpromazine was given in a dose of 10 mg every 8 h.	One week later a second clinical evaluation indicated an improvement in swallowing with no significant signs of oral or pharyngeal dysphagia. A second videofluoroscopic evaluation one month later, indicated improvement in both the oral and pharyngeal phases.
Stones et al. <sup>34</sup>	89-year-old woman with dementia	Fluspirilene 3 mg weekly (two months)	NE: left hemiparesis DA: one day of absolute dysphagia. Choking on saliva.	Not specified	Benzotropine 2 mg intravenously	There was a sustained improvement in her dysphagia. Two months later there had been no recurrence.
Tang et al. <sup>35</sup>	46-year-old man with schizophrenia	Flupentixol 20 mg intramuscular injection every 2 weeks (for 4 years).	NE: severe involuntary movement such as lateral jaw movement, tongue twisting and limbs tremor and athetoid movement, especially over upper limbs. DA: difficulty in swallowing liquid food initially, and then solid. Episodes of sudden asphyxia at eating. Abnormal bolus holding, piecemeal swallowing, abnormal epiglottic movement, delayed oral transit time in paste barium meal and delayed pharyngeal transit time in all kinds of barium meals, all of which resulted in frequent silent aspirations.	Clinical assessment and Videofluoroscopy	Biperiden 2 mg/3 times day was prescribed for a month but achieved no improvement. Amantadine 100 mg and Baclofen 5 mg daily were prescribed.	Nineteen days later his dysphagia improved much in ingestion of solid foods, but was still present with fluid. Follow-up videofluoroscopy revealed improved paste barium meal oral transit time and aspiration. Baclofen was increased to 5 mg twice daily, and both dysphagia and involuntary movement improved 8 days later.

Table 3 (Continued)

Author	Patient characteristics	Antipsychotics related to dysphagia	Neurological and dysphagia features	Dysphagia assessment method	Treatment	Clinical outcome
<i>Atypical antipsychotics</i>						
Armstrong et al. <sup>36</sup>	31-year old woman schizoaffective disorder	Quetiapine 750 mg for 2 years.	NE: no evidence of any noticeable extrapyramidal side effects. DA: swallowing difficulty and choking while eating.	Not specified	Stopped medication and changed to aripiprazole 5 mg daily.	Swallowing difficulties remitted within 24–48 h after stopping quetiapine. Swallowing difficulties have not emerged for the last 10 months.
Bhat-tacharjee et al. <sup>37</sup>	25-year-old male with history of schizophrenia	Olanzapine 10 mg daily (3 weeks).	NE: tardive dystonia. DA: difficulty in swallowing intermittently when he attempted to eat solid food. He had no problem in taking liquid. MBS was normal. Lack of normal propulsive activity in pharynx and upper esophagus. Significant residues in the pharynx post-swallow.	Videofluoroscopy	Carbamazepine was started, 200 mg three times a day.	After 2 weeks of stating treatment, patient's symptoms improved and he was able to chew and eat solid food without any problem.
Brahm et al. <sup>38</sup>	46-year-old woman with dementia due to lithium toxicity and profound mental retardation	Risperidone 2 mg daily (increase from 1.5 mg to 2 mg the previous month), clozapine 500 mg.	NE: not provided DA: increase in drooling, difficulty swallowing and gurgling sounds.	Not specified	Risperidone was decreased to 1.5 mg daily.	On follow-up 3 days later, drooling and swallowing difficulties were resolving.
Duggal et al. <sup>39</sup>	35-year-old woman with paranoid schizophrenia.	Risperidone 4 mg daily.	NE: no abnormalities, and no other abnormal movements or extrapyramidal signs. DA: difficulty in swallowing solid and semi-solid food. No difficulty in swallowing liquids, but other kinds of food would tend to get stuck in her throat. Endoscopy and barium swallow study were unremarkable.	Clinical assessment, endoscopy and barium swallow study.	Risperidone was discontinued and she started clozapine 25 mg daily, which was increased to 75 mg daily over 3 weeks.	She had complete resolution of dysphagia without any additional medications.

Table 3 (Continued)

Author	Patient characteristics	Antipsychotics related to dysphagia	Neurological and dysphagia features	Dysphagia assessment method	Treatment	Clinical outcome
Kobayashi et al. <sup>40</sup>	68-year-old man with impairment of consciousness.	Quetiapine 50 mg daily and amantadine 75 mg.	NE: EPS, including ‘‘lead pipe’’ and rigidity. NMS. DA: dysphagia	Not specified	Quetiapine and amantadine were discontinued and dantrolene sodium 20 mg daily intravenously and bromocritine 5 mg daily were started.	NMS was resolved.
Kohen et al. <sup>41</sup>	66-year-old female with bipolar disorder.	Quetiapine 200 mg	NE: residual cerebellar symptoms of dysmetria, dysarthria and ataxia DA: Delayed transfer of puree and fluids with aspiration of thick fluids.	Videofluoroscopy	Quetiapine was tapered off.	1 month later she had a repeat MBS which showed patient improvement.
Lin et al. <sup>42</sup>	54-year-old male who presented ritual behavior, irregular life pattern, social withdrawal, self-talking, and poor personal care.	Aripiprazole 10 mg daily initially, titrated to 30 mg daily within 3 weeks.	NE: no other signs of extrapyramidal symptom, except slight salivary drooling. DA: difficulty in swallowing on the third day of aripiprazole – both solid and semisolid food got stuck in his throat and he could eat only by means of drinking. The function oral intake scale (FOIS) score was four points.	Clinical assessment FOIS	Aripiprazole was tapered to 20 mg daily, and trihexyphenidyl 4 mg daily was added but swallowing disturbance persisted, so the treatment was changed to paliperidone 6 mg daily.	Two days later, he could eat cooked solid foods without difficulty, and his FOIS score progressed to six points.
Matsuda et al. <sup>43</sup>	23-year-old woman with auditory hallucinations for 9 years	Aripiprazol 3 mg daily initially and then 18 mg daily	NE: slurred speech. Gait disturbance. No focal neurological deficit or major abnormality except for postural tremor in her hands. DA: mild dysphagia. Tardive dystonia in the larynx.	Not specified	Aripiprazole was stopped and started quetiapine at 200 mg daily, which was titrated to 400 mg and maintained.	Her vocal symptoms began to improve a few weeks after admission, continuing thereafter until her vocal and gait disturbance had almost disappeared. After 1 year with quetiapine at 400 mg daily her functioning returned to normal.

Table 3 (Continued)

Author	Patient characteristics	Antipsychotics related to dysphagia	Neurological and dysphagia features	Dysphagia assessment method	Treatment	Clinical outcome
Mel-lacheruvu et al. <sup>44</sup>	51-year old man with a history of bipolar disorder 21-year-old African American man with acute psychosis and a familiarly history of schizophrenia.	30 mg of ziprasidone intramuscular (IM). 20 mg of ziprasidone IM	NE: not provided DA: difficulty speaking and swallowing, and was noted to have stridor. some pooled secretions but no laryngeal edema or macroglossia. NE: not provided DA: he developed trouble swallowing and worsening stridor.	Laryngoscopy Not specified	He was administered 50 mg of diphenhydramine hydrochloride IM. He was administered 2 mg of cogentin (benztropine) IM.	Within 5 min the symptoms had resolved. Later, he was continued on 40 mg of oral ziprasidone twice daily and 50 mg of oral diphenhydramine hydrochloride twice daily and no further problems were reported.  Within several minutes, his symptoms resolved. He was continued on oral ziprasidone of up to 80 mg twice daily and 2 mg of oral cogentin twice daily. The cogentin was tapered over the course of 2 weeks without recurrence of the laryngeal symptoms. He had no further recurrence of dysphagia.
Mend-hekar et al. <sup>45</sup>	18-year-old man with schizophrenia (DSM-IV-TR criteria), history of being suspicious, irritable, withdrawn, muttering to self, and having grandiose ideas and disturbed biological functions for a duration of 1 year.	Paliperidone 6 mg daily, After taking only two doses of paliperidone and within 12 h of his last dose, he noted signs of dysphagia	NE: No evidence of organic illness, and no abnormal movements on other parts of the body. DA: choking sensation in his throat if he tried to ingest any solid or semisolid food and made gurgling sounds. He had little difficulty taking liquids, but solid food would stick in his throat.	Clinical assessment	He was given intramuscular promethazine 50 mg and he showed remarkable recovery in swallowing. Paliperidone was replaced by clozapine 200 mg daily.	

Table 3 (Continued)

Author	Patient characteristics	Antipsychotics related to dysphagia	Neurological and dysphagia features	Dysphagia assessment method	Treatment	Clinical outcome
Montañés-Pauls et al. <sup>46</sup>	30-year old woman with severe mental retardation	Risperidone 3 mg/daily increased to 6 mg/daily.	NE: not provided DA: 5 months after dose increase, difficulty swallowing solid foods and liquids.	Not specified	Not improvement with biperiden 1 mg/8 h. Stopped risperidone and changed to quetiapine 400 mg daily.	The patient improved.
Moreno et al. <sup>47</sup>	43 year-old male with Huntington's Disease	Olanzapine 10 mg daily.	NE: NMS with severe parkinsonism DA: dysphagia	Not specified	Olanzapine was discontinued.	The patient presented a gradual improvement and two weeks later remained in his basal clinical situation.
Nair et al. <sup>48</sup>	35-year old man with schizophrenic relapse.	Risperidone 4 mg daily.	NE: not provided DA: difficulty in swallowing. Physical examination revealed remarkable swelling of the uvula without fever.	Self-reported and physical exam.	Risperidone was discontinued. Benzotropine 2 mg intramuscularly was given.	Within 2 h dysphagia disappeared, and there was a dramatic normalization in the size of the uvula.
Pearlman et al. <sup>49</sup>	42-year-old man with schizoaffective disorder unresponsive to other APs.	Clozapine 660 mg daily (3 months treatment).	NE: not provided DA: hypersalivation and disturbance of swallowing. Normal elevation of the pharynx but retained barium in the vallecular and piriform sinuses, which cleared after several swallows and which suggested decreased pharyngeal peristalsis.	Videofluoroscopy	Benzotropine 2 mg was administered and instruction in swallowing two or three times without inhaling were given.	Benzotropine had not effect but the instructions in swallowing alleviated the sensation of choking without affecting the sialorrhea. After 9 months, the sialorrhea had abated, despite a dose increase to 900 mg/day.

Table 3 (Continued)

Author	Patient characteristics	Antipsychotics related to dysphagia	Neurological and dysphagia features	Dysphagia assessment method	Treatment	Clinical outcome
Sagar et al. <sup>50</sup>	25-year-old man with bipolar affective disorder.	Olanzapine 20 mg	NE: no focal neurologic deficits or signs of parkinsonism. CDA: increased salivation and difficulty in swallowing his saliva and in taking food orally or drinking water.	Not specified	Olanzapine dose was reduced to 10 mg daily and was stopped over the next 5 days and the patient was continued on sodium valproate 1000 mg and clonazepam 4 mg daily.	The dysphagia resolved over the next week.
Sico et al. <sup>51</sup>	58-year-old man with psychotic disorder	Risperidone 5 mg daily.	NE: intact mental status with no emotional lability. Electromyography/nerve conduction studies showed no evidence of neuropathy, myopathy or motor neuron disease. DA: severe oropharyngeal hypomotility with resultant poor oropharyngeal clearance after swallowing and aspiration. laryngeal aspiration.	Videofluoroscopy	Discontinuation of risperidone	After 9 days he was able to tolerate a soft diet. His bulbar symptoms improved, including return of the gag reflex. One month later, his facial diplegia and dysphagia completely resolved.

Table 3 (Continued)

Author	Patient characteristics	Antipsychotics related to dysphagia	Neurological and dysphagia features	Dysphagia assessment method	Treatment	Clinical outcome
Stewart <sup>52</sup>	71-year-old man with paranoid schizophrenia.	Intramuscular injection of fluphenazin decanoate 37.5 mg and oral fluphenazin up to 20 mg daily; dysphagia onset after 4 days.	NE: no parkinsonism DA: normal oral phase, aspiration of thin and thick liquids; pooling of residues in the pyriform sinus.	Videofluoroscopy	Fluphenazin decanoate reduced to 25 mg biweekly without additional oral dose.	Normal videofluoroscopy was found after 10 weeks
Stewart <sup>53</sup>	76-year-old man with Alzheimer's disease and aggressive behavior	Risperidone 1.5 mg daily; dysphagia and parkinsonism noted after 3 months	NE: Mild parkinsonism (mild rigidity, decrement in stride length) DA: poor bolus control; delayed initiation of the pharyngeal phase, decreased and slowed laryngeal elevation, poor laryngeal closure.	Videofluoroscopy	Treatment changed to olanzapine 2.5 mg daily.	Parkinsonism resolved within 10 days and normal videofluoroscopy was found after 6 months
Varghese et al. <sup>54</sup>	38-year-old man with schizophrenia.	Risperidone 4 mg daily (6 months).	NE: no signs of parkinsonism. CDA: difficulty in swallowing food and water.	Self-reported	Reduction of the Risperidone dose from 4 mg to 3 mg	The patient had significant reduction in his dysphagia.
Vohra et al. <sup>55</sup>	40-year old female with bipolar affective disorder and moderate to severe learning disability.	Quetiapine 300 mg daily increased to 750 mg daily	NE: not provided CDA: symptoms of dysphagia after two weeks of dose increment.	Clinical assessment and videofluoroscopy	Quetiapine was gradually substituted with olanzapine.	Dysphagia disappeared completely and has not reoccurred since then.
Yamashita et al. <sup>56</sup>	50-year-old man with a 21-year history of chronic schizophrenia	Risperidone long-acting injection 37.5 mg every 2 weeks, levomepromazine 30 mg daily.	NE: NMS CDA: difficulty in swallowing, decreasing his oral intake.	Self-reported	Oral biperiden, 2 mg, was given, but NMS did not improve, then dantrolene 40 mg daily was initiated but risperidone was maintained.	After 11 month after discharge the patient did not experience NMS relapse.

CDA: clinical dysphagia assessment; DA: dysphagia assessment; ENT: ear, nose and throat examination; FOIS: Function Oral Intake Scale Score; MBS: modified barium swallow; NE: neurological examination; NMS: neuroleptic malignant syndrome.



**Table 4** Summarize of the characteristics of the clinical cases reported in patients with dysphagia following antipsychotics.

	Typical antipsychotics	Atypical antipsychotics
<i>Number of clinical cases reported (%)</i>	14 (38.8%)	22 (61.1%)
<i>Age and sex of the patients</i>	58.1 ± 21.0 years 50% man	43.0 ± 17.1 years 68.2% man
<i>Other manifestations of EPS (yes/no)</i>		
Yes	9 (64.3%)	5 (22.7%)
No	4 (28.6%)	10 (45.4%)
Not provided	1 (7.1%)	7 (31.8%)
<i>Dysphagia assessment method (N, %)</i>		
Clinical bedside assessment	2 (14.3%)	3 (13.6%)
Instrumental assessment	5 (35.7%)	8 (36.4%)
Bedside and instrumental assessment	4 (28.6%)	2 (9.1%)
Self-reporting swallowing symptoms	3 (21.4%)	3 (13.6%)
Not specified	0 (0%)	8 (36.4%)
<i>Treatment strategy (N, %)</i>		
Change to another antipsychotic	4 (28.6%)	8 (36.4%)
Change to a nonantipsychotic drug	2 (14.3%)	4 (18.2%)
Dose reduction	4 (28.6%)	6 (27.3%)
Administering a drug that reversed the effect	5 (35.7%)	6 (27.3%)
Swallowing training	1 (7.1%)	0 (0%)

EPS: extrapyramidal symptoms.

### Dysphagia assessment method

In eight of the cases included, the authors assessed OD by means of clinical bedside assessment,<sup>22,23,27,33,35,42,45,56</sup> in thirteen other cases instrumental assessment was used to assess dysphagia,<sup>25,26,28,30,32,35,37,41,44,49,51-53</sup> in six cases both clinical bedside and instrumental assessment were used,<sup>23,24,33,35,39,55</sup> in three cases patients by self-reporting swallowing symptoms,<sup>48,54,56</sup> and the other twelve case reports did not specify the method of dysphagia assessment.

### Treatment

Several strategies to resolve dysphagia were reported: changing to another antipsychotic,<sup>23,26,32,33,36,39,42,43,45,46,53,55</sup> changing to a nonantipsychotic drug,<sup>37,41,50,60</sup> discontinuing antipsychotic therapy or lowering the dose,<sup>25,28,30,31,38,41,47,51,52,54</sup> continuing with the same treatment after administering a drug that reversed the effect,<sup>22,27,34,35,44,49,56</sup> stopping the treatment and administering a drug that reversed the effect,<sup>29,40,44,48</sup> and swallowing training.<sup>24</sup>

### Clinical outcome

All patients resolved dysphagia after the treatment (within 5 min, in the cases where a drug was used to resolve the symptoms, to 11 months).

The characteristics of the clinical cases reported in the literature of patients with dysphagia following antipsychotics regarding the type of antipsychotic are summarized in Table 4.

### Discussion

Antipsychotic-associated dysphagia is a clinically relevant issue, as consistently documented in several case reports

in patients of all ages. This systematic review offers an overview of the various case reports dealing with antipsychotic drugs and their impact on swallowing function. The first conclusion we can draw is that the level of evidence on the effect of antipsychotic medication on the swallowing function is scarce as most of the information comes from case reports, but it is frequently reported.

Older patients are at increased risk for extrapyramidal adverse effects of these medications.<sup>57</sup> It is worth noting that the demographic characteristics of the cases included in this study suggested that antipsychotic-related dysphagia, although more common in older people, may occur in patients of all ages, and generally in dementia people and those institutionalized in mental health services.

We found 14 cases of dysphagia related to typical antipsychotics and 22 cases of dysphagia related to atypical antipsychotics. Even though this difference could be attributed to a publication bias, we have to emphasize again the capacity of atypical antipsychotics to be associated with OD, an issue sometimes neglected by clinicians. Dopaminergic neurons are felt to play a role in the homeostasis of the extrapyramidal system, which is thought to modulate and regulate motor neurons resulting in coordination of complex muscle movements such as swallowing.<sup>58</sup> In half the cases, dysphagia occurred together with other parkinsonian features but in the other half, OD was present as an isolated symptom. From a clinical point of view, isolated symptom cases present a difficult challenge as the relationship between OD and antipsychotics may go unnoticed.

Antipsychotic-associated swallowing disorders have been commonly attributed to the blockage of dopamine D2 receptors in the nigrostriatal pathway, causing EPS and tardive dyskinesia. Antipsychotic-related dysphagia has been reported to affect both the oral and the pharyngeal stages

of swallowing due to the complex neuromodulatory control of coordinated movement in these phases.<sup>57</sup>

There is not a definitive and unique solution for antipsychotic related dysphagia and various actions were taken to resolve the swallowing affectation of the cases reported: changing to another antipsychotic, discontinuing antipsychotic therapy, lowering the dose, administering a drug that reversed the effect or performing swallowing therapy. While the swallowing problems was resolved positively in all cases, indicating the reversible effect of antipsychotic-related dysphagia, when changing to other antipsychotics it is important to remember that atypical antipsychotics may also affect swallowing function.

Our systematic review has several strengths; we conducted extensive literature searches, did not impose restrictions according to time of publication, assessed the reported cases according to predefined criteria and tried to exclude bias where we could. We were able to include more case reports than any previous review has done. However, our systematic review also has a number of important limitations, which pertain to the potential incompleteness of the evidence. Antipsychotics related OD is likely to be underreported; therefore, the number of cases summarized here is less meaningful than the fact that such incidents exist at all. Moreover, a systematic review does not allow to draw conclusions about the theoretical more incidence of dysphagia following typical in comparison with atypical antipsychotics, since dysphagia related to atypical antipsychotics may be more reported than with typical antipsychotics. The often-low quality of the primary reports further limits the conclusiveness of our findings. Several reports lacked sufficient detail, which renders the interpretation of their findings problematic. Given such limitations, a cause-effect relationship between the antipsychotics and OD is frequently difficult to establish. We did not include systematic reviews, clinical trials, surveys and cohort studies in our review. A previous systematic review of our team consisting of randomized clinical trials and observational studies also concluded that OD could be considered as an adverse effect of antipsychotic medication.<sup>59</sup>

In conclusion, several case reports of adverse effects regarding both typical and atypical antipsychotics have been published and some of them had serious consequences, even being reversible. Clinicians should be aware of this potential highlighting risk associated with antipsychotics.

## Authorship statement

Guarantor of article: Marta Miarons.

**Specific author contributions:** MM and LR: designed, coordinated the study, performed the research and drafted the manuscript. Both authors approved the final version of the manuscript.

## Financial support

None of the authors have any conflict of interest nor have received any funding related to the present study.

## Conflict of interests

The authors declare no conflict of interests.

## Acknowledgments

We thank Jane Lewis for reviewing the English of the manuscript. This work has been conducted within the framework of a doctoral thesis in medicine from the Autonomous University of Barcelona.

## References

1. Alagiakrishnan K, Bhanji RA, Kurian M. Evaluation and management of oropharyngeal dysphagia in different types of dementia: a systematic review. *Arch Gerontol Geriatr.* 2013;56:1e9.
2. Rösler A, Lessmann H, von Renteln-Kruse W, Stansschuss S. Dysphagia and dementia: disease severity and degree of dysphagia as assessed by fiberoptic endoscopy. *Eur J Geriatr.* 2008;31:127e130.
3. Langmore SE, Olney RK, Lomen-Hoerth C, et al. Dysphagia in patients with frontotemporal lobar dementia. *Arch Neurol.* 2007;64:58–62.
4. Horner J, Alberts M, Dawson D, Cook G. Swallowing in Alzheimer's disease. *Alzheimer Dis Assoc Disord.* 1994;8:177–89.
5. Cook IJ, Kahrillas PJ. AGA technical review on management of oropharyngeal dysphagia. *Gastroenterology.* 1999;116:455–78.
6. Suh M, Kim H, Na D. Dysphagia in patients with dementia: Alzheimer versus vascular. *Alzheimer Dis Assoc Disord.* 2009;23:178–84.
7. Easterling CS, Robbins E. Dementia and dysphagia. *Geriatr Nurs.* 2008;29:275–85.
8. Dysphagia: a tertiary and specialised medical problem. [www.dysphagiaonline.com](http://www.dysphagiaonline.com) [accessed 1.09.2017].
9. Diagnosis and treatment of Swallowing Disorders in Acute-Care Stroke Patients. Summary, Evidence Report/Technology Assessment. Agency for Health Care Policy and Research. Number 8, March 1999. Rockville, MD, USA. [www.ahrq.gov/clinic/epcsums/dysphsum](http://www.ahrq.gov/clinic/epcsums/dysphsum) [accessed 10.108.2017].
10. Disfagia Neurógena: Evaluación y tratamiento. Blocs 14. Fundació Institut Guttmann (ed. Badalona, 2002). [www.guttmann.com](http://www.guttmann.com) [accessed 4.09.2017].
11. Trifirò G. Antipsychotic drug use and community-acquired pneumonia. *Curr Infect Dis Rep.* 2011;13:262–8.
12. Miarons M, Cabib C, Barón FJ, Rofes L. Evidence and decision algorithm for the withdrawal of antipsychotic treatment in the elderly with dementia and neuropsychiatric symptoms.
13. Dorsey E, Rabbani A, Gallagher S, Conti R, Alexander G. Impact of FDA black box advisory on antipsychotic medication use. *Arch Intern Med.* 2010;170:96–103.
14. Cabré M, Serra-Prat M, Force L, Almirall J, Palomera E, Clavé P. Oropharyngeal dysphagia is a risk factor for readmission for pneumonia in the very elderly persons: observational prospective study. *J Gerontol A: Biol Sci Med Sci.* 2014;69:330–7.
15. Van der Steen JT, Mehr DR, Kruse RL, et al. Predictors of mortality for lower respiratory infections in nursing home residents with dementia were validated transnationally. *J Clin Epidemiol.* 2006;59:970–9.
16. Trifirò. Antipsychotic drug use and community-acquired pneumonia. *Curr Infect Dis Rep.* 2011;13:262–8.

17. Dziewas R, Warnecke T, Schnabel M, et al. Neuroleptic-induced dysphagia: case report and literature review. *Dysphagia*. 2007;22:63–7.
18. Visser HK, Wigington JL, Keltner NL, Kowalski PC. Biological perspectives: choking and antipsychotics: is this a significant concern? *Perspect Psychiatr Care*. 2014;50:79–82.
19. Schnoll-Susman F, Katz PO. Managing esophageal dysphagia in the elderly. *Curr Treat Options Gastroenterol*. 2016;14:315–26.
20. Kohen I, Lester P. Quetiapine-associated dysphagia. *World J Biol Psychiatry*. 2009;10 Pt 2:623–5.
21. Moher D, Liberati A, Tetzlaff J, Altman D. Preferred reporting items for systematic reviews and meta-analyses: the PRISMA statement. *PLoS Med*. 2009;6:e1000097.
22. Agarwal P, Ichaporia N. Flupenthixol-induced tardive dystonia presenting as severe dysphagia. *Neurol India*. 2010;58:784–5.
23. Baheshree R, Jonas S. Dysphagia in a psychotic patient: diagnostic challenges and a systematic management approach. *Indian J Psychiatry*. 2012;54:280–2.
24. Bashford G, Bradd P. Drug-induced Parkinsonism associated with dysphagia and aspiration: a brief report. *J Geriatr Psychiatry Neurol*. 1996;9:133–5.
25. Bulling M. Drug-induced dysphagia. *Aust N Z J Med*. 1999;5:748.
26. Chaumartin N, Monville M, Lachaux B. Dysphagia or dysphagias during neuroleptic medication? *Encephale*. 2012;38:351–5.
27. Gonzalez F. Extrapyrarnidal syndrome presenting as dysphagia: a case report. *Am J Hospic Palliat Med*. 2008;25:398–400.
28. Hugues T, Shone G, Lindsay G, Wiles C. Severe dysphagia associated with major tranquillizer treatment. *Postgrad Med J*. 1994;70:581–3.
29. Lee J, Takeshita J. Antipsychotic-induced dysphagia: a case report. *Prim Care Companion J Clin Psychiatry*. 2015;17:371.
30. Leopold N. Dysphagia in drug-induced parkinsonism: a case report. *Dysphagia*. 1996;11:151–3.
31. Nishikawa T, Hayashi T, Nishioka S, Matsumoto T. Two cases of neuroleptic-induced prolonged extrapyramidal symptoms. *Int J Psychiatry Clin Pract*. 2005;9:284–8.
32. Shinno H, Matsuoka T, Yamamoto O, Noma Y, Hikasa S, Takebayashi M, et al. *Int J Psychiatry Clin Pract*. 2005;9:284–8 [Psychogeriatrics 2007;7:64–8].
33. Sokoloff L, Pavlakovic R. Neuroleptic-induced dysphagia. *Dysphagia*. 1997;12:177–9.
34. Stones M, Kennie D, Fulton J. Dystonic dysphagia associated with fluspirilene. *Br Med J*. 1990;301:668–9.
35. Tang K, Hsieh M. A case of schizophrenia with dysphagia successfully treated by a multidimensional approach. *Gen Hosp Psychiatry*. 2010;32:559.e11–3.
36. Armstrong D, Ahuja N, Lloyd A. Quetiapine-related dysphagia. *Psychosomatics*. 2008;49:450–2.
37. Bhattacharjee S, Tiwari M, Dutt A, Kumar H. Olanzapine-induced task specific tardive dystonia and its response to carbamazepine: a case report. *Neurol India*. 2012;60:649–50.
38. Brahm N, Fast G, Brown R. Risperidone and dysphagia in a developmentally disabled woman. *Prim Care Companion J Clin Psychiatry*. 2007;9:315–6.
39. Duggal H, Mendhekar D. Risperidone-induced tardive pharyngeal dystonia presenting with persistent dysphagia: a case report. *Prim Care Companion J Clin Psychiatry*. 2008;10:161–2.
40. Kobayashi A, Kawanishi C, Matsumura T, et al. Quetiapine-induced neuroleptic malignant syndrome in dementia with Lewy bodies: a case report. *Prog Neuropsychopharmacol Biol Psychiatry*. 2006;30:1170–2.
41. Kohen I, Lester P. Quetiapine-associated dysphagia. *World J Biol Psychiatry*. 2009;10:623–5.
42. Lin T, Lee B, Liao Y, Chiu N, Hsu W. High dosage of aripiprazole-induced dysphagia. *Int J Eat Disord*. 2012;45:305–6.
43. Matsuda N, Hashimoto N, Kusumi I, Ito K, Koyama T. Tardive laryngeal dystonia associated with aripiprazole monotherapy. *J Clin Psychopharmacol*. 2012;32:297–8.
44. Melllacheruvu S, Norton J, Schweinfurth J. Atypical antipsychotic drug-induced acute laryngeal dystonia: 2. Case reports. *J Clin Psychopharmacol*. 2007;27:206–7.
45. Mendhekar D, Agarwal A. Paliperidone-induced dystonic dysphagia. *J Neuropsychiatry Clin Neurosci*. 2010;22:E37.
46. Montañés-Pauls B, Moya-Ripolles D. Neuromuscular dysphagia associated with risperidone. *Farm Hosp*. 2009;33:230–1.
47. Moreno J, Palau J, Díaz A, García J. Neuroleptic malignant syndrome induced by olanzapine in a patient with Huntington's disease. *J Huntington's Dis*. 2012;1:31–2.
48. Nair S, Saeed O, Shahab H, Sedky K, Garver D, Lippmann S. Sudden dysphagia with uvular enlargement following the initiation of risperidone which responded to benztropine: was this an extrapyramidal side effect? *Gen Hosp Psychiatry*. 2001;23:231–2.
49. Pearlman C. Clozapine nocturnal sialorrhea, and choking. *J Clin Psychopharmacol*. 1994;14:283.
50. Sagar R, Varghese S, Balhara Y. Dysphagia due to olanzapine, an antipsychotic medication. *Indian J Gastroenterol*. 2005;24:37–8.
51. Sico J, Patwa H. Risperidone-induced bulbar palsy-like syndrome. *Dysphagia*. 2011;26:340–3.
52. Stewart J. Reversible dysphagia associated with neuroleptic treatment. *J Am Geriatr Soc*. 2001;49:1260–1.
53. Stewart J. Dysphagia associated with risperidone therapy. *Dysphagia*. 2003;18:274–5.
54. Varghese S, Balhara Y, George S, Sagar R. Risperidone dysphagia. *J Postgrad Med*. 2006;52:327–8.
55. Vohra A, Patterson J. Quetiapine-induced dysphagia in a developmentally disabled woman with bipolar affective disorder. *German J Psychiatry*. 2011;14:95–7.
56. Yamashita T, Fujii Y, Misawa F. Neuroleptic malignant syndrome associated with risperidone long-acting injection: a case report. *J Clin Psychopharmacol*. 2013;33:127–9.
57. Gareri P, De Fazio P, De Fazio S, et al. Adverse effects of atypical antipsychotics in the elderly: a review. *Drugs Aging*. 2006;24:937–56.
58. Ertekin C, Aydogdu I. Neurophysiology of swallowing. *Clin Neurophysiol*. 2003;114:2226–44.
59. Miarons FM, Rofes SL. Antipsychotic medication and oropharyngeal dysphagia: systematic review. *Eur J Gastroenterol Hepatol*. 2017;29:1332–9.
60. Miarons FM, Rofes SL. Antipsychotic medication and oropharyngeal dysphagia: systematic review. *Eur J Gastroenterol Hepatol*. 2017;29:1332–9.