

Drug-induced liver injury due to mesterolone: A case report[☆]



Daño hepático inducido por mesterolona: a propósito de un caso

Dear Editor,

Mesterolone is an anabolic steroid with an acceptable indication only in very specific medical situations. However, its illicit use is growing exponentially, usually in young men who frequent gyms. It is relatively easy to skirt health regulations and acquire these often-imported compounds. Frivolous use of anabolic steroids for purposes of improving one's bodily appearance or athletic performance may have serious health consequences of which the medical community must be aware.

Case report

A 43-year-old man, an amateur bodybuilder with no prior history of note, was admitted to our centre due to jaundice which had started one week beforehand. He did not have a rash, adenomegaly or fever. Following thorough questioning, he admitted to having used Proviron[®] 25 mg/12 h as a muscle enhancer for 12 days and up to three weeks beforehand.

Bilirubin reached a peak level of 6.8 mg/dl; peak figures for alanine aminotransferase (ALT) and alkaline phosphatase (AP) were 248 and 116 (IU/l), respectively. The patient did not present any signs of liver failure at any time. His gamma-globulins (0.8 g/dl) and immunoglobulin G (IgG) (901 mg/dl) were normal. He had no eosinophilia ($0.2 \times 10^9/l$) or lymphopenia ($8.6 \times 10^9/l$). An ultrasound and magnetic resonance cholangiography intended to ascertain aetiology ruled out vascular and biliary disease. Viral causes of acute hepatitis were also ruled out (HAV-IgM, HBV-DNA, HCV-PCR, HEV-IgM, HEV-PCR, EBV-IgM and CMV-IgM were negative); liver-specific autoimmune markers were also negative.

The patient's signs and symptoms resolved spontaneously, and his laboratory values gradually improved. He required a 12-day hospital stay and subsequent follow-up for 56 days in order to confirm full recovery for all abnormal parameters (Fig. 1).

Discussion

In recent years, reports of cases of hepatotoxicity due to anabolic steroids have significantly increased; at present, such cases account for up to 8 % of all cases of drug-induced liver injury (DILI) in the Spanish registry of hepatotoxicity.¹

The ratio between the levels of ALT and AP, both expressed in terms of multiples of the upper limit of normal (40 and 130 [IU/l], respectively), enables three classic patterns of DILI to be distinguished: cytotoxic-hepatocellular (>5), cholestatic (<2) and mixed (2–5).² The typical pattern of hepatotoxicity of anabolic steroids is cholestatic; however, cytotoxic forms have also been reported, as in our case ($6.2/0.8 = 7.7$). The laboratory profiles discussed correspond, though not in full, to the type of histological lesion: up to 60 % of cases of DILI due to anabolic steroids feature histological data particular to hepatocellular lesion.³ Histological patterns of DILI due to anabolic steroids span a broad, highly varied and heterogeneous spectrum of hepatic lesions ranging from simple steatosis to liver tumours (adenomas, hepatocarcinomas and others). Peliosis hepatis has also been linked to chronic use of anabolic steroids.⁴

In suspicious cases, the classic CIOMS/RUCAM scale enables evaluation of causality in a simple fashion, taking into account data on temporal relationship, risk factors, course following suspension, other simultaneous drugs, concomitant aetiologies, prior information available on similar cases and, rarely, responses to re-exposure.⁵ In our case, a value consistent with probable hepatotoxicity (+ 8) was obtained.

As a result, there was a clear temporal association between the onset of symptoms and the use of the drug, and a secondary improvement following the suspension of the drug. In these cases, a coherent diagnosis may be made

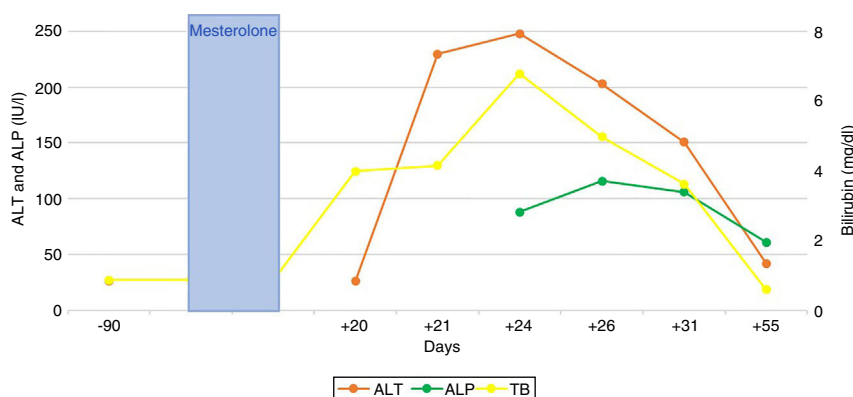


Figure 1 Chronological course of laboratory abnormalities and their temporal relationship to the use of the drug responsible.

[☆] Please cite this article as: Pérez Palacios D, Giráldez Gallego Á, Carballo Rubio V, Solà Fernández A, Pascasio Acevedo JM. Daño hepático inducido por mesterolona: a propósito de un caso. *Gastroenterol Hepatol.* 2019;42:629–630.

without resorting to biopsy, which is limited to situations of uncertainty and/or situations following an unfavourable course. Even in these situations of uncertainty, when diagnosis is especially complex, histological results may be non-specific.

In cases of DILI, a high level of clinical suspicion is crucial to prevent errors and delays in diagnosis, especially in patients who have acquired drugs illegally and may hide important information. The usual trend is towards spontaneous natural resolution; however, severe cases, life-threatening cases and cases resulting in death have been reported.¹

Clinicians have an ethical responsibility to report cases like the one described to the health authorities. Disclosure of data from hepatotoxicity registries should raise awareness in this regard among the agents involved and promote clinical alertness to this health problem of growing magnitude.

Acknowledgements

To Dr Miren García Cortés for her wise advice.

References

1. Robles-Díaz M, González-Jiménez A, Medina-Cáliz I, Stephens C, García-Cortés M, García-Muñoz B, et al. Distinct phenotype of hepatotoxicity associated with illicit use of anabolic androgenic steroids. *Aliment Pharmacol Ther.* 2015;41:116–25.
2. Aithal GP, Watkins PB, Andrade RJ, Larrey D, Molokhia M, Takikawa H, et al. Case definition and phenotype standardization in drug-induced liver injury. *Clin Pharmacol Ther.* 2011;89:806–15.
3. Medina-Cáliz I, García-Cortés M, González-Jiménez A, Cabello MR, Robles-Díaz M, Sanabria-Cabrera J, et al. Herbal and dietary supplement-induced liver injuries in the Spanish DILI Registry. *Clin Gastroenterol Hepatol.* 2018;16:1495–502.
4. Schwingel PA, Cotrim HP, dos Santos CR, dos Santos AO, de Andrade ARCF, Carruego MVVB, et al. Recreational anabolic-androgenic steroid use associated with liver injuries among brazilian young men. *Subst Use Misuse.* 2015;50:1490–8.
5. Danan G, Benichou C. Causality assessment of adverse reactions to drugs-I. A novel method based on the conclusions of international consensus meetings: Application to drug-induced liver injuries. *J Clin Epidemiol.* 1993;46:1323–30.

Domingo Pérez Palacios*, Álvaro Giráldez Gallego, Virginia Carballo Rubio, Ana Solà Fernández, Juan Manuel Pascasio Acevedo

Unidad de Gestión Clínica de Aparato Digestivo, Hospital Universitario Virgen del Rocío, Sevilla, Spain

* Corresponding author.

E-mail address: domipe3@gmail.com (D. Pérez Palacios).

2444-3824/

© 2019 Elsevier España, S.L.U. All rights reserved.

Autoimmune cerebellitis in Crohn's disease[☆]



Cerebelitis autoinmune en enfermedad de Crohn

Acute cerebellitis is an inflammatory condition that often involves an infectious aetiology and usually follows a benign course. Cases of autoimmune origin are rare, and cases associated with inflammatory bowel disease are anecdotal. Clinical suspicion, as well as its correlation with complementary tests and a congruent therapeutic response, leads in these few cases to the diagnosis of the condition.

A 37-year-old-male with a personal history of Crohn's disease in the ileum featuring a penetrating pattern with entero-enteric and ileo-vesical fistulas for which he had undergone surgery, on treatment with 40 mg of adalimumab weekly, went in for left hemicranial headache accompanied by paresthesia in his upper limbs and blurred vision in his left eye.

On examination, the patient was alert and orientated, presenting intermittent horizontal diplopia, paresis on abduction of his left eye with no associated diplopia, hyper-reflexia and postural tremor in all four limbs, with no dysmetria or dysidiadochokinesia. While standing, he maintained his balance and presented a gait with a slight increase in base of support.

He underwent laboratory testing which showed: glucose 114 mg/dl; urea 18 mg/dl; creatinine 0.57 mg/dl; total bilirubin 0.46 mg/dl; GGT 55 U/l; GOT 17 U/l; GPT 36 U/l; alkaline phosphatase 86 U/l; Na 143 mEq/l; K 3.69 mEq/l; C-reactive protein 0.45 mg/dl; haemoglobin 12.5 g/dl; leukocytes 7,200/mm³; platelets 341,000/mm³; aPTT 24s and D-dimer 0.70 mg/l. No abnormalities were found in thyroid hormones, immunoglobulins G, A and M, vitamin E, vitamin B₁₂ or folic acid. Serology for HIV, syphilis, toxoplasma, CMV, Epstein-Barr virus, brucella, *Borrelia burgdorferi*, *Mycoplasma pneumoniae* and *Chlamydia pneumoniae* was negative.

A CT scan of the head showed a slight diminishment of the extra-axial spaces in the posterior fossa with slight dilation of the third ventricle and lateral ventricles, whereupon cerebral venous thrombosis was ruled out. A thoracoabdominal CT scan and lumbar puncture showed no significant findings. Magnetic resonance imaging of the brain was ordered and reported an increased signal on T2 and flair in the cerebellar lobes, with a compression effect on the fourth ventricle, accompanied by a slight drop in the cerebellar tonsils in the context of signs of hypertension in

[☆] Please cite this article as: Práxedes González E, Lázaro Sáez M, Hernández Martínez Á, Vogt Sánchez EA, Arjona Padillo A, Vega Sáenz JL. Cerebelitis autoinmune en enfermedad de Crohn. *Gastroenterol Hepatol.* 2019. <https://doi.org/10.1016/j.gastrohep.2019.06.002>