



## SCIENTIFIC LETTERS

## Spontaneous hepatic portal venous gas in a patient with ulcerative colitis. A case report and a review



### Gas venoso portal hepático espontáneo en un paciente con colitis ulcerosa. Reporte de un caso y revisión

Hepatic portal venous gas (HPVG) has been defined as the presence of gas/air in the portal venous system. It has been traditionally associated with ischemic bowel processes, and has been considered as an ominous finding with a mortality rate up to 75%.<sup>1</sup>

HPVG has been described in patients with inflammatory bowel disease (IBD), mostly in Crohn's Disease (CD).<sup>2,3</sup> We present a case of HPVG and a literature review of the reported cases of HPVG in ulcerative colitis (UC).

A 45-year-old-woman was diagnosed with left-sided UC 15 years ago. She started treatment with azathioprine after a steroid-dependent flare-up in 2010, adding infliximab in 2012 due to the persistence of UC activity.

In October 2014, the patient was admitted in our emergency care unit presenting acute severe abdominal pain referred to epigastrium, nausea, tachycardia and fever (39.3 °C). She did not report evidence of clinical UC activity in recent months. In serial blood samples an increase in inflammatory markers (C-reactive protein [CRP], up to 63 mg/L from normal values within the first 24h) was observed. Simple chest and abdominal X-rays showed no relevant findings. An abdominal computed tomography (CT) was performed, and HPVG was observed in the left lobe of the liver (Fig. 1). Other intra-abdominal complications were ruled out and inflammatory changes in the rectum and sigma were observed, suggesting active UC. Immediately

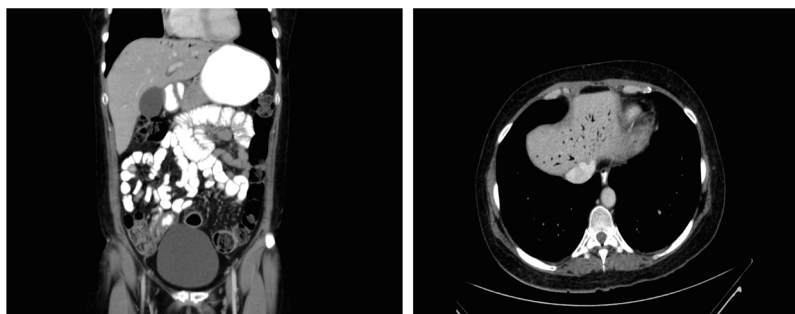
afterwards, a rectosigmoidoscopy was performed in which continuous mucosal damage with moderate inflammation up to 40 cm from the anal verge was identified.

The patient was admitted in our department for conservative management. Endovenous antibiotics (metronidazole plus ceftriaxone) and steroids (methyl-prednisolone 1 mg/kg daily) were initiated. Both azathioprine and infliximab treatment were discontinued.

The patient promptly reported feeling better and remained afebrile. Subsequent blood samples showed a progressive decrease of CRP (6.8 mg/L at discharge). Urine and blood cultures, as well as stool samples studies, were negative. At the 7th day of admission, a control CT-scan was performed, with complete HPVG resolution. Thereafter, endovenous steroids were changed for oral steroids. The patient remained in our unit for a total of 10 days and at the time she was discharged, antibiotics were stopped.

Liebman<sup>1</sup> reported 64 HPVG patients in which up to 72% cases were associated with bowel necrosis, with a global mortality rate of 75%, advocating for an aggressive management and urgent surgical exploration once this condition was diagnosed. More recently, an updated review of 182 patients with HPVG reported an overall mortality rate of 39%.<sup>2</sup> Other apparently more benign conditions, such as gastric ulcer, complications of endoscopic procedures and IBD, were associated with HPVG.<sup>2</sup> Some of these conditions reacted favorably to conservative management, suggesting that HPVG itself is not a predictor of poor outcome.<sup>1,2,4,5</sup>

Abdominal ultrasound and CT-scan are the radiological modalities used nowadays to diagnose HPVG.<sup>3,5</sup> The classical appearance of this entity is that of branching lucencies within 2 cm of the liver capsule, predominantly in the left lobe, which differs from biliary gas because the latter is associated with air within the central portion of the liver<sup>1-5</sup> (Fig. 1).



**Figure 1** Computed tomography (CT)-scan images at diagnosis of HPVG. (a) Axial reconstruction. (b) Coronal reconstruction. Portal vein gas is predominantly located within the left hepatic lobe in both CT-scan images. Air bubbles appear to extend within 2 cm of the liver capsule.

**Table 1** Cases of hepatic portal venous gas in ulcerative colitis.

Author	Gender	Age	UC extent	Years of UC	Prior procedure	Clinical features	Clinical UC activity	Diagnostic modality	Mucosal damage	Treatment	Outcome
Lazar et al. <sup>6</sup>	Male	48	Extensive	UK (1-3)	BE	Abdominal pain Fever Emesis	Flare	X-ray (plus perforation)	Yes	ATBs Sulfathalidine Prednisone	Recovery
Weinstein et al. <sup>11</sup>	Male	35	UK	6	BE	Malaise Chills Fever Tenderness	Remission	X-ray	Yes	ATBs	Recovery
Speer et al. <sup>12</sup>	Male	79	Left-sided <sup>a</sup>	10	None	Abdominal pain Low fever	Remission	X-ray	Yes	ATBs (as an outpatient)	Recovery
Kees et al. <sup>9</sup>	Female	44	Extensive	6	1-BE 2-BE	Low fever Mild TC	1-Flare 2-Remission	X-ray	1-Yes 2-Yes	Sulfasalazine, ATBs	1-Recovery 2-Recovery
Liebman et al. <sup>1</sup>	Male	23	UK	UK	BE	Lightheaded Shaking chill	Remission	X-ray	Yes	ATBs	Recovery
Christensen et al. <sup>8</sup>	Male	71	Left-sided <sup>a</sup>	5	BE	Mild stomach ache	Remission	X-ray	No	None	Recovery
Haber <sup>13</sup>	Female	45	Left-sided	4	RSC	Fever	Flare	X-ray	Yes	ATBs NG aspiration	Recovery
Birnberg et al. <sup>14</sup>	Female	24	UK	7	BE	Low fever	Remission	X-ray	Yes	ATBs	Recovery
Moss et al. <sup>15</sup>	Male	39	Extensive	<1	BE	Tenderness	Flare	X-Ray (plus perforation)	Yes	ATBs Surgery (subtotal colectomy)	Recovery
See et al. <sup>16</sup>	Female	53	UK	UK	Total colectomy due to fulminant colitis	Multiple organ failure	-	CT-scan	-	ATBs	Death
Bull et al. <sup>7</sup>	Female	60	Extensive	3	BE	None	Flare	X-ray	Yes	None	Recovery <sup>b</sup>
Paran et al. <sup>10</sup>	Male	51	UK	UK	None	Abdominal pain Bloodless diarrhea	Flare	CT-scan	Yes	Parenteral Nutrition ATBs	Recovery
Shah et al. <sup>17</sup>	Male	22	Extensive	UK	Total colectomy due to refractory UC	Abdominal pain Tachycardia Hypotension	-	CT-scan	-	Parenteral Nutrition ATBs	Recovery
Shinagawa et al. <sup>18</sup>	Male	18	Extensive	<1	Colonoscopy	Fever	Flare	CT-scan	Yes	ATBs	Recovery
Bamba et al. <sup>19</sup>	Male	54	Extensive	2.5	Colonoscopy	None	Flare	X-ray	Yes	Food deprivation ATBs	Recovery
Tanaka et al. <sup>20</sup>	Female	87	UK	22	None	Diarrhea Abdominal pain Vomiting	Flare	CT-scan	Yes	ATBs	Recovery

Table 1 (Continued)

Author	Gender	Age UC extent	Years of UC	Prior procedure	Clinical features	Clinical UC activity	Diagnostic modality	Mucosal damage	Treatment	Outcome
Fukita et al. <sup>21</sup>	Male	40 UK	9	None	Hematochezia Abdominal pain Fever	Flare	CT-scan	Yes	ATBs	Recovery
Present case	Female	45 Left-sided	15	None	Abdominal pain Fever	Remission	CT-scan	Yes	ATBs Prednisolone	Recovery

ATBs, Antibiotics; BE, Barium Enema; CT-scan, Computer Tomography-scan; NG, Naso-gastric; RSC, Rectoscopy; TC, Tachycardia; UC, Ulcerative Colitis; UK, Unknown, X-ray: plain film abdominal radiography.

<sup>a</sup> Minimum known extension.

<sup>b</sup> Panproctocolectomy due to UC flare nine days after admission.

The pathogenesis of HPVG could be explained as follows: (1) the passage of intraluminal air or gas-forming bacteria into the portomesenteric venous system due to mucosal disruption (2) increased bowel pressure that leads to bowel distension with mucosal disruption, described mainly in iatrogenic procedures such as colonoscopies and barium enemas; (3) the existence of abdominal infections.<sup>1,5</sup>

It seems that mucosal damage, as well as bowel distension secondary to increased bowel pressure in the setting of diagnostic studies, are the main factors that lead to the occurrence of HPVG in IBD patients.<sup>1,2,4,5</sup>

With the present case, only 18 cases of HPVG in patients with UC have been described in the English literature to date (Table 1).<sup>1,6,7-21</sup> Sixty one percent of cases were found after a barium enema or a colonoscopy. The majority of cases (88%) were managed conservatively. The mortality rate was 5% (one out of 18 patients), although it seems that in this case the fatal outcome was due to a complications occurred after an emergency surgery in the setting of fulminant colitis.<sup>16</sup>

Therefore, it seems that the management and treatment of HPVG has to be addressed to the underlying disease, which will determine the prognosis of the patients.

## Author contributions

Murzi M, Oblitas E, Garcia-Planella E and Gordillo J designed the case report; Posso M provided advice on performing the systematic review and searched in the databases; Murzi M and Gordillo J screened the articles and selected the full texts; Murzi M wrote the paper; Soriano G, Gordillo J, Pernas JC and Garcia-Planella E provided clinical advice; Soriano G, Gordillo J and Garcia-Planella E revised the paper. All authors contributed and approved the last version of the manuscript.

## Funding

No funding was provided for this manuscript.

## Conflict of interest

The authors declare that they have no conflict of interest.

## Acknowledgments

The authors would like to thanks German Soriano and David Bridgewater for the help with the translation of the present manuscript.

## References

- Liebman PR, Patten MT, Manny J, Benfield JR, Hechtman HB. Hepatic – portal venous gas in adults: etiology, pathophysiology and clinical significance. *Ann Surg.* 1978;187:281–7.
- Kinoshita H, Shinozaki M, Tanimura H, Umemoto Y, Sakaguchi S, Takifuji K, et al. Clinical features and management of hepatic portal venous gas: four case reports and cumulative review of the literature. *Arch Surg.* 2001;136:1410–4.

3. Nelson AL, Millington TM, Sahani D, Chung RT, Bauer C, Hertl M, et al. Hepatic portal venous gas: the ABCs of management. *Arch Surg*. 2009;144:575–81.
4. Ng SSM, Yiu RYC, Lee JFY, Li JCM, Leung KL. Portal venous gas and thrombosis in a Chinese patient with fulminant Crohn's colitis: a case report with literature review. *World J Gastroenterol*. 2006;12:5582–6.
5. Alqahtani S, Coffin CS, Burak K, Chen F, MacGregor J, Beck P. Hepatic portal venous gas: a report of two cases and a review of the epidemiology, pathogenesis, diagnosis and approach to management. *Can J Gastroenterol*. 2007;21:309–13.
6. Lazar HP. Survival following portal venous air embolization: report of a case. *Am J Dig Dis*. 1965;10:259–64.
7. Bull MJ, Kaye B. Portal vein gas following double-contrast barium enema. *Br J Radiol*. 1985;58:1129–30.
8. Christensen MA, Lu CH. Gas in the portal vein after air-contrast barium enema in a patient with inflammatory colitis. *South Med J*. 1982;75:1291–2.
9. Kees CJ, Hester CL Jr. Portal vein gas following barium enema examination. *Radiology*. 1972;102:525–6.
10. Paran H, Epstein T, Gutman M, Shapiro Feinberg M, Zissin R. Mesenteric and portal vein gas: computerized tomography findings and clinical significance. *Dig Surg*. 2003;20:127–32.
11. Weinstein GE, Weiner M, Schwartz M. Portal vein gas. *Am J Gastroenterol*. 1968;49:425–9.
12. Speer CS, Carlson DH. Portal venous air with survival in ulcerative colitis: report of a case. *Dis Colon Rectum*. 1972;15:453–8.
13. Haber I. Hepatic portal vein gas following colonoscopy in ulcerative colitis: report of a case. *Acta Gastroenterol Belg*. 1983;46:14–7.
14. Birnberg FA, Gore RM, Shragg B, Margulis AR. Hepatic portal venous gas: a benign finding in a patient with ulcerative colitis. *J Clin Gastroenterol*. 1983;5:89–91.
15. Moss ML, Mazzeo JT. Pneumoperitoneum and portal venous air after barium enema. *Va Med Q*. 1991;118:233–5.
16. See C, Elliott D. Images in clinical medicine. Pneumatosis intestinalis and portal venous gas. *N Engl J Med*. 2004;350, e3.
17. Shah A, Furajii HA, Cahill RA. Symptomatic pneumatosis intestinalis (including portal venous gas) after laparoscopic total colectomy. *World J Gastrointest Endosc*. 2014;6:564–7.
18. Shinagawa T, Hata K, Watanabe T. Hepatic portal venous gas after colonoscopy for ulcerative colitis: a case report. *J Crohns Colitis*. 2015;9:1058–9.
19. Bamba S, Tsujikawa T, Saotome T, Okuno T, Saito Y, Sasaki M, et al. Pneumatosis coli with ulcerative colitis as a rare complication of colonoscopy. *Clin J Gastroenterol*. 2010;3:233–6.
20. Tanaka H, Watanabe T, Nagai T, Minaga K, Kamata K, Komeda Y, et al. Hepatic portal venous gas associated with *Klebsiella oxytoca* infection in the absence of preceding antibiotic treatment. *Clin J Gastroenterol*. 2019 Feb 9, <http://dx.doi.org/10.1007/s12328-019-00947-1> [Epub ahead of print].
21. Fukita Y, Ishibashi H, Toyomizu M, Adachi S, Asaki T, Takeda T, et al. A case of *Staphylococcus aureus* colitis presenting with hepatic portal venous gas and pneumatosis cystoides intestinalis at onset. *Gastroenterol Endosc*. 2016;58:2182–90.

Marianette Murzi<sup>a</sup>, Jordi Gordillo<sup>a,\*</sup>, Elida Oblitas<sup>a</sup>, German Soriano<sup>a,b</sup>, Juan Carlos Pernas<sup>c</sup>, Margarita Posso<sup>d</sup>, Esther Garcia-Planella<sup>a</sup>

<sup>a</sup> *Gastroenterology and Hepatology Unit. Hospital de la Santa Creu i Sant Pau (IIB Sant Pau), Barcelona, Catalonia, Spain*

<sup>b</sup> *Centro de Investigaciones Biomédicas en Red en Enfermedades Hepáticas y Digestivas (CIBEREHD), Instituto de Salud Carlos III, Madrid, Spain*

<sup>c</sup> *Radiology Department, Abdominal Section. Hospital de la Santa Creu i Sant Pau (IIB Sant Pau), Barcelona, Catalonia, Spain*

<sup>d</sup> *Service of Clinical Epidemiology and Public Health, Hospital de la Santa Creu i Sant Pau (IIB Sant Pau), Barcelona, Spain*

\*Corresponding author.

E-mail address: [jgordillo@santpau.cat](mailto:jgordillo@santpau.cat) (J. Gordillo).

<https://doi.org/10.1016/j.gastrohep.2019.08.004>  
0210-5705/

© 2019 Elsevier España, S.L.U. All rights reserved.

## Black esophagus after combined liver-kidney transplantation<sup>☆</sup>



### Esófago negro tras doble trasplante hepatorenal

Acute oesophageal necrosis is an uncommon condition characterised by images of diffuse black pigmentation of the oesophagus on endoscopy. It is caused by ischaemia and usually manifests as upper gastrointestinal bleeding (UGB). The mortality rate is high and management varies from intensive medical treatment to surgery when associated with perforation.

We present a case of black oesophagus associated with mediastinitis after combined liver-kidney transplantation (CLKT).

This was a 50-year old male diagnosed with alcoholic cirrhosis of liver, Child-Pugh A5, MELD 20, portal hypertension and chronic kidney failure on peritoneal dialysis. CLKT was indicated. During the procedure, the patient required multiple transfusions and suffered a cardiac arrest with pulseless electrical activity for 2 min. In the immediate postoperative period, he was haemodynamically stable and the investigations performed (analyses, serial Doppler and cholangiogram) were normal. On postoperative day thirteen, the patient became haemodynamically unstable and had UGB. Gastroscopy showed black oesophagus due to circumferential necrosis along the entire length. CT scan showed pneumomediastinum and a mediastinal collection (Fig. 1A), with urgent surgical intervention indicated. The oesophagus was found to have transmural necrosis with a perforation in the lower segment causing mediastinitis. Transhiatal oesophagectomy, debridement and mediastinal

<sup>☆</sup> Please cite this article as: Aranda Escaño E, Prieto Calvo M, Perfecto Valero A, Tellaeche de la Iglesia M, Gastaca Mateo M, Valdivieso López A. Esófago negro tras doble trasplante hepatorenal. *Gastroenterol Hepatol*. 2020;43:25–27.