

3. Nelson AL, Millington TM, Sahani D, Chung RT, Bauer C, Hertl M, et al. Hepatic portal venous gas: the ABCs of management. *Arch Surg*. 2009;144:575–81.
4. Ng SSM, Yiu RYC, Lee JFY, Li JCM, Leung KL. Portal venous gas and thrombosis in a Chinese patient with fulminant Crohn's colitis: a case report with literature review. *World J Gastroenterol*. 2006;12:5582–6.
5. Alqahtani S, Coffin CS, Burak K, Chen F, MacGregor J, Beck P. Hepatic portal venous gas: a report of two cases and a review of the epidemiology, pathogenesis, diagnosis and approach to management. *Can J Gastroenterol*. 2007;21:309–13.
6. Lazar HP. Survival following portal venous air embolization: report of a case. *Am J Dig Dis*. 1965;10:259–64.
7. Bull MJ, Kaye B. Portal vein gas following double-contrast barium enema. *Br J Radiol*. 1985;58:1129–30.
8. Christensen MA, Lu CH. Gas in the portal vein after air-contrast barium enema in a patient with inflammatory colitis. *South Med J*. 1982;75:1291–2.
9. Kees CJ, Hester CL Jr. Portal vein gas following barium enema examination. *Radiology*. 1972;102:525–6.
10. Paran H, Epstein T, Gutman M, Shapiro Feinberg M, Zissin R. Mesenteric and portal vein gas: computerized tomography findings and clinical significance. *Dig Surg*. 2003;20:127–32.
11. Weinstein GE, Weiner M, Schwartz M. Portal vein gas. *Am J Gastroenterol*. 1968;49:425–9.
12. Speer CS, Carlson DH. Portal venous air with survival in ulcerative colitis: report of a case. *Dis Colon Rectum*. 1972;15:453–8.
13. Haber I. Hepatic portal vein gas following colonoscopy in ulcerative colitis: report of a case. *Acta Gastroenterol Belg*. 1983;46:14–7.
14. Birnberg FA, Gore RM, Shragg B, Margulis AR. Hepatic portal venous gas: a benign finding in a patient with ulcerative colitis. *J Clin Gastroenterol*. 1983;5:89–91.
15. Moss ML, Mazzeo JT. Pneumoperitoneum and portal venous air after barium enema. *Va Med Q*. 1991;118:233–5.
16. See C, Elliott D. Images in clinical medicine. Pneumatosis intestinalis and portal venous gas. *N Engl J Med*. 2004;350, e3.
17. Shah A, Furajii HA, Cahill RA. Symptomatic pneumatosis intestinalis (including portal venous gas) after laparoscopic total colectomy. *World J Gastrointest Endosc*. 2014;6:564–7.
18. Shinagawa T, Hata K, Watanabe T. Hepatic portal venous gas after colonoscopy for ulcerative colitis: a case report. *J Crohns Colitis*. 2015;9:1058–9.
19. Bamba S, Tsujikawa T, Saotome T, Okuno T, Saito Y, Sasaki M, et al. Pneumatosis coli with ulcerative colitis as a rare complication of colonoscopy. *Clin J Gastroenterol*. 2010;3:233–6.
20. Tanaka H, Watanabe T, Nagai T, Minaga K, Kamata K, Komeda Y, et al. Hepatic portal venous gas associated with *Klebsiella oxytoca* infection in the absence of preceding antibiotic treatment. *Clin J Gastroenterol*. 2019 Feb 9, <http://dx.doi.org/10.1007/s12328-019-00947-1> [Epub ahead of print].
21. Fukita Y, Ishibashi H, Toyomizu M, Adachi S, Asaki T, Takeda T, et al. A case of *Staphylococcus aureus* colitis presenting with hepatic portal venous gas and pneumatosis cystoides intestinalis at onset. *Gastroenterol Endosc*. 2016;58:2182–90.

Marianette Murzi^a, Jordi Gordillo^{a,*}, Elida Oblitas^a, German Soriano^{a,b}, Juan Carlos Pernas^c, Margarita Posso^d, Esther Garcia-Planella^a

^a *Gastroenterology and Hepatology Unit. Hospital de la Santa Creu i Sant Pau (IIB Sant Pau), Barcelona, Catalonia, Spain*

^b *Centro de Investigaciones Biomédicas en Red en Enfermedades Hepáticas y Digestivas (CIBEREHD), Instituto de Salud Carlos III, Madrid, Spain*

^c *Radiology Department, Abdominal Section. Hospital de la Santa Creu i Sant Pau (IIB Sant Pau), Barcelona, Catalonia, Spain*

^d *Service of Clinical Epidemiology and Public Health, Hospital de la Santa Creu i Sant Pau (IIB Sant Pau), Barcelona, Spain*

*Corresponding author.

E-mail address: jgordillo@santpau.cat (J. Gordillo).

<https://doi.org/10.1016/j.gastrohep.2019.08.004>
0210-5705/

© 2019 Elsevier España, S.L.U. All rights reserved.

Black esophagus after combined liver-kidney transplantation[☆]



Esófago negro tras doble trasplante hepatorenal

Acute oesophageal necrosis is an uncommon condition characterised by images of diffuse black pigmentation of the oesophagus on endoscopy. It is caused by ischaemia and usually manifests as upper gastrointestinal bleeding (UGB). The mortality rate is high and management varies from intensive medical treatment to surgery when associated with perforation.

We present a case of black oesophagus associated with mediastinitis after combined liver-kidney transplantation (CLKT).

This was a 50-year old male diagnosed with alcoholic cirrhosis of liver, Child-Pugh A5, MELD 20, portal hypertension and chronic kidney failure on peritoneal dialysis. CLKT was indicated. During the procedure, the patient required multiple transfusions and suffered a cardiac arrest with pulseless electrical activity for 2 min. In the immediate postoperative period, he was haemodynamically stable and the investigations performed (analyses, serial Doppler and cholangiogram) were normal. On postoperative day thirteen, the patient became haemodynamically unstable and had UGB. Gastroscopy showed black oesophagus due to circumferential necrosis along the entire length. CT scan showed pneumomediastinum and a mediastinal collection (Fig. 1A), with urgent surgical intervention indicated. The oesophagus was found to have transmural necrosis with a perforation in the lower segment causing mediastinitis. Transhiatal oesophagectomy, debridement and mediastinal

[☆] Please cite this article as: Aranda Escaño E, Prieto Calvo M, Perfecto Valero A, Tellaeche de la Iglesia M, Gastaca Mateo M, Valdivieso López A. Esófago negro tras doble trasplante hepatorenal. *Gastroenterol Hepatol*. 2020;43:25–27.

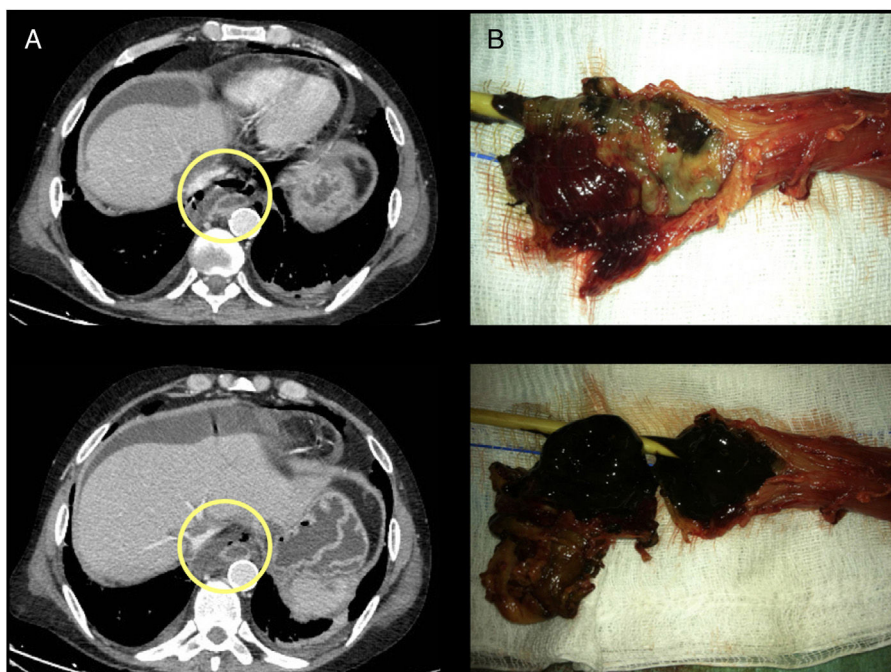


Fig. 1 (A) CT: pneumomediastinum and mediastinal collection. (B) Surgical specimen, black oesophagus.

lavage, cervical oesophagostomy and Witzel gastrostomy were performed. The pathology report revealed complete necrosis of the oesophageal mucosa secondary to acute necrotising oesophagitis (Fig. 1B). The patient made slow but satisfactory progress. One month after the transplant, he had a post-anastomotic thrombosis of the hepatic artery, but there were no clinical-analytical repercussions and it was managed conservatively. He was discharged home tolerating the gastrostomy tube well 72 days post-transplant. Just over three months after the transplant, the patient developed ischaemic cholangiopathy with the need for internal-external biliary drainage as bridging therapy for a re-transplant. At 14 months, due to the stability of his nutritional status and liver function, transit reconstruction was indicated prior to liver re-transplantation, with the aim of not hindering the mobilisation of the plasty afterwards. Retrosternal gastroplasty was performed with manual end-to-end oesophago-gastric anastomosis and placement of a jejunal feeding tube. On day eight, he was found to have necrosis of the gastroplasty with cervical anastomotic dehiscence. He required re-intervention with resection of the plasty and new cervical oesophagostomy. The patient died as a result of multiorgan failure secondary to sepsis.

Black oesophagus is highly unusual, occurs predominantly in males (4:1) and has an estimated prevalence of 0.008–0.2%.^{1,2} The main risk factors are diabetes, cancer, high blood pressure, chronic lung disease, alcoholism, coronary heart disease, cirrhosis, kidney failure, post-operative, immunosuppression and malnutrition. Triggers include hypoperfusion, gastroesophageal reflux and infections. All this leads to insufficient function of the protective barriers of the mucosa and tissue ischaemia with the resulting macroscopic black oesophagus appearance.^{1–4} The main complication is oesophageal perforation and mediastinitis, with a mortality rate of around 40%.²

It usually manifests as UGB, with endoscopy findings of diffuse circumferential involvement, with friable and blackened mucosa. It characteristically affects the distal segment of the oesophagus, with abrupt cessation at the gastroesophageal mucosal junction.^{1,2,5} The differential diagnosis must be established with other disorders which can cause similar endoscopic images (such as melanoma, acanthosis nigricans, pseudomelanosis, pseudomembranous oesophagitis and the ingestion of corrosives).⁵

This case involved at least seven of the known risk factors: hypoperfusion, cirrhosis, post-operative, kidney failure, hypertension, immunosuppression and malnutrition.⁴ No concomitant infection was diagnosed. We would suggest that the hypoperfusion which occurred during surgery was the main determinant,³ with multiple transfusions and then cardiac arrest, causing tissue ischaemia, in a patient with little physiological reserve.

Initial treatment consists of aggressive resuscitation, the use of proton pump inhibitors and the correction of trigger factors. In the event of complications, such as perforation or mediastinitis,^{1–3,5} emergency surgery may be necessary.

To our knowledge, this is the first reported case of black oesophagus in a CLKT recipient with successful treatment. Despite the perforation and mediastinitis in a patient who was immunocompromised because of the CLKT, the cause of death was the complications deriving from the transit reconstruction 14 months after the combined transplant.

Funding

No funding was received.

Conflict of interest

The authors have no conflicts of interest to declare.

References

1. Gurvits GE. Black esophagus: acute esophageal necrosis syndrome. *World J Gastroenterol*. 2010;16:3219–25.
2. Kanaparthy C, Singhal S, Guillaume C, Sharma S, Anand S. Acute gastrointestinal necrosis: “black esophagus” or “black gut”. *Trop Gastroenterol*. 2011;32:323–6.
3. Hichem Loghmani M, Ben Mansour W. L’oesophage noir: à propos d’un cas. *LA Tunisie Medicale*. 2018;96:142–7.
4. Lamers CR, Mares WGN, Bac DJ. Black esophagus: a case series and literature review of acute esophageal necrosis. *Scand J Gastroenterol*. 2018;53:1421–4.
5. Groenveld RL, Bijlsma A, Steenvoorde P, Ozdemir A. A black perforated esophagus treated with surgery: report of a case. *World J Gastrointest Surg*. 2013;5:199–201.

Elena Aranda Escaño^{a,*}, Mikel Prieto Calvo^{a,b},
Arkaitz Perfecto Valero^a, Miriam Tellaeché de la Iglesia^a,
Mikel Gastaca Mateo^{a,b,c}, Andrés Valdivieso López^{a,b,c}

^a Servicio de Cirugía General y Aparato Digestivo, Hospital Universitario Cruces, Barakaldo, Biscay, Spain

^b Unidad de Cirugía Hepatobiliar, Retroperitoneo y Trasplante Hepático, Hospital Universitario Cruces, Barakaldo, Biscay, Spain

^c Departamento de Cirugía, Radiología y Medicina Física, Universidad del País Vasco, Biscay, Spain

* Corresponding author.

E-mail address: elenamaria.arandaescano@osakidetza.eus (E. Aranda Escaño).

<https://doi.org/10.1016/j.gastre.2019.07.008>
2444-3824/

© 2019 Elsevier España, S.L.U. All rights reserved.

Colonic endometriosis mimicking a caecal carcinoid tumour[☆]



Endometriosis colónica que simula tumor carcinoide cecal

Tumours of the appendix are part of a subset of bowel cancers, the early diagnosis of which can be clinically challenging. They represent 0.5% of all gastrointestinal cancers and their prognosis depends on the type of lesion, the most common being carcinoid.¹ The involvement of the appendix in endometriosis is rare, affecting only 3% of all cases, while intraluminal endometriosis is even rarer, making diagnosis difficult and even mimicking appendix cancer.² In relation to cancer mimicking, we present the case of a 43-year-old woman with a history of hypothyroidism due to autoimmune thyroiditis and atrophic gastritis with gastric

neuroendocrine tumours resected by endoscopy. In a double-contrast follow-up CT scan, a lobulated lesion was identified in the caecum adjacent to the ileocaecal valve, with contrast uptake of approximately 27 × 21 × 20 mm, suggestive of cancer (Fig. 1).

The patient had no abdominal symptoms, weight loss, rectal bleeding or change in bowel habit. Blood tests and physical examination were also normal.

Investigations were completed with a colonoscopy, which showed a protruding appendiceal *ostium* with an inflammatory appearance. A biopsy was taken, with the protrusion moving around. The pathology report on the biopsy revealed chronic congestive colitis with oedema of the lamina propria and minimal acute activity, with moderate local eosinophilia. The case was presented before the multidisciplinary committee and in view of the patient’s history it was decided that the patient required oncology surgery to remove the lesion.

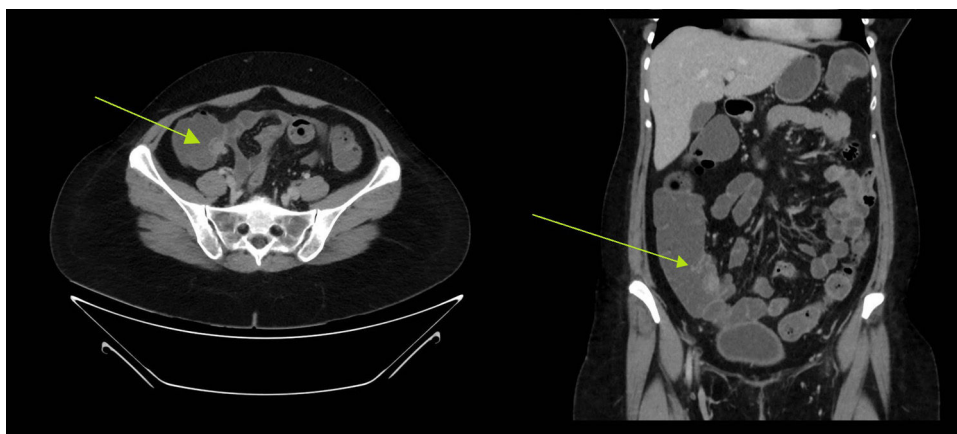


Fig. 1 Image of endometriosis mimicking carcinoid lesion in the caecum. Cross-sectional and coronal section of the double-contrast CT scan where a lobular lesion was identified in the caecum adjacent to the ileocaecal valve of approximately 27 × 21 × 20 mm, suggestive of carcinoid tumour lesion. The green arrow is pointing to the lesion.

[☆] Please cite this article as: Gómez Sánchez J, Zurita Saavedra M, Gonzalez Puga C, Gutierrez Sainz J, Mirón Pozo B. Endometriosis colónica que simula tumor carcinoide cecal. *Gastroenterol Hepatol*. 2020;43:27–28.