



## IMAGE OF THE MONTH

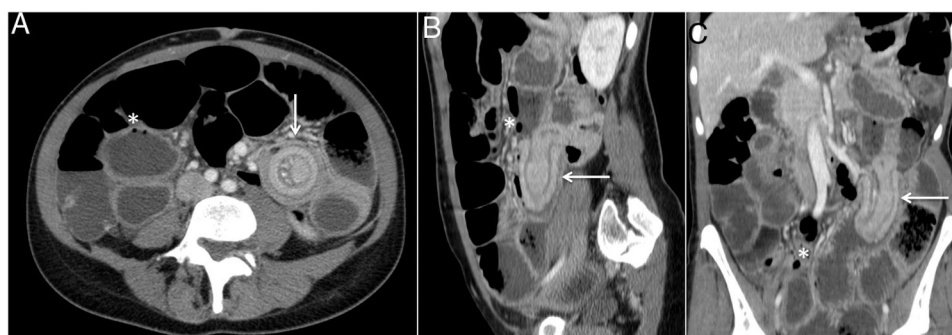
### Deep infiltrating endometriosis: An atypical cause of intestinal obstruction<sup>☆</sup>



### Endometriosis infiltrativa profunda, una causa atípica de oclusión intestinal

Margarita Fernández-de la Varga<sup>\*</sup>, Sergio Béjar-Serrano, Pablo del Pozo-del Valle

Servicio de Aparato Digestivo, Hospital Universitari i Politècnic La Fe, Valencia, Spain



**Figure 1** Abdominal CT scan showing ileo-ileal intussusception (arrows) in transverse (A), sagittal (B) and coronal (C) planes, with marked distension of proximal loops and pneumatosis intestinalis (asterisks).

Endometriosis is a benign chronic disease, which is common in women of fertile age.<sup>1</sup> Deep infiltrating endometriosis is a rare disease and may have serious manifestations. Its diagnosis is difficult when there is no gynecological history of endometriosis.<sup>2</sup>

We present a case of a 45-year-old patient who attended A&E for recurring episodes of abdominal pain with distension

and vomiting, which had been progressing over 10 months. She reported a worsening of the condition in recent days, with nausea, vomiting and constipation.

Upon examination she presented a distended and tympanic abdomen, with diffuse pain on palpation and no signs of peritoneal irritation. Bowel sounds were diminished.

The blood test showed no abnormalities. An abdominal X-ray revealed dilation of loops of the small intestine, suggesting occlusive symptoms. The study was completed with an abdominal CT scan (Fig. 1), in which ileo-ileal intussusception of the small intestine was observed, with marked distension of the proximal loops, and showing pneumatosis intestinalis and free fluid at the bottom of the Douglas pouch.

The patient underwent an emergency laparotomy, with resection of the intussuscepted segment of the small

<sup>☆</sup> Please cite this article as: Fernández-de la Varga M, Béjar-Serrano S, del Pozo-del Valle P. Endometriosis infiltrativa profunda, una causa atípica de oclusión intestinal. Gastroenterol Hepatol. 2020;43:262–263.

<sup>\*</sup> Corresponding author.

E-mail address: [margafvarga@gmail.com](mailto:margafvarga@gmail.com)  
(M. Fernández-de la Varga).

intestine (20 cm) and subsequent anastomosis, presenting a postoperative picture with no complications. The histology of the surgical specimen is compatible with a focus of intestinal endometriosis as the cause of the intussusception.

Intestinal endometriosis represents a diagnostic challenge given the non-specific nature of the symptoms it causes. The lack of treatment or the use of an erroneous treatment diminishes quality of life, on occasions leading to the onset of complications that may even compromise the patient's life.<sup>3</sup>

### Conflicts of interest

The authors have no conflicts of interest to declare.

### References

1. González CI, Cires M, Jiménez FJ, Rubio T. Endometriosis intestinal. *An Sist Sanit Navar*. 2008;31:197–200.
2. Ávila Vergara MA, Sánchez Carrillo V, Peraza Garay F. Obstrucción intestinal secundaria a endometriosis infiltrante profunda del íleon. *Rev Esp Enferm Dig*. 2018;110:208–9.
3. Krzeminski S. Intestinal endometriosis, a case report. *Pol Merkur Lekarski*. 2017;42:121–4.