

## IMAGE OF THE MONTH

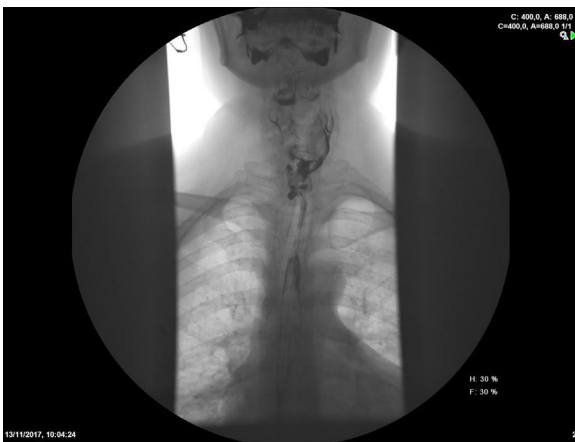## Dysphagia after esophageal perforation from anterior cervical osteosynthesis plate migration

### Disfagia tras perforación esofágica por migración de material de osteosíntesis cervical

Antonio Rodríguez-D'Jesus<sup>a,\*</sup>, Ana Gómez Rodríguez<sup>b</sup>, Nereida Fernández Fernández<sup>b</sup>, José Ignacio Rodríguez Prada<sup>b</sup>

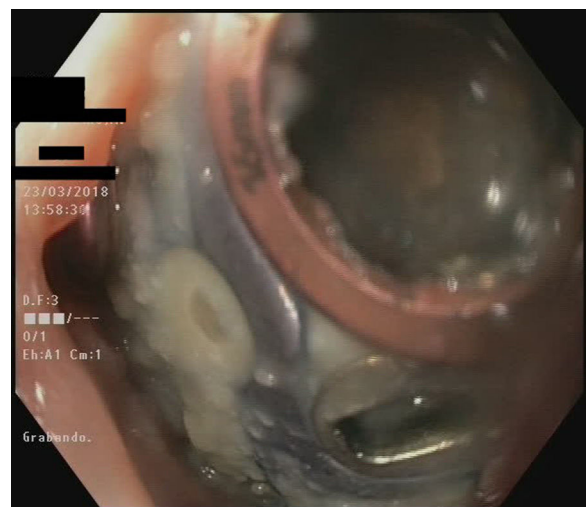
<sup>a</sup> Hospital Alvaro Cunqueiro Vigo, Pontevedra, Spain

<sup>b</sup> Servicio de Digestivo, Hospital Álvaro Cunqueiro, Vigo Hospital Alvaro Cunqueiro, Spain



**Figure 1** Diverticulum in close relationship with the osteosynthesis plate.

We present a case of a 58 years-old female with no past medical history but several cervical spine surgeries due to a traumatic cervical fracture and later on due to pseudoarthrosis of the osteosynthesis plate. The patient refers



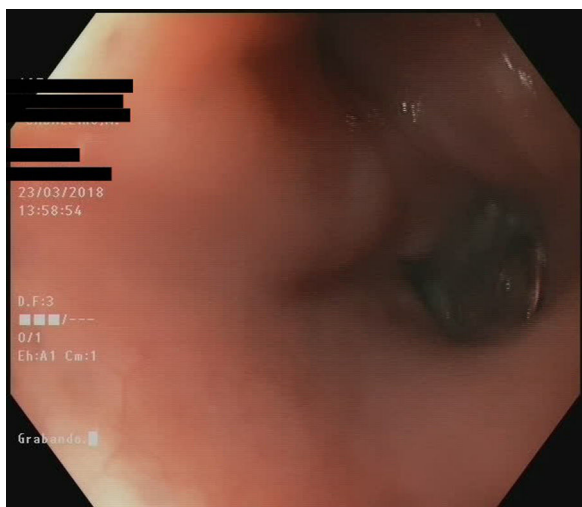
**Figure 2** Esophageal diverticulum plus osteosynthesis material.

years of cough after food intake accompanied by vomiting, which had been getting worse recently. These symptoms appear with both solids and liquids, and the patient complains that they began after surgical interventions.

An esophageal transit and CT Scanner were performed as the first diagnostic test showing the presence of a

\* Corresponding author.

E-mail address: [anjoro76@gmail.com](mailto:anjoro76@gmail.com) (A. Rodríguez-D'Jesus).



**Figure 3** Esophageal diverticulum plus osteosynthesis material.

diverticulum in close relationship with the osteosynthesis plate with contrast leak at that level (Fig. 1). A gastroscopy was requested. A diverticulum was observed and inside it, osteosynthesis material, that had eroded the wall and penetrated into its lumen (Figs. 2 and 3) (Video 1).

The case was discussed, and combined surgery was performed. Neurosurgery department removed the osteosynthesis plate, and esophagogastric surgeons completed diverticulectomy. The operation was carried out without complications, and the patient was discharged, asymptomatic, and tolerating a regular diet.

The literature on the esophageal complications of cervical surgery is scarce. Surgery of the cervical spine with anterior approach can lead to multiple complications, however most of them are extremely rare. Dysphagia is one of the most frequent (transient 5–30%, dysphagia 0.8–5%).<sup>1</sup> In cervical surgeries, esophageal perforation occurs between 0.25% and 1%, and pharyngeal perforation around 0.2–1.2%,<sup>2,3</sup> it usually occurs in the upper cervical region. In most cases, it is not detected during surgery, and symptoms appear later as local infection, fistula, sepsis, or mediastinitis. It often occurs as a result of tissue retraction or graft displacement.

## Appendix A. Supplementary data

Supplementary data associated with this article can be found, in the online version, at [doi:10.1016/j.gastrohep.2020.02.017](https://doi.org/10.1016/j.gastrohep.2020.02.017).

## References

1. Fernández-Esparrach G, Gimeno-García A, Ayuso J, Ginès A, Bordas J. Vertebral prosthetic arthrodesis migration to the esophageal lumen: a rare cause of dysphagia. *Endoscopy*. 2007;39 Suppl. 1:E188, <http://dx.doi.org/10.1055/s-2007-966102>.
2. García-Armengol R, Colet-Esquerre S, Teixidor-Rodríguez P, Alamar-Abril M, Cladellas-Ponsa JM, Hostalot-Panisello C, et al. Complicaciones del abordaje anterior en la patología de la columna cervical. *Neurocirugía*. 2007;18:209–20.
3. Acosta-Merida M, Medina-Velázquez R, Marchena-Gómez J, Alonso-Gómez J, Mhaidli H. Disfagia tras artrodesis cervical por migración del material protésico. *Cir Esp*. 2015;93:537–45.