

BRAF, *CTNNB1*, *DDR2*, *EGFR*, *ERBB2*, *ERBB3*, *ERBB4*, *ESR1*, *FBXW7*, *FGFR1*, *FGFR2*, *FGFR3*, *GNA11*, *GNAQ*, *HRAS*, *IDH1*, *IDH2*, *JAK1*, *JAK2*, *JAK3*, *KIT*, *KRAS*, *MAP2K1*, *MAP2K2*, *MET*, *MTOR*, *NOTCH1*, *NRAS*, *PDGFRA*, *PIK3CA*, *PTEN*, *RAF1*, *RET*, *ROS1*, *SMAD4*, *SMO*, *STK11*, and *TP53*. Furthermore, no copy number alterations were detected in *AKT1*, *ALK*, *AR*, *BRAF*, *CCND1*, *CDK4*, *CDK6*, *EGFR*, *ERBB2*, *FGFR1*, *FGFR2*, *FGFR3*, *FGFR4*, *KIT*, *KRAS*, *MET*, *MYC*, *MYCN*, *PDGFRA*, and *PIK3CA*.

The other non-Barrett's associated EAC derive from heterotopic gastric mucosa and is more frequent in males. A third actor to consider is the esophageal gland duct adenoma, located in the lower esophagus, with most published cases being in males between 40 and 60 years old, treated with endoscopic resection and with no recurrence or malignancy during follow up.⁵ It is uncertain whether esophageal gland duct adenoma can be a precursor lesion of adenocarcinoma. Our case had some hyperplastic benign submucosal glands, larger than normally seen, but it is difficult to state if the tumour was originated in such a lesion, although it cannot be completely excluded (Fig. 1H).

In conclusion, it is important to identify these rare EAC arising in the submucosal gland/duct system, since they could have a different etiopathogenesis and carcinogenetic pathway. Little is known about their genetic profile as no genetic study has been performed in the few reported cases. Our case had a poor response to neoadjuvant therapy, and we did not find any mutation in any of the most frequent genes involved in gastric, esophageal or other frequent human adenocarcinomas.

Acknowledgements

We are indebted to the Molecular Biology Core from the Biomedical Diagnostic Center (CDB) of Hospital Clinic for technical support. We also acknowledge the support of the Xarxa Catalana de Bancs de Tumors-XBTC, the Banc de Tumors of the Hospital-Clínic-IDIBAPS, and the support of CERCA Programme/Generalitat de Catalunya.

References

1. Then EO, Lopez M, Saleem S, Gayam V, Sunkara T, Culliford A, et al. Esophageal cancer: an updated surveillance epidemiology

and end results database analysis. *World J Oncol.* 2020;11:55–64, <http://dx.doi.org/10.14740/wjon1254>.

2. Wang S-W, Chang C-S, Wang J, Yeh H-Z. Early adenocarcinoma originating in submucosal gland of thoracic esophagus presenting as submucosal tumor. *Endoscopy.* 2008;40 Suppl. 2:E237–8, <http://dx.doi.org/10.1055/s-2008-1077680>.
3. Tamura H, Saiki H, Amano T, Yamamoto M, Hayashi S, Ando H, et al. Esophageal carcinoma originating in the surface epithelium with immunohistochemically proven esophageal gland duct differentiation: A case report. *World J Gastroenterol.* 2017;23:3928–33, <http://dx.doi.org/10.3748/wjg.v23.i21.3928>.
4. Kim J, Bowlby R, Mungall AJ, Robertson AG, Odze RD, Cherniack AD, et al. Integrated genomic characterization of oesophageal carcinoma. *Nature.* 2017;541:169–75, <http://dx.doi.org/10.1038/nature20805>.
5. Nie L, Wu HY, Shen YH, Fan XS, Sun Q, Huang Q, et al. Esophageal submucosal gland duct adenoma: a clinicopathological and immunohistochemical study with a review of the literature. *Dis Esophagus.* 2017;30:1–6, <http://dx.doi.org/10.1111/dote.12442>.

Karmele Saez de Gordo^a, Jose Guerrero^a, Rosanna Bishop^a, Ivan Archilla^a, Maite Rodrigo^a, Oriol Sendino^{b,e,f,g}, Dulce Momblan^c, Tamara Sauri^{d,e,f}, Pedro Jares^{a,e,f}, Miriam Cuatrecasas^{a,e,f,g,*}

^a Department of Pathology, Hospital Clínic, University of Barcelona, IDIBAPS, Barcelona, Spain

^b Gastroenterology Department, Hospital Clínic, Barcelona, Spain

^c Surgery Department, Hospital Clínic, Barcelona, Spain

^d Oncology Department, Hospital Clínic, Barcelona, Spain

^e Institut d'Investigacions Biomèdiques August Pi i Sunyer (IDIBAPS), Barcelona, Spain

^f Universitat de Barcelona (UB), Barcelona, Catalonia, Spain

^g Centro de Investigación Biomédica en Red de Enfermedades Hepáticas y Digestivas (CIBERehd), Spain

* Corresponding author.

E-mail address: mcuatrec@clinic.cat (M. Cuatrecasas).

0210-5705/ © 2020 Elsevier España, S.L.U. All rights reserved.

Splenosis: An underappreciated cause of gastrointestinal bleeding in splenectomized patients. Case report and literature review



Esplenosis: una causa subestimada de hemorragia gastrointestinal en el esplenectomizado. Caso clínico y revisión literaria

Splenosis is the ectopic splenic tissue autotransplanted following splenectomy or splenic trauma.¹ This tissue may

give rise to a mass or masses located in the peritoneum or extraperitoneally, which may present a difficult differential diagnosis. Occasionally, splenosis may produce abdominal pain, obstruction, and gastrointestinal bleeding.^{1,2}

A 55-year-old male attended the emergency room (ER) for a new episode of melena in July 2018. Previous medical history included a necrotizing pancreatitis in 2003 with a splenic vein thrombosis with collateral circulation as a sign of prehepatic portal hypertension (PPH). In 2007 spleen rupture occurred. Since then, the patient presented several episodes of upper gastrointestinal bleeding (UGIB). They were thought to be secondary to this PPH because on endoscopy an enlarged mucosal fold on the gastric fundus was found to be the source of bleeding recurrently

Table 1 Summary of all cases reviewed.

case	Year of publication	Age (years)/sex	Reason of splenectomy	Time interval from surgery to bleeding (years)	Location	Tc99mHDES (performed yes/no)	Rebleeding ^a	Endoscopic findings	Definitive intervention	Outcome
Basile RM, et al. ⁹	1989	24/M	Traumatic rupture	19	Ileon	NO (Tc99m sulfur colloid study)	NO	EGD x2: No findings	Surgical resection	Survived intervention. No follow up.
Chiarugi M, et al. ¹⁰	1996	65/M	Gaucher disease	29	Greater curvature of the stomach	NO	YES	EGD: Ulcer 10 mm with adherent clot IIB	Surgical resection	Survived intervention. No follow up.
Laszewicz, et al. ¹¹	1997	40/M	NM	NM	Posterior wall of the stomach	NO	YES	EGD: Bluish semipedunculated polyp. Detachable snare.	Surgical resection	Survived intervention. No follow up.
Sikov M, et al. ⁶	2000	48/M	Traumatic rupture	41	Jejunum + colon	YES (but splenosis was not found).	YES	EGD + Colonoscopy: No findings.	Surgical resection	Survived intervention. Several years (not specified) follow up: No rebleeding.
Margari A, et al. ¹	2008	47/M	Traumatic rupture	19	Gastric fundus	NO	NO	EGD: Big clot occupying stomach.	Surgical resection	Survived intervention. No follow up.
Arroja B, et al. ⁷	2011	68/M	Traumatic rupture	30	Greater curvature of the stomach	YES	NO	EGD: Ulcer over elevated formation	Medical treatment ^b	3 weeks follow up: No rebleeding.
Obokhare ID, et al. ¹²	2012	41/M	Gastric varices	3	Colon (splenic flexure)	NO	YES	Colonoscopy: Polypoid ulcerated mass.	Surgical resection	Survived intervention. No follow up.
Alang N ²	2013	54/F	NM	37	Gastric fundus	NO	NO	EGD: Fundic clot.	Surgical resection	Survived intervention. No follow up.
Alvite Canosa ¹³	2013	49/M	Traumatic rupture	28	Gastric fundus	NO	YES	EGD: Fundic erosions. EUS: Perilesional tortuous vessels (varices).	Surgical resection	Survived intervention. 4 months follow up: No rebleeding.

Table 1 (Continued)

case	Year of publication	Age (years)/sex	Reason of splenectomy	Time interval from surgery to bleeding (years)	Location	Tc99mHDES (performed yes/no)	Rebleeding ^a	Endoscopic findings	Definitive intervention	Outcome
Yang K, et al. ¹⁴	2013	42/M	Traumatic rupture	17	Gastric fundus	NO	YES	EGD: Submucosal mass in fundus, bleeding ulcer on top.	Surgical resection	Survived intervention. No follow up.
Leitz EM, et al. ¹⁵	2015	35/M	Traumatic rupture	NM	Small bowel	YES	NO	EGD + Colonoscopy: No findings.	Transarterial embolization	Survived intervention. 9 months follow up: No rebleeding.
Famà F, et al. ⁸	2016	68/M	Traumatic rupture	25	Jejunum	YES	YES	EGD + Colonoscopy + VCE: No findings.	Medical treatment ^b	7 years follow up: No rebleeding.
Reinglas J, et al. ⁴	2016	52/M	Traumatic rupture	38	Gastric fundus	NO	YES	EGD: Fundic clot. EUS: Perforating vessels in the gastric wall, no large varices.	Transarterial embolization	Survived intervention. 8 months follow up: No rebleeding.
Xiao SM, et al. ¹⁶	2017	40/M	Traumatic rupture	10	Colon (splenic flexure) + stomach greater curvature	NO	YES	Colonoscopy: Neoplasia in splenic flexure	Surgical resection	Survived intervention. No follow up.
Arena R, et al. ¹⁷	2018	58/M	Traumatic rupture	30	Ileum	NO	NO	EGD + Colonoscopy: No findings. VCE: Ulcerated lesion in the ileon	Surgical resection	Survived intervention. No follow up.
Moralejo Lozano Ó, et al. (current article)	2020	55/M	Traumatic rupture	11	Gastric fundus	YES	YES	EGD: IGV-1 (EUS confirmed) + Fundic clot.	Surgical resection	Survived intervention. 18 months follow up: No rebleeding.

EGD: Esophagogastroduodenoscopy, EUS: Endoscopic ultrasound, F: Female, IGV-1: Isolated gastric varices type 1, M: Male, NM: Not mentioned, Tc-99m HDES: Technetium (Tc) 99m-labelled heat-denatured erythrocyte scintigraphy, VCE: Videocapsule endoscopy.

^a Rebleeding: recurrent melena episodes or evidence of rebleeding during hospital admission.

^b Medical treatment: intravenous fluids and proton-pump inhibitors (PPI).

(findings were: adherent clot to this fold, or an stomach full of blood with no alternative source). Despite different approaches (cyanoacrylate, aethoxysklerol, or arterial embolization of an active leak depending on the left gastric artery), UGIB episodes continued.

This time, a new endoscopic ultrasound (EUS) revealed a 39 mm rounded, homogeneous, hypoechoic mass adjacent to the gastric fundus, with perforating vessels. A technetium (Tc) 99m-labelled heat-denatured erythrocyte scintigraphy (HDES) detected an uptake area in the gastric fundus. All this information was consistent with a diagnosis of splenosis. Selective cyanoacrylate injection under EUS guidance with disappearance of doppler uptake of the perforating vessels was done. Nevertheless, rebleeding occurred, and surgery was planned: a partial gastrectomy of the fundus was performed. In macroscopic examination, over the external surface of the gastric wall multiple solid nodular brown-violet formations are found measuring between 3 and 32 mm, corresponding in the microscopic examination to splenic tissue including white and red pulp.

After an eighteen-month follow up, no rebleeding has occurred, anaemia is solved and stable, no more transfusions or iron supplements are required, and the patient is back to an active life.

Previous published literature has been reviewed. We focused our interest on gastrointestinal bleeding due to splenosis. We conducted a search through PubMed using the MeSH terms "splenosis" and "bleeding" or "hemorrhage", as well as through the references of the articles found. Language was limited to English. Fifteen previously cases were found, published between 1989 and 2019 (Table 1).

Age ranged from 24 to 68 years (mean: 49.13 years; median: 48.50 years), mostly male (93.75%). Spleen rupture (75%) was the main reason for splenectomy. The interval time from splenectomy to diagnosis ranged from 3 to 41 years (mean: 24.07 years; median: 26.50 years). Most frequent location was the stomach (62.50%), followed by small intestine (31.25%) and colon (18.75%). This data contrast with the reported most frequent location of abdominal splenosis which are greater omentum and serosal surface of small intestine.³ Recurrence of bleeding during hospital admission was common (62.50%).

Diagnosing splenosis can be challenging. Several imaging methods can be helpful such as abdominal ultrasonography, computed tomography (CT), or standard magnetic resonance imaging (MRI) but a lack of specificity is present. Ferumoxide-enhanced MRI, Tc-99m sulphur colloid scintigraphy,^{3,4} or single-photon emission computed tomography (SPECT)⁵ have been described. However, technetium (Tc) 99m-labelled HDES is generally accepted as the most sensitive and specific test.³ It is to be noted that just in 37.50% of the cases HDES was performed, with the splenosis often being diagnosed intraoperatively. This could relate to a low grade of suspicion; but also, the clinical situation of the patient often required urgent surgery.

Definitive treatment for most cases was surgical resection (75%). However, conservative approach (12.50%) and arteriography (31.25%) have also been described. Arteriography was used in 5 cases, not detecting the bleeding source in 2 of them. When embolization was performed (3 cases), it was definitive just in two of them. In 56.25% of the cases no follow-up was reported. In those with informed follow-up,

it was generally short, with only three cases (including ours) overcoming one or more years.^{6,8}

As a conclusion, gastrointestinal bleeding due to splenosis occurs more commonly many years after splenectomy, mostly in males, with the gastric fundus as the most common location. It is frequently recurrent, and surgical resection is often required, but other approaches such as transarterial embolization^{4,15} or conservative treatment^{7,8} have also been reported.

Funding

The present investigation has not received specific aid from agencies from the public sector, commercial sector or non-profit entities.

References

- Margari A, Amoroso M, D'Abbicco D, Notarnicola A, Epifania B. Massive gastrointestinal bleeding due to splenotic nodule of the gastric wall. A case report. *Chir Ital.* 2008;60:863–5.
- Alang N. Splenosis: an unusual cause of massive gastrointestinal bleeding. *R I Med J.* 2013;96:48–9.
- Guan B, Li XH, Wang L, Zhou M, Dong ZW, Luo GJ, et al. Gastric fundus splenosis with hemangioma masquerading as a gastrointestinal stromal tumor in a patient with schistosomiasis and cirrhosis who underwent splenectomy: a case report and literature review. *Medicine (Baltimore).* 2018;97:e11461.
- Reinglas J, Perdrizer K, Ryan SE, Patel RV. Splenosis involving the gastric fundus, a rare cause of massive upper gastrointestinal bleeding: a case report and review of the literature. *Clin Exp Gastroenterol.* 2016;9:301–5.
- Schillaci O, Filippi L, Danieli R, Simonetti G. Single-photon emission computed tomography/computed tomography in abdominal diseases. *Semin Nucl Med.* 2007;37:48–61.
- Sikov WM, Schiffman FJ, Weaver M, Dyckman J, Shulman R, Torgan P. Splenosis presenting as occult gastrointestinal bleeding. *Am J Hematol.* 2000;65:56–61.
- Arroja B, Almeida N, Macedo CR, Moreira AP, Oliveira P, Tomé L, et al. Gastric splenosis: a rare cause of digestive bleeding. *Rev Esp Enferm Dig.* 2011;103:377–8.
- Famà F, Giacobbe G, Cintolo M, Gioffré-Florio M, Pallio S, Consolo P. A Lower gastrointestinal bleeding due to a post-traumatic splenosis: "wait and see" represents a feasible attitude: a case report. *Medicine (Baltimore).* 2016;95:e3555.
- Basile RM, Morales JM, Zupanec R. Splenosis, a cause of massive gastrointestinal hemorrhage. *Arch Surg.* 1989;124:1087–9.
- Chiarugi M, Martino MC, Bucciatti P, Goletti O. Bleeding gastric ulcer complicating splenosis in type 1 Gaucher's disease. *Eur J Surg.* 1996;162:63–5.
- Laszewicz W, Baniukiewicz A, Wroblewski E. Upper gastrointestinal hemorrhage secondary to ectopic spleen. *Endoscopy.* 1997;29:56–7.
- Obokhare ID, Beckman E, Beck DE, Whitlow CB, Margolin DA. Intramural colonic splenosis: a rare case of lower gastrointestinal bleeding. *J Gastrointest Surg.* 2012;16:1632–4.
- Alvite Canosa M, Castro Ortiz E, Alonso Fernandez L, Montoto Santomé P, Monjero Ares I, Álvarez Gutiérrez A, et al. Upper gastrointestinal bleeding due to gastric splenosis. *Gastroenterol Hepatol.* 2013;36:59–61.
- Yang K, Chen XZ, Liu J, Wu B, Chen XL, Hu JK. Splenosis in gastric wall mimicking gastrointestinal stromal tumor. *Endoscopy.* 2013;45 Suppl. 2 UCTN:E82–3.
- Leitz EM, Kwan SW. Splenosis: a rare cause of gastrointestinal bleeding successfully treated with transarterial embolization. *Clin J Gastroenterol.* 2015;8:126–9.

16. Xiao SM, Xu R, Tang XL, Ding Z, Li JM, Zhou X. Splenosis with lower gastrointestinal bleeding mimicking colonic gastrointestinal stromal tumour. *World J Surg Oncol*. 2017;15:78.
17. Arena R, Gasperoni S, Lisotti A, Petrini CAA, Brancaccio ML, Triossi O, et al. An unusual cause of gastrointestinal bleeding and intestinal obstruction. *Turk J Gastroenterol*. 2018;29:365–6.

Óscar Moralejo Lozano^{a,*}, Marta Aparicio Cabezudo^a,
Marta Cruz Aparicio^a, Ana Caso Viesca^b,
Michel Colmenares Bulgheroni^a,
Adrián Joaquín Barraón Masa^a,
José Miguel Esteban López-Jamar^a

^a Gastroenterology and Hepatology Department, Hospital Clínico San Carlos, 28040 Madrid, Spain

^b Pathology Department, Hospital Clínico San Carlos, 28040 Madrid, Spain

Corresponding author.

E-mail address: oscarmoralejo@gmail.com

(Ó. Moralejo Lozano).

0210-5705/ © 2020 Elsevier España, S.L.U. All rights reserved.

Tocilizumab as a possible cause of ischemic colitis[☆]



Tocilizumab como posible causa de colitis isquémica

In December 2019, a novel coronavirus, called SARS-CoV-2, was isolated as a causative agent of a new form of pneumonia that has spread globally since then and was subsequently renamed COVID-19 by the World Health Organization.¹ According to data from the Spanish Ministry of Health, as of 1 May 2020, the number of cases diagnosed by PCR in Spain surpassed 215,000 and the number of deaths stood at around 25,000, representing a mortality rate of 11.6%.²

Some patients experience cytokine release syndrome. Interleukin-6 (IL-6) is the key molecule in this cytokine storm.³ Tocilizumab, a humanised recombinant monoclonal antibody, acts against the IL-6 receptor. For that reason, it has come to be used in patients with serious COVID-19 and elevated IL-6. Despite the apparent benefits reported, the possible adverse effects of this agent should be borne in mind. We report the case of a patient treated with tocilizumab for serious COVID-19 who presented signs and symptoms consistent with segmental ischaemic colitis.

A 59-year-old man was admitted to the intensive care unit for bilateral pneumonia due to SARS-CoV-2, complicated

by moderate to severe acute respiratory distress syndrome (ARDS) requiring prolonged orotracheal intubation. Notable elements of his medical history were hypertension and ischaemic cardiomyopathy, for which he underwent revascularisation in February 2020 and was on dual antiplatelet therapy. After three days with boluses of methylprednisolone, the patient's condition worsened, with unfavourable laboratory and radiological test results, for which a single dose of 600 mg of intravenous tocilizumab was prescribed. Ten days following administration of this drug, the patient started to have episodes of haematochezia which required transfusion of four units of packed red blood cells and one unit of platelets (two units of packed red blood cells approximately every 48–72 h) due to the onset of multifactorial anaemia, as he reached haemoglobin levels of 7.2 g/dl.

He underwent a colonoscopy 24 h after the first episode of haematochezia. The procedure revealed digested blood debris (with no active bleeding) up to the hepatic flexure and signs in the mucosa of ischaemic colitis with two ulcers and an adhered clot 55–65 cm from the external anal margin (Fig. 1). This colonoscopy was complete, although ileoscopy was not performed. A gastroscopy showed several gastric ulcers measuring around a millimetre suggestive of acute gastric mucosa lesions with no blood debris and no signs of active bleeding. In view of the endoscopic findings and the patient's context, he was put on digestive rest with parenteral nutrition and broad-spectrum empirical antibiotic

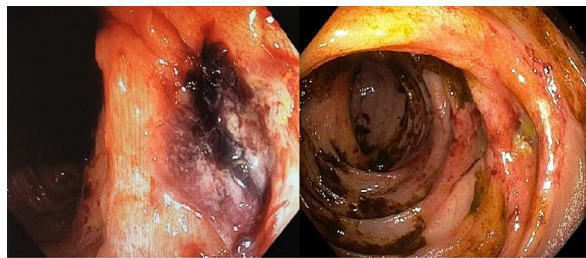


Figure 1 Impairment due to ischaemic colitis: on the left, segmental mucosal impairment with an ulcerated lesion; on the right, colonoscopy after two weeks showing an ulcer with a fibrinated base.

[☆] Please cite this article as: Forneiro Pérez R, Dabán López P, Zurita Saavedra MS, Hernández García MD, Mirón Pozo B. Tocilizumab como posible causa de colitis isquémica. *Gastroenterol Hepatol*. 2020. 2021;44:373–374.