



## ORIGINAL ARTICLE

# Successful cholangioscopic electrocoagulation for biliary papillomatosis: Report covering six cases (with video)



Chuncheng Wu<sup>a,◇</sup>, Juliana F. Yang<sup>b,◇</sup>, Qiongying Zhang<sup>a</sup>, Wei Liu<sup>a</sup>, Ke Liao<sup>a</sup>, Bing Hu<sup>a,\*</sup>

<sup>a</sup> Department of Gastroenterology, West China Hospital, Sichuan University, China

<sup>b</sup> Department of Internal Medicine, Division of Digestive and Liver Diseases, The Vanderbilt University Medical Center, Nashville, TN, USA

Received 18 September 2020; accepted 21 December 2020

## KEYWORDS

Cholangioscopic;  
Electrocoagulation;  
Biliary papillomatosis

## Abstract

**Background:** Biliary papillomatosis is a rare type of papillomatosis. Depending on the location of the disease, radical surgical resection or liver transplants are the treatment of choice. These radical surgical options may be unrealistic in patients who are not surgical candidates or who are unwilling to consider surgery.

**Aims:** To evaluate the effectiveness of endoscopic electrocoagulation for the biliary papillomatosis.

**Methods:** In this case series, we report six patients with unresectable biliary papillomatosis who underwent cholangioscopic electrocoagulation using needle knife and their clinic follow up information.

**Results:** After patients received cholangioscopy with electrocoagulation of the residual biliary papilloma, the daily T-tube drainage volume increased to 200–400 ml with improvement in the drainage content and significant relief of clinical symptoms, such as jaundice and abdominal pain.

**Conclusion:** This method of using electrocoagulation to directly target and destroy tumor tissue is a safe and effective alternative for those with unresectable disease, and this method has shown to enhance T-tube drainage volume and improve patients' overall clinical symptoms.

© 2021 Elsevier España, S.L.U. All rights reserved.

\* Corresponding author.

E-mail address: [hubingnj@163.com](mailto:hubingnj@163.com) (B. Hu).

◇ Chuncheng Wu and Juliana F. Yang are co-first authors.

**PALABRAS CLAVE**Colangioscopia;  
Electrocoagulación;  
Papilomatosis biliar**Electrocoagulación colangioscópica exitosa para la papilomatosis biliar: Informe de 6 casos (con video)****Resumen**

**Antecedentes:** La papilomatosis biliar es un tipo raro de papilomatosis. Dependiendo de la localización de la enfermedad, la resección quirúrgica radical o los trasplantes de hígado son el tratamiento de elección. Estas opciones quirúrgicas radicales pueden ser poco realistas en pacientes que no son candidatos a la cirugía o que no están dispuestos a considerarla.

**Objetivos:** Evaluar la eficacia de la electrocoagulación endoscópica para la papilomatosis biliar.

**Métodos:** En esta serie de casos, informamos de 6 pacientes con papilomatosis biliar irresecable que fueron sometidos a electrocoagulación colangioscópica mediante bisturí de aguja, y de su información de seguimiento clínico.

**Resultados:** Después de que los pacientes recibieran la colangioscopia con electrocoagulación del papiloma biliar residual, el volumen de drenaje diario del tubo en T aumentó a 200-400 ml con mejora del contenido del drenaje y alivio significativo de los síntomas clínicos, como la ictericia y el dolor abdominal.

**Conclusión:** Este método de uso de la electrocoagulación para apuntar directamente y destruir el tejido tumoral es una alternativa segura y eficaz para aquellos con enfermedad no resecable, y este método ha demostrado mejorar el volumen de drenaje del tubo T y mejorar los síntomas clínicos generales de los pacientes.

© 2021 Elsevier España, S.L.U. Todos los derechos reservados.

**Introduction**

Biliary papillomatosis (BP) is a rare type of papillomatosis that was initially described by Chappet in 1894.<sup>1,2</sup> The etiology and pathogenesis remains unknown.<sup>3</sup> This rare disease entity is characterized by multiple papillary (villous) excrescences producing blood, mucous and cell debris leading to dilation of the bile duct.<sup>2,4</sup> BP often occurs in middle-aged men with a male-to-female ratio of 2:1.<sup>3,5-7</sup> The initial diagnosis of BP is challenging due to its none-specific clinical presentations of jaundice, recurrent cholangitis, abdominal pain, and laboratory tests which often mimic choledocholithiasis.<sup>6,8</sup> It is imperative that BP receives prompt diagnosis as it carries high mortality rate and malignant transformation in approximately 35–64% of the cases in addition to septic complications and progression from biliary cirrhosis to liver failure.<sup>2,5,9-11,8,12,17</sup>

Modern cross-sectional image studies are often inadequate in making conclusive diagnosis since these modalities often show bile duct filling defects or choledocholithiasis.<sup>2,10,13-15</sup> However, recent advancements in endoscopic retrograde cholangiopancreatography (ERCP), cholangioscopy and intra-operative ultrasound have become important adjuncts in making the elusive BP diagnosis and in determining resectability.<sup>8,16</sup> Depending on the location of the disease, radical surgical resection or liver transplants are the treatment of choice.<sup>17</sup> These radical surgical options may be unrealistic in patients who are not surgical candidates or who are unwilling to consider surgery. In this group of patients alternate treatment options such as local ablative procedures, palliative stenting and drainage may be feasible. These modalities can be performed with ERCP or cholangioscopy.<sup>11,13,18,19</sup>

In this case series, we report six patients with unresectable BP who underwent cholangioscopic electrocoagulation using needle knife and their clinic follow up information.

**Methods**

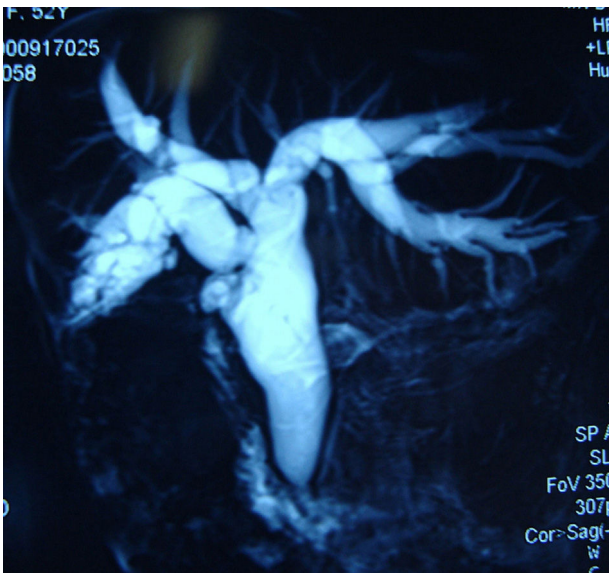
Six patients with histological diagnosis of BP were treated with cholangioscopic electrocoagulation at West China Medical Center (Sichuan, PR China) from October 2011 to January 2014. Patient details are summarized in [Table 1](#). All six patients showed both intrahepatic and extrahepatic dilations on both CT and MRI ([Fig. 1](#)). Patient 1 and patient 2 underwent pre-operative ERCP with characteristic finding of the classic “fish-eye appearance” at the ampulla of Vater ([Fig. 2](#)). Subsequent cholangioscopy showed persistent intrahepatic and extrahepatic biliary dilations and irregular filling defects despite vigorous washing ([Fig. 3A](#)). These areas underwent extensive bile duct biopsy under fluoroscopy ([Fig. 3B](#)). The biopsy specimens showed benign papillary adenomas of biliary type without dysplasia in histopathologic examination, confirming the diagnosis of BP ([Fig. 4](#)).

All six patients fixed T-tube (at least 20 Fr) drainage post-operation. The daily bile flow was between 50 ml and 150 ml. Mucous was found in all the drainage content and serum bilirubin remained persistently elevated. Cholangioscopy with electrocoagulation (VIO 200S, ERBE, German. Endo cut Q mode, coagulation current, 40 W) of the residual papilloma with high frequency electric needle knife (Olympus, Japan) was performed in 6–8 weeks post-operation (Video 1). At the beginning of cholangioscopy, we pulled out the T-tube, the cholangioscope (Fuji, Japan) went through the sinus tract formed by T-tube into the common bile

**Table 1** Details of patients with biliary papillomatosis.

No.	Sex/age (years)	Clinical presentation	Tumor location	ERCP		Treatment	Times of electrocoagulation	Complication after electrocoagulation	Drainage volume of T tube (ml) <sup>a</sup>	Recurrence	Follow-up
				Mucus from papilla	Filling defect						
1	M/65	Jaundice Cholangitis	Both IHD	Yes	Yes	Left hepatectomy	3	Fever	100 → 200	No	8 months (died of pulmonary infection)
2	M/67	Epigastric Pain jaundice	Both IHD	N/A	N/A	Left hepatectomy	4	No	100 → 400	No	5 years (alive)
3	F/58	Pancreatitis Jaundice	Both IHD	Yes	Yes	Cholecystectomy	4	Biliary bleeding	50 → 200	Yes cholangitis	5 years (alive)
4	M/68	Jaundice	Both IHD	N/A	N/A	CBD resection	3	No	50 → 150	No	4 years (alive)
5	F/70	Jaundice Cholangitis	Both EHD IHD	N/A	N/A	Hepatico- jejunostomy Left hepatectomy	2	Biliary bleeding	150 → 350	Yes cholangitis	3 years (alive)
6	M/72	Jaundice Cholangitis	Both IHD	N/A	N/A	Wedge excision of right lobe	4	No	100 → 250	No	3 years (alive)

<sup>a</sup> Drainage volume of T tube before/after electrocoagulation. IHD, intrahepatic duct; EHD, extrahepatic duct; CBD, common bile duct; N/A, not available.



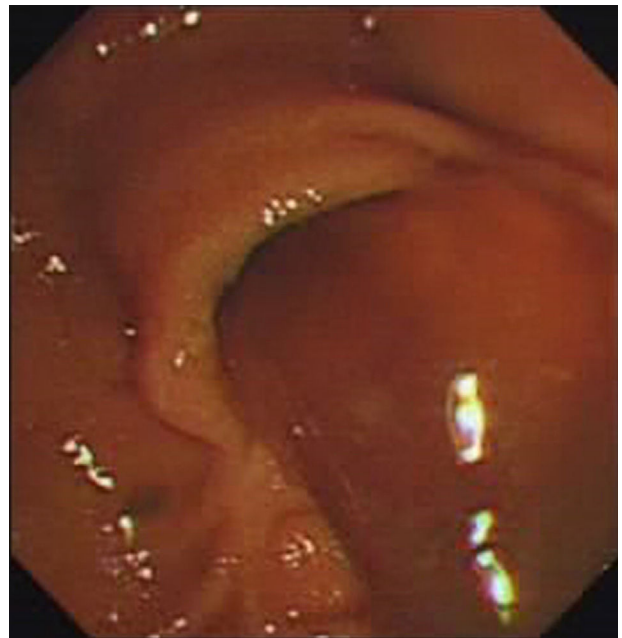
**Figure 1** MRI showed both intrahepatic and extrahepatic dilations.

duct. As usual, T-tube drainage was replaced post therapy and another cholangioscopic treatment was performed one week after endoscopic treatment. The maximum numbers of endoscopic treatments was four times.

## Results

After patients received cholangioscopy with electrocoagulation of the residual biliary papilloma, the daily T-tube drainage volume increased to 200–400ml with improvement in the drainage content and significant relieve clinic symptoms, such as jaundice and abdominal pain. However, patient No.1 developed fever of 101.3 °F (38.5 °C) three days post-operative that was conservatively treated. Patient No. 3 and No. 5 developed a small amount of biliary bleeding that spontaneously resolved without treatment.

These patients were followed for three to five years. Patient Nos. 2, 4 and 6 did not have any recurrent jaundice

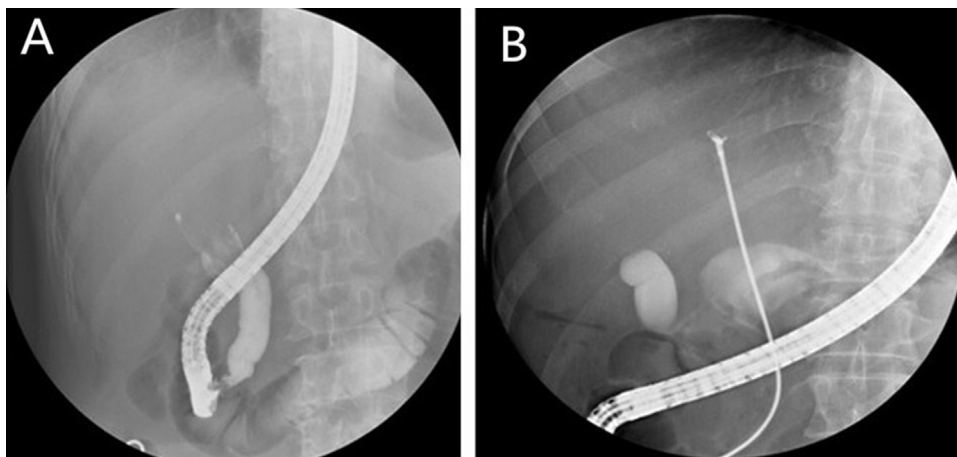


**Figure 2** ERCP showed the classic “fish-eye appearance” at the ampulla of Vater and excessive mucous discharge from the papilla.

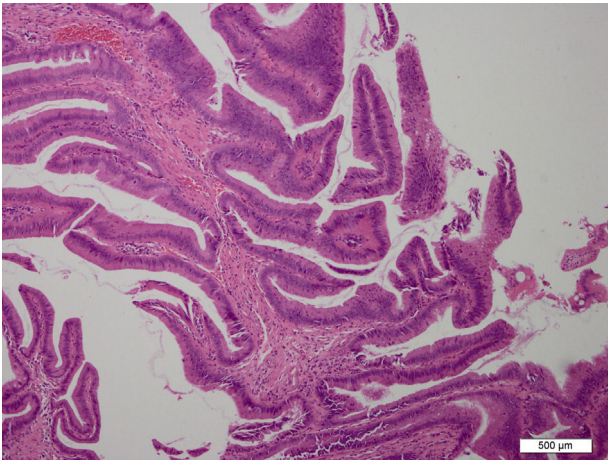
or abdominal pain. Patient No. 3 and No. 5 developed recurrent cholangitis one year post cholangioscopic treatment. Patient No. 1 was followed for 8 month prior to succumb to severe pulmonary infections.

## Discussion

Following advancement in endoscopy, ERCP and cholangioscopy are now the modality of choice in making the BP diagnosis.<sup>20,21</sup> The characteristic findings of BP during ERCP include excessive mucous discharge observed from the papilla in addition to the multiple filling defects found during cholangioscopy.<sup>22,23</sup> Diagnosis of BP can often be made by bile duct biopsy.



**Figure 3** (A) Cholangioscopy showed persistent biliary dilations and irregular filling defects despite vigorous washing. (B) Bile duct biopsy was performed under fluoroscopy.



**Figure 4** The biopsy specimens showed benign papillary adenomas.

BP is in fact premalignant disease with high malignancy potential and high rate of recurrence.<sup>2,5,8,9</sup> Therefore, surgical resection or liver transplant are often recommended due to its high malignant transformation and diffuse pattern of the disease.<sup>10,24</sup> Recently, new approaches such as percutaneous cholangioscopic laser ablation, iridium-192 intraluminal therapy, and photodynamic therapy and argon plasma coagulations are shown to improve survival.<sup>25–28</sup>

Here, we report that all six patients had diffuse BP involving bilateral hepatic lobes, which make radical surgical resection impossible. Among them, four patients that underwent partial hepatectomy in lobes with higher disease burden should be considered as tumor reduction surgery, therefore there were still residual diseases in the remaining livers. These patients all underwent post-operative cholangioscopic electrocoagulation in effort to destroy the residual tumor, to decrease mucous secretion, to enhance bile drainage, and to improve liver function as well as clinical symptoms.

During the operation of cholangioscopic electrocoagulation within the bile duct, it is vital that the tip of the needle knife is close to or gently touch the target lesion, do not press the lesion or bile duct wall with force as this maneuver will result in increased risk of bleeding and biliary tract perforation. Electrocoagulation current can be used to destroy tumor tissue. When working, sparks can be seen at the tip of the needle knife under endoscope. As long as the spark contacts the lesion, the lesion can be destroyed. Alternative method such as argon plasma coagulation (APC) can be also considered, but APC does not fit into the cholangioscopy and the water used during cholangioscopy procedures will create large amount of bubbles that would affect procedure.

## Conclusion

This cases series demonstrate that cholangioscopic electrocoagulation is a feasible therapeutic option for patients who are not candidates for surgical intervention of biliary papillomatosis. This method of using electrocoagulation to directly target and destroy tumor tissue is a safe and effective alternative for those with unresectable disease, and this method has shown to enhance T-tube drainage volume and

improve patients' overall clinical symptoms. Further studies are needed to further investigate the safety and efficacy of this method in the treatment of biliary papillomatosis.

## Author contributions

Find the patient and get the idea: Chuncheng Wu, MD; Bing Hu, MD.

Performed the treatment: Chuncheng Wu, MD; Bing Hu, MD; Qiongying Zhang, RN.

Collected the information the patient: Chuncheng Wu, MD; Qiongying Zhang, RN; Ke Liao, MS.

Collected the figure of the patient: Chuncheng Wu, MD; Qiongying Zhang, RN; Ke Liao, MS.

Discussed the diagnose and treatment for the patient: Chuncheng Wu, MD; Juliana F. Yang, MD; Qiongying Zhang, RN; Wei Liu, MD; Bing Hu, MD.

Analysis and interpretation of the data of the patient: Chuncheng Wu, MD; Juliana F. Yang, MD; Qiongying Zhang, RN; Wei Liu, MD; Bing Hu, MD.

Drafted and revised the article: Chuncheng Wu, MD; Juliana F. Yang, MD; Ke Liao, MS; Bing Hu, MD.

Final approval of the article: Chuncheng Wu, M.D.; Juliana F. Yang, M.D.; Qiongying Zhang, RN; Wei Liu, M.D.; Bing Hu, M.D.; Ke Liao, M.S.

## Conflict of interest

All authors have no conflicts of interest to disclose.

## Acknowledgement

The authors want to thank Sichuan Province Science and Technology Department (China) (2018SZ0134) for their support. Financial disclosure

All authors have no financial relationships relevant to this article to disclose.

## Appendix A. Supplementary data

Supplementary data associated with this article can be found, in the online version, at [doi:10.1016/j.gastrohep.2020.12.012](https://doi.org/10.1016/j.gastrohep.2020.12.012).

## References

1. Chappet V. Cancer epithelial primitif au canal choledoque. *Lyon Med.* 1894;76:145–57.
2. Gu CC, Lin Y, Jin HS, Jian ZX. Biliary papillomatosis with malignant transformation: a case report and review of the literature. *Oncol Lett.* 2015;10:3315–7.
3. Hsu YQ. Biliary papillomatosis. *Hong Kong Med J.* 2014;20:168, e3.
4. Nakajima T, Kondo Y, Miyazaki M, Okui K. A histopathologic study of 102 cases of intrahepatic cholangiocarcinoma: histologic classification and modes of spreading. *Hum Pathol.* 1988;19:1228–34.
5. Lee SS, Kim MH, Lee SK, Jang SJ, Song MH, Kim KP, et al. Clinicopathologic review of 58 patients with biliary papillomatosis. *Cancer.* 2004;100:783–93.

6. Adioui T, Seddik H, Baba H, Slioui B, Ali AA, Hamdi FZ, et al. Successful surgical treatment of extrahepatic biliary papillomatosis diagnosed with endoscopic retrograde cholangiopancreatography: a case report. *J Med Case Rep.* 2014;8:148.
7. Vassiliou I, Kairi-Vassilatou E, Marinis A, Theodosopoulos T, Arkadopoulos N, Smyrniotis V. Malignant potential of intrahepatic biliary papillomatosis: a case report and review of the literature. *World J Surg Oncol.* 2006;4:71.
8. Sotiropoulos GC, Lang H, Nadalin S, Holtmann G, Dirsch O, Broelsch CE. Papillomatosis confined to the distal biliary tract – a rare cause of obstructive jaundice: report of a case. *Surg Today.* 2003;33:781–4.
9. Holtkamp W, Reis HE. Papillomatosis of the bile ducts: papilloma–carcinoma sequence. *Am J Gastroenterol.* 1994;89:2253–5.
10. Yeung YP, AhChong K, Chung CK, Chun AYW. Biliary papillomatosis: report of seven cases and review of English literature. *J Hepatobiliary Pancreat Surg.* 2003;10:390–5.
11. Li Z, Gao C, Zhang X, He Z, Niu W. Intrahepatic biliary papillomatosis associated with malignant transformation: report of two cases and review of literature. *Int J Clin Exp Med.* 2015;8:21802–6.
12. Taguchi J, Yasunaga M, Kojiro M, Holtmann G, Dirsch O, Broelsch CE. Intrahepatic and extrahepatic biliary papillomatosis. *Arch Pathol Lab Md.* 1993;117:944–7.
13. Parsi MA. Biliary papillomatosis: diagnosis with direct peroral cholangioscopy. *Gastrointest Endosc.* 2015;81:231.
14. Iwasaki Y, Shimoda M, Furihata T, Rokkaku K, Kubota K. Biliary papillomatosis arising in a congenital choledochal cyst: report of a case. *Surg Today.* 2002;32:1019–22.
15. Lee PS, Auyeung KM, To KF, Chan YI. Biliary papillomatosis complicating recurrent pyogenic cholangitis. *Clin Radiol.* 2001;56:591–3.
16. Kim YS, Myung SJ, Kim SY, Kim HJ, Kim JS, Nam SW, et al. Biliary papillomatosis: clinical, cholangiographic and cholangioscopic findings. *Endoscopy.* 1998;30:763–7.
17. Beavers KL, Fried MW, Johnson MW, Zacks SL, Gerber DA, Weeks SM, et al. Orthotopic liver transplantation for biliary papillomatosis. *Liver Transpl.* 2001;7:264–5.
18. Donnellan F, Swan MP, May GR, Kortan PP. Biliary papillomatosis diagnosed with mother–daughter narrow-band imaging (NBI) cholangioscopy. *Endoscopy.* 2011;43:E86–7.
19. Itoi T, Sofuni A, Itokawa F, Tsuchiya T, Kurihara T. Evaluation of proral videocholangioscopy using narrow-band imaging for diagnosis of intraductal papillary neoplasm of the bile duct. *Dig Endosc.* 2009;21 Suppl. 1:103–7.
20. Kim YS, Myung SJ, Lee SK, Kim MH. Role of percutaneous transhepatic cholangioscopy in biliary papillomatosis: can it change treatment modality? *Gastrointest Endosc.* 1998;47:563–4 [letter].
21. D’Abrigeon G, Blanc P, Bauret P, Diaz D, Durand L, Michel J, et al. Diagnostic and therapeutic aspects of endoscopic retrograde cholangiography in papillomatosis of the bile ducts: analysis of five cases. *Gastrointest Endosc.* 1997;46:237–41.
22. Caroli J. Disease of the intrahepatic biliary tree. *Clin Gastroenterol.* 1973;2:147–61.
23. Kim HJ, Kim MH, Lee SK, Yoo KS, Park ET, Lim BC, et al. Mucin-hypersecreting bile duct tumor characterized by a striking homology with an intraductal papillary mucinous tumor (IPMT) of the pancreas. *Endoscopy.* 2000;32:389–93.
24. Yeh TS, Tseng JH, Chiu CT, Liu NJ, Chen TC, Jan YY, et al. Cholangiographic spectrum of intraductal papillary mucinous neoplasm of the bile ducts. *Ann Surg.* 2006;244:248–53.
25. Baughman SM, Bishoff JT, Zimmerman MK, Carter MR, et al. Case report: serial percutaneous cholangioscopy with laser ablation for the management of locally recurrent biliary intraductal papillary mucinous tumor. *J Gastrointest Surg.* 2005;9:215–8.
26. Gunven P, Gorsetman J, Ohlsen H, Ruden BI, Lundell G, Skoog L, et al. Six-year recurrence free survival after intraluminal iridium-192 therapy of human bilobar papillomatosis: a case report. *Cancer.* 2000;89:69–73.
27. Bechmann LP, Higar P, Frilling A, Schumacher B, Baba HZ, Gerkern G, et al. Successful photodynamic therapy for biliary papillomatosis: a case report. *World J Gastroenterol.* 2008;14:4234–7.
28. Jazrawi SF, Nguyen D, Barnett C, Tang SJ. Novel application of intraductal argon plasma coagulation in biliary papillomatosis (with video). *Gastrointest Endosc.* 2009;69N2:372–4.