



IMAGE OF THE MONTH

Small bowel obstruction caused by chestnut ingestion



Obstrucción del intestino delgado causada por la ingestión de una castaña

Andrea Barberis*, Umberto Rossi, Marco Filauro

Ente Ospedaliero Ospedali Galliera, Genova, Liguria, Italy

We present a case of an 80-year-old man with mental retardation was seen on January 2020 in our emergency department for increase in time of abdominal pain and vomiting. He has no history of abdominal surgery and he said that he ate a seasonal soup 12h earlier. Clinical examination demonstrated abdominal distension with tenderness. Abdominal X-ray showed small bowel loops distension (arrows) with absence of free abdominal air (Fig. 1). Abdominal CT scan axial (Fig. 2) and coronal (Fig. 3) reconstruction demonstrated small bowel loops distension (arrows) and a 28mm oval formation in a distal jejunal bowel loop, with air inclusions that gave it a "brain aspect" (arrowhead). Patient was managed conservatively with a nasogastric tube. 24h later he had an abundant defecation in the context of which a whole chestnut with its shell was found (Fig. 4).

Chestnuts are one of the winter season foods in Italy and it can be among the ingredients of the soups, after their shell removal and cooking. Most cases of food bolus bowel obstruction are due to meat and fish bones, less frequent are reported case due to fruits; another type of intestinal obstruction from ingestions to keep in mind and exclude may be due to trichophagia.¹ In literature only few cases of bowel obstruction due to intact chestnuts are reported^{2,3}; the peculiarity of this case is related to the fact that the foreign body, initially blocked in the jejunum, mobilized without

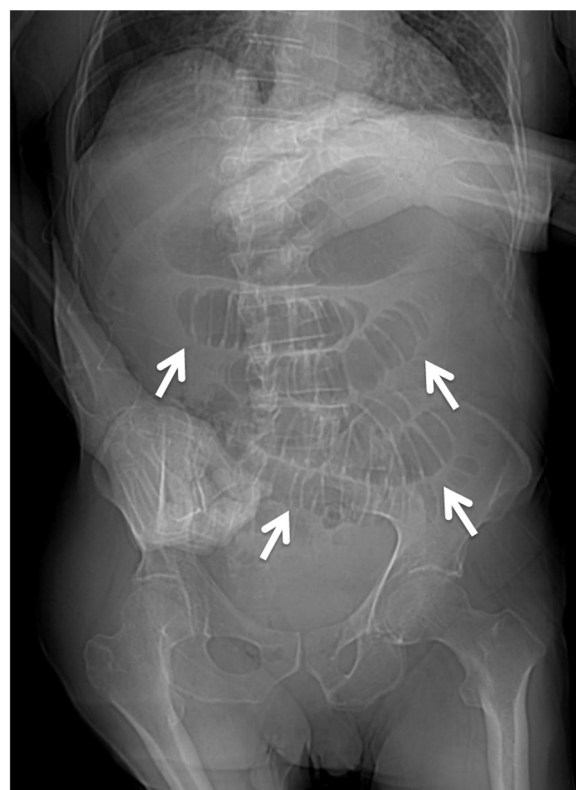


Figure 1 Abdominal X-ray showing small bowel loops distension (arrows) with absence of free abdominal air.

* Corresponding author.

E-mail address: andrea.barberis@galliera.it (A. Barberis).

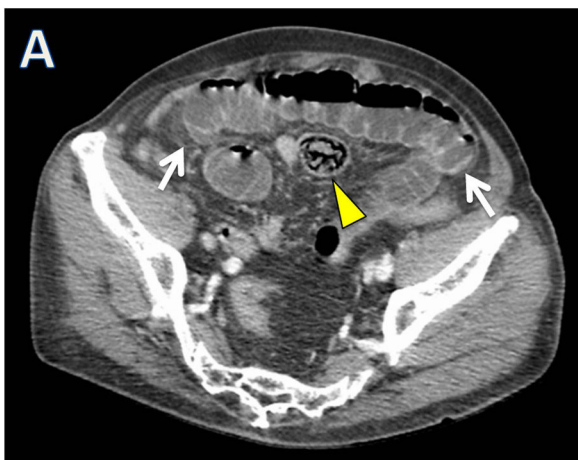


Figure 2 Abdominal CT axial and coronal showing small bowel loops distension (arrows) and an oval formation in a distal jejunal bowel loop.

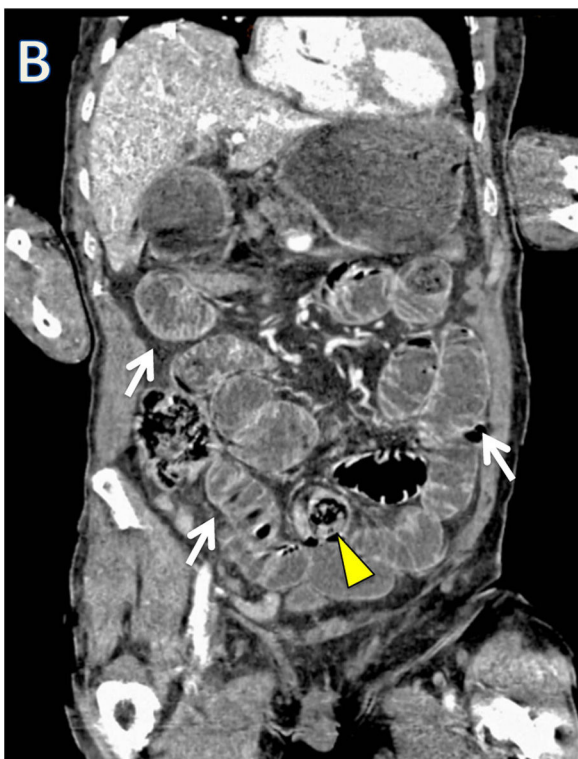

Figure 3 Abdominal CT axial and coronal showing small bowel loops distension (arrows) and an oval formation in a distal jejunal bowel loop.

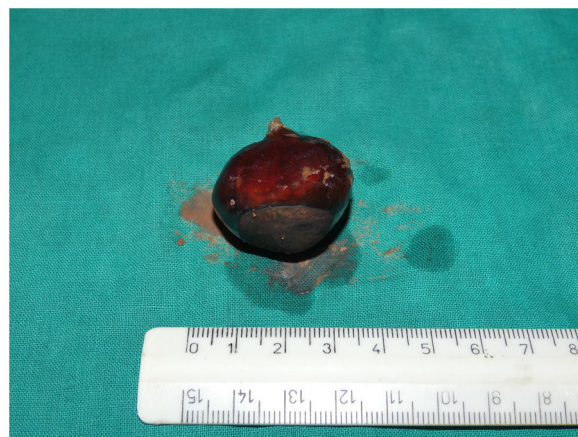

Figure 4 The foreign body (a chestnut) evacuated by the patient.

any therapeutic measure and, despite its size, passed the ileocecal valve that is frequent site of obstruction.

Patients with bowel obstruction due to food bolus have to be careful interview on their meal history; treatment depends on symptoms, grade of bowel obstruction and possible damage of bowel wall.

References

1. Gallego-Pérez B, Martínez-Crespo JJ, Garcia-Belmonte D. A trichobezoar causing intestinal obstruction in an adolescent girl. *Gastroenterol Hepatol.* 2014;37:545–6, <http://dx.doi.org/10.1016/j.gastrohep.2014.02.002>.
2. Satake R, Chinda D, Shimoyama T, Satake M, Oota R, Yamai K, et al. Repeated small bowel obstruction caused by chestnut ingestion without the formation of phytobezoars. *Intern Med.* 2016;55:1565–8, <http://dx.doi.org/10.2169/internalmedicine.55.6811>.
3. Ravindra RK, Das A, Chew GL, Daniel E. Small bowel obstruction with multiple perforations post chestnut ingestion. *BMJ Case Rep.* 2019;12, <http://dx.doi.org/10.1136/bcr-2018-227999>.