



Case report

Microscopic polyangiitis and antiphospholipid syndrome. An uncommon association [☆]



Víctor Jaime López-Villegas ^{a,b}, Diego Alejandro Medina-Morales ^{a,b},
Lina María Saldarriaga-Rivera ^{a,c,d,*}

^a Grupo de investigación en Medicina Interna, Universidad Tecnológica de Pereira, Pereira, Colombia

^b Especialización en Medicina Interna, Universidad Tecnológica de Pereira, Pereira, Colombia

^c Medicina Interna y Reumatología, Universidad Tecnológica de Pereira, Pereira, Colombia

^d Departamento de Medicina Interna y Reumatología, Clínica Los Rosales, Pereira, Colombia

ARTICLE INFO

Article history:

Received 19 June 2018

Accepted 10 August 2018

Available online 23 November 2019

Keywords:

Microscopic polyangiitis

Antiphospholipid syndrome

Vasculitis

Antineutrophil cytoplasmic

antibody

ABSTRACT

Antiphospholipid syndrome is frequently associated with systemic lupus erythematosus and other autoimmune diseases. However, coexistence with primary vasculitis has been poorly reported. The case is presented of a 67-year-old patient with a history of recurrent abortion and chronic pulmonary thromboembolism who was admitted due to haemoptysis. At the initial evaluation, a massive alveolar haemorrhage and glomerulonephritis were diagnosed. The results of the antibodies were positive for ANCA with P-type pattern, anti-myeloperoxidase antibodies, and antiphospholipid antibodies (anti-β2 IgG glycoprotein 1 and lupus anticoagulant). Diagnosis of ANCA positive vasculitis-type microscopic polyangiitis was made in association with antiphospholipid syndrome. Given the clinical context, it was decided to initiate intravenous methylprednisolone in pulses for 3 consecutive days, followed by oral prednisone, and as maintenance therapy, rituximab and anticoagulation with warfarin were instituted. The clinical evolution of the patient was satisfactory, with symptom control being achieved, as well as a significant improvement of renal and pulmonary function, with a decrease in the Birmingham vasculitis activity score (BVAS).

© 2018 Asociación Colombiana de Reumatología. Published by Elsevier España, S.L.U. All rights reserved.

PII of original article: S0121-8123(18)30093-8

[☆] Please cite this article as: López-Villegas VJ, Medina-Morales DA, Saldarriaga-Rivera LM. Poliangitis microscópica y síndrome antifosfolípido. Una asociación infrecuente. Rev Colomb Reumatol. 2019;26:287–291.

* Corresponding author.

E-mail address: vasculitisreumato@gmail.com (L.M. Saldarriaga-Rivera).

2444-4405/© 2018 Asociación Colombiana de Reumatología. Published by Elsevier España, S.L.U. All rights reserved.

Poliangitis microscópica y síndrome antifosfolípido. Una asociación infrecuente

RESUMEN

Palabras clave:

Poliangitis microscópica
Síndrome antifosfolípido
Vasculitis
Anticuerpos anticitoplasma de neutrófilos

El síndrome antifosfolípido se asocia frecuentemente con lupus eritematoso sistémico y otras enfermedades autoinmunes. Sin embargo, la coexistencia con vasculitis primaria ha sido poco reportada. Se presenta el caso de una paciente de 67 años de edad con historia de aborto recurrente y tromboembolismo pulmonar crónico, quien es admitida para estudio de hemoptisis. A la evaluación inicial se diagnosticó una hemorragia alveolar masiva y glomerulonefritis. El resultado de los anticuerpos fue positivo para anticuerpos anticitoplasma de neutrófilos (ANCA) con patrón tipo perinuclear, anticuerpos anti-mieloperoxidasa y anticuerpos antifosfolípidos (anti $\beta 2$ glicoproteína 1 IgG y anticoagulante lúpico), configurándose el diagnóstico de vasculitis asociada a ANCA de tipo poliangeitis microscópica en asociación con síndrome antifosfolípido. Dado el contexto clínico, se decidió iniciar metilprednisolona intravenosa en pulsos por 3 días consecutivos, seguida de prednisona oral, y como terapia de mantenimiento se instauró rituximab y anticoagulación con warfarina. La evolución clínica de la paciente fue satisfactoria, alcanzando control de síntomas e importante mejoría de la función renal y pulmonar, con disminución del score BVAS.

© 2018 Asociación Colombiana de Reumatología. Publicado por Elsevier España, S.L.U. Todos los derechos reservados.

Introduction

Antiphospholipid syndrome (APS) is a condition defined by the coexistence of venous or arterial thrombosis, or gestational morbidity in the presence of antiphospholipid antibodies (lupus anticoagulant, anticardiolipin or anti $\beta 2$ glycoprotein (1) persistently positive for more than 12 weeks.¹ APS is frequently associated with systemic lupus erythematosus or with other underlying autoimmune disease, such as hemolytic anemia, idiopathic thrombocytopenic purpura, rheumatoid arthritis, Sjögren's syndrome, systemic sclerosis, mixed connective tissue disease, polymyositis, among others²; however, its coexistence with primary systemic vasculitis is infrequent.³

Microscopic polyangiitis (MPA) is a necrotizing pauci-immune vasculitis, which predominantly affects small vessels (e.g., capillaries, venules or arterioles).⁴ Its onset is more frequent in people over 50 years of age and affects more men than women; the two organs typically affected and that often define the prognosis are the kidney and the lung; however it can affect concomitantly other organs, such as the nervous system, the skin, the musculoskeletal system, the heart, the eyes and the gastrointestinal tract.⁵

A search conducted in Pubmed on the coexistence of MPA and APS only demonstrated one case published in this database.

The case is presented of a patient with a diagnosis of positive myeloperoxidase-anti-neutrophil cytoplasmic antibodies (MPO-ANCA) vasculitis type MPA with pulmonary and renal involvement, and a history of recurrent abortions and chronic pulmonary thromboembolism, being configured the diagnosis of APS due to the presence of antiphospholipid antibodies.

Clinical case

A 67-year old woman was admitted for study due to a clinical picture of 2 months of evolution of non-massive hemoptysis and subjective fever that appeared in the last month, with no other concomitant symptoms. At the beginning of the current clinical picture the patient was assessed in another institution, where they performed a chest CT-angiography, which revealed recanalized segmental thrombi and ground-glass areas both in upper and lower lobes, a diagnosis of pneumonia was established and it was decided to institute antibiotic treatment. A week later she was admitted to our institution. Her medical history was relevant due to the antecedent of hospitalization 2 years before due to a picture of diffuse alveolar hemorrhage confirmed by fibrobronchoscopy and a transbronchial biopsy that revealed signs of pulmonary thromboembolism in histopathology, without evidence of capillaritis; given this, management with rivaroxaban was initiated (additionally she was receiving a supplement of levothyroxine for primary hypothyroidism). She was not taking other medications nor had other known diagnoses. Her obstetric history was important, since she reported 7 embryogenic abortions, with more than 3 that occurred consecutively before the week 10. In the review of systems, numbness type paresthesias were found on the soles of both feet; other symptoms were negative.

At admission she was hemodynamically stable, with BP 104/65 mmHg; HR 79/min; RR 20/min; SpO₂ 96% on ambient air; weight 74 kg. The rest of the physical examination was only positive due to paleness in mucous membranes and fine crackles in the bases of both lungs.

The initial laboratory findings revealed moderate anemia of normal volumes, elevated C-reactive protein (CRP) and active

Table 1 – Results of paraclinical tests.

Exam	Admission	Day 4	Day 7	Day 18
Hemogram	Leukocytes 6460; neutrophils 4500; lymphocytes 1400; Hb 7.7; MCV 87.5; MCH 26.8; RDW 14.7; Hct 23%; platelets 443,000			
Coagulation	PTT: 32.7; PT: 14.7; INR 1.1			
Creatinine	1.32			
BUN	24.5			
CRP	39			
NA	142			
K	3.48			
Urinalysis	Density 1020; proteins 150 mg/dl; erythrocytes 250 (normal 0-5). Without erythrocyte dysmorphism. Bacteria+++			
Sputum smear	Negative for acid-alcohol resistant bacilli			
24 h urine protein	1760 mg			
Direct Coombs test	Negative			
C3	163			
C4	24.8			
Rheumatoid factor		<8.0		
AG-HBS		Negative		
ANTI-HVC		Negative		
VDRL		Non-reactive		
IgE level			96.47 (high)	
IgM level			69 (normal)	
IgG level			1314 (normal)	
IgA level			319 (normal)	
Anti-RO				<3.0
Anti-LA				<3.0
Anti-SM				4.9 (negative)
Anti-RNP				3.1 (negative)
Anti-DNA				Negative
ANCA				Positive 1/640 perinuclear pattern (ANCA-p)
Anti-myeloperoxidase (MPO) antibodies				90.1 (positive)
Anti-proteinase 3 (PR3) antibodies				0.64 (negative)
Anti-glomerular basement membrane (GBM) antibodies				Less than 1/20
Antinuclear antibodies (ANA)				Negative
β2-Glycoprotein IgM				1.4 (negative)
β2-Glycoprotein IgG				>100 (positive)
Anti-cardiolipin IgM				6.6 (negative)
Anti-cardiolipin IgG				<3.0 (negative)
Lupus anticoagulant				Positive

urinary sediment with proteinuria in the non-nephrotic range. The results of the diagnostic aids are shown in [Table 1](#); the chest X-ray and tomography are shown in [Figs. 1 and 2](#), respectively.

The patient was diagnosed with diffuse alveolar hemorrhage and glomerulonephritis. Anti-neutrophil cytoplasmic

antibodies (ANCA) by IIF were requested, which were positive in a titer of 1/640 with a perinuclear pattern, which was confirmed with the Elisa test, which was positive for myeloperoxidase (MPO) antibodies. A renal biopsy was performed with a finding of pauci-immune extracapillary proliferative glomerulonephritis and the electromyography demonstrated sensory

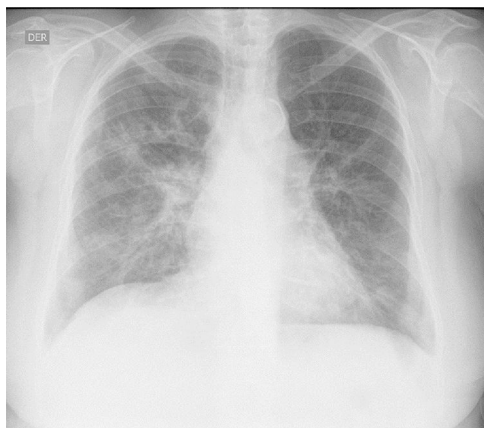


Fig. 1 – Chest X-ray. Bilateral parahilar and basal alveolo-interstitial opacities with a reticular predominance are observed.

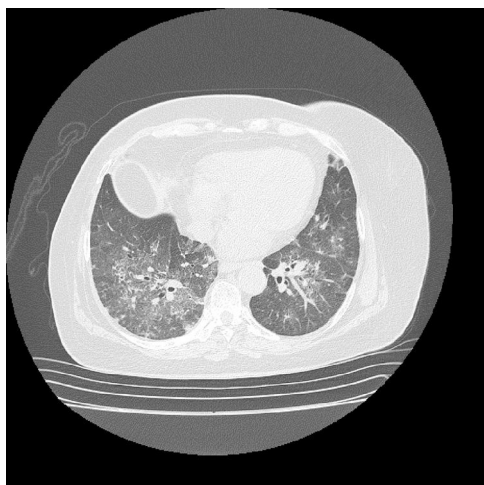


Fig. 2 – Chest tomography with contrast. There is a ground glass pattern with non-homogeneous distribution, with few centrilobular nodules, associated with traction, without formation of cavitations.

polyneuropathy of axonal type in lower limbs, configuring the diagnosis of positive MPO-ANCA vasculitis type MPA (in the absence of granulomas) with high disease activity (BVAS 12/33 points). The antinuclear antibodies (ANAs) were negative and of the antiphospholipid antibodies, the anti- β 2 glycoprotein 1 IgG resulted positive in a high titer, in addition to the lupus anticoagulant, the others being negative. Based on the obstetric antecedents, the finding of pulmonary thromboembolism by histology and chest CT angiography, in the presence of anti β 2 glycoprotein 1 antibodies in a high titer, the diagnosis of APS was established, taking into consideration the need to repeat the antiphospholipid antibodies at 12 weeks, which were positive.

The patient was treated with intravenous pulses of methylprednisolone for 3 consecutive days, followed by oral prednisone at a dose of 1 mg/kg/day. As maintenance therapy, rituximab was instituted, presenting a marked improvement in the renal and pulmonary function, with a decrease of the BVAS score to 2/33. Anticoagulation during the hospitalization

was done with low molecular weight heparins, and warfarin was started prior to discharge with a target INR between 2 and 3.

Discussion

MPA is an ANCA-associated small vessel vasculitis. This group is completed by granulomatosis with polyangiitis (GPA) and eosinophilic granulomatosis with polyangiitis.⁴

The affection in MPA is multisystemic; most patients have renal involvement; two thirds have musculoskeletal commitment; half have skin lesions; alveolar hemorrhage occurs in up to 30% of patients, and gastrointestinal and neurological compromise occurs in about one third of them.⁵

We describe the case of a patient with MPO-ANCA associated vasculitis that meets the characteristics of MPA according to the Chapel Hill consensus updated in 2012, with renal involvement given by pauci-immune extracapillary proliferative glomerulonephritis, demonstrated in histology; diffuse alveolar hemorrhage and peripheral neuropathy, in the absence of asthma, eosinophilia and granulomatous inflammation, which differentiates it from other ANCA-associated vasculitis.^{4,5}

As in this patient, the ANCAs in MPA are predominantly directed against MPO, and their pathogenic role in this condition is recognized from numerous studies, although the mechanisms by which tolerance is developed and broken remain unknown.⁶ In a minority of cases the ANCAs may be directed against proteinase 3 (PR3), although their role in pathogenesis is less convincing.⁷

In the etiology of ANCA-associated vasculitis, both genetic and environmental factors (e.g., exposure to silica, drugs such propylthiouracil and infections, particularly by *S. aureus*) are recognized,⁸ none of these were identified in the patient.

In addition, chronic pulmonary thromboembolism was documented in this patient. The incidence of this disorder is high in patients with primary systemic vasculitis.⁹ This association has been studied more in patients with GPA; in the clinical trial The Wegener's Granulomatosis Clinical Occurrence of Thrombosis Study (WeCLOT), with a population of 180 patients with GPA, the incidence of venous thromboembolic events was 20-fold higher than in the general population.¹⁰ The reasons are not identified.

The presence of antiphospholipid antibodies is not an unusual characteristic in patients with vasculitis. A higher frequency of anti-cardiolipin and anti β 2 glycoprotein 1 antibodies at low titers has been found in patients with GPA; however, a causal association of antiphospholipid antibodies with thrombosis has not been demonstrated.¹¹

In addition to GPA, antiphospholipid antibodies have been reported in association with polyarteritis nodosa, giant cell arteritis, polymyalgia rheumatica, Takayasu arteritis, Behçet syndrome, eosinophilic granulomatosis with polyangiitis and MPA.³

The study conducted by Rees et al.¹² in 144 patients with primary systemic vasculitis, reported a prevalence of 17% of antiphospholipid antibodies; 6% (9 patients) met criteria for APS, and of the latter, 4 patients had ANCA-associated small vessel vasculitis (2 cases with GPA and 2 cases with

eosinophilic granulomatosis with polyangiitis). No case of MPA was described, which is consistent with a search conducted in different databases.

The absence of capillaritis in the histological analysis of the lung specimen, taken during the first hospitalization of the patient, can be explained by a diffuse alveolar hemorrhage secondary to pulmonary thromboembolism. In this order of ideas and taking into account the obstetric antecedents of gestational losses occurred before the 10th week of pregnancy, associated with the laboratory criteria given by a positive result for lupus anticoagulant and anti β 2 glycoprotein 1 IgG at high titers, the diagnosis of APS was confirmed.

In conclusion, we consider that the clinical spectrum of patients with MPA continues to be defined; the additional characteristics observed in our patient suggested an associated APS, which was finally confirmed. Therefore, monitoring the development of antiphospholipid antibodies in patients with primary systemic vasculitis and evidence of thrombosis or obstetric morbidity may be important in determining the need for prophylactic anticoagulation for prevention of thrombosis.

Funding

None.

Conflict of interest

There is no conflict of interest.

REFERENCES

- Miyakis S, Lockshin MD, Atsumi T, Branch DW, Brey RL, Cervera R, et al. International consensus statement on an update of the classification criteria for definite antiphospholipid syndrome (APS). *J Thromb Haemost*. 2006;4:295–306.
- Levy RA, Gómez-Puerta JA, Cervera R. History, classification and subsets of the antiphospholipid syndrome. In: Cervera R, Espinosa G, Munther K, editors. *Handbook of systemic autoimmune diseases*, vol. 12. Elsevier; 2017. p. 1–16.
- Lally L, Sammaritano LR. Vasculitis in antiphospholipid syndrome. *Rheum Dis Clin North Am*. 2015;41:109–23, ix.
- Jennette JC, Falk RJ, Bacon PA, Basu N, Cid MC, Ferrario F, et al. 2012 revised International Chapel Hill Consensus Conference Nomenclature of Vasculitides. *Arthritis Rheum*. 2013;65:1–11.
- Villiger PM, Guillemin L. Microscopic polyangiitis: clinical presentation. *Autoimmun Rev*. 2010;9:812–9.
- McKinney EF, Willcocks LC, Broecker V, Smith KG. The immunopathology of ANCA-associated vasculitis. *Semin Immunopathol*. 2014;36:461–78.
- Kallenberg CGM. The diagnosis and classification of microscopic polyangiitis. *J Autoimmun*. 2014;48–49:90–3.
- Chen M, Kallenberg CG. ANCA-associated vasculitides — advances in pathogenesis and treatment. *Nat Rev Rheumatol*. 2010;6:653–64.
- Weidner S, Hafezi-Rachti S, Rupprecht HD. Thromboembolic events as a complication of antineutrophil cytoplasmic antibody-associated vasculitis. *Arthritis Rheum*. 2006;55:146–9.
- Merkel PA, Lo GH, Holbrook JT, Tibbs AK, Allen NB, Davis JC Jr, et al. Brief communication: high incidence of venous thrombotic events among patients with Wegener granulomatosis: the Wegener's Clinical Occurrence of Thrombosis (WeCLOT) Study. *Ann Intern Med*. 2005;142:620–6.
- Sebastian JK, Voetsch B, Stone JH, Romay-Penabad Z, Lo GH, Allen NB, et al. The frequency of anticardiolipin antibodies and genetic mutations associated with hypercoagulability among patients with Wegener's granulomatosis with and without history of a thrombotic event. *J Rheumatol*. 2007;34:2446–50.
- Rees JD, Lanca S, Marques PV, Gómez-Puerta JA, Moco R, Oliveri C, et al. Prevalence of the antiphospholipid syndrome in primary systemic vasculitis. *Ann Rheum Dis*. 2006;65:109–11.