

Letter to the Editor

Immunological profile in biopsies of primary angiitis of the central nervous system [☆]



Perfil inmunológico en biopsias de vasculitis primaria del sistema nervioso central

Dear Editor,

Primary angiitis of the central nervous system (PACNS) is a rare autoimmune disease characterized by the inflammation of central nervous system arteries without compromising any other organ, and without a primary cause. This disease predominantly affects medium to small caliber arteries in the brain parenchyma, the spinal cord and the meninges, causing central nervous system (CNS) dysfunction.¹ With an incidence rate of 2.4 cases per 1,000,000 habitants, it is a truly rare entity. Its pathophysiology is not yet elucidated, but it appears to be mediated by antigen presentation to the T lymphocytes in the arterial wall.²

PACNS is categorized into different subtypes according to pathological and histological findings: granulomatous angiitis of the central nervous system (GACNS), lymphocytic angiitis of the CNS, amyloid beta-related angiitis, mass-like lesions, and spinal cord vasculitis. With 59% of cases, GACNS is the most common of the subtypes.³

In 2013 our group reported 3 cases of patients with PACNS.⁴ This time, an immunohistochemical study was done in 2 of the patients' samples, revealing a leukocytic infiltrate (CD45+) constituted almost entirely of T lymphocytes (CD3+) with a clearly higher prevalence of CD4+ cells (Fig. 1A), with no evidence of plasmatic cells (CD138 and CD38 markers were negative) and an absence of Treg Lymphocytes (negativity for CD25). HLA was detected in 50% of the cells in both samples (Fig. 1B).

In a report of 4 biopsies of Japanese patients, there was a T lymphocyte infiltrate, with a predominance of CD8+ cells in the brain parenchyma, and a B lymphocyte (CD20+) prevalence in the perivascular area.⁵ In another Japanese case report,⁶ the biopsy analysis showed an infiltrate of memory T cells (CD45RO+), suggesting that an activation by cytokines such as IFN- γ leads to an enhanced antigen presentation by perivascular macrophages, endothelial cells, smooth muscle cells, and astrocytes. These data, along with our results, suggests a T lymphocyte (with CD4 predominance), Th1 response (with

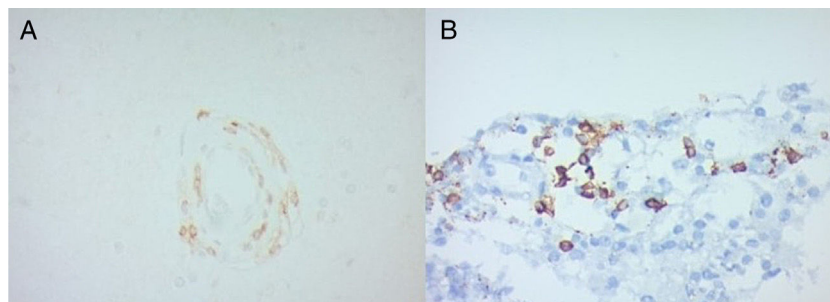


Fig. 1 – Immunohistochemistry in biopsy samples of two patients with PACNS. (A) Leukocytic infiltrates mostly of T lymphocytes (CD3+) with higher prevalence of CD4+ cells. (B) HLA expression in PACNS (50% of the cells).

[☆] The patients authorized the publication of this article and signed informed consent.

IFN- γ and IL-12 cytokines) mediated disease. The negligible presence of B lymphocytes and the absence of plasmatic cells imply that this is not a humoral immunity mediated entity.

Nevertheless, more complex studies are required to understand the pathophysiology of this disease, the cytokine expression pattern, and to be able to establish a difference between the leukocyte infiltrate of the brain parenchyma and the perivascular space. In the future, this information could lead to targeted therapy against T lymphocyte co-stimulation.

Conflict of interest

The authors declare they have no conflicts of interest. No financial support was received.

REFERENCES

- Mandal J, Chung SA. Primary angiitis of the central nervous system. *Rheum Dis Clin* [Internet]. Elsevier; 2017;43:503-18. doi:10.1016/j.rdc.2017.06.001.
- Salvarani C, Brown RDJ, Hunder GG. Adult primary central nervous system vasculitis. *Lancet*. 2012;380:767-77.
- Salvarani C, Brown RD, Christianson TJH, Huston J, Giannini C, Miller DV, et al. Adult primary central nervous system vasculitis treatment and course: analysis of one hundred sixty-three patients. *Arthritis Rheumatol* [Internet]. 2015;67:1637-45, <http://dx.doi.org/10.1002/art.39068>.
- Coronel-Restrepo N, Bonilla-Abadia F, Cortes OA, Izquierdo JH, Shinchi AM, Bravo JC, et al. Primary angiitis of the central nervous system: a report of three cases from a single colombian center. *Case Rep Neurol Med*. 2013;2013:940438.
- Myung J, Kim B, Yoon B-W, Lee SK, Sung J-J, Chung CK, et al. B-cell dominant lymphocytic primary angiitis of the central nervous system: four biopsy-proven cases. *Neuropathology*. 2010;30:123-30.
- Iwase T, Ojika K, Mitake S, Katada E, Katano H, Mase M, et al. Involvement of CD45RO+ T lymphocyte infiltration in a patient with primary angiitis of the central nervous system restricted to small vessels. *Eur Neurol*. 2001;45:184-5.

Iván Posso-Osorio^a, Daniela Espinosa-Cárdenas^b, David Aguirre-Valencia^a, Juan Naranjo-Escobar^a, Luis-Alberto Escobar^c, Carlos A. Cañas^a, Gabriel J. Tobón^{a,d,*}

^a GIRAT: Grupo de Investigación en Reumatología, Autoinmunidad y Medicina Traslacional, Fundación Valle del Lili and Universidad Icesi, Cali, Colombia

^b Centro de Investigaciones Clínicas, Fundación Valle del Lili, Cali, Colombia

^c Unidad de Patología, Fundación Valle del Lili, Cali, Colombia

^d Laboratorio de Inmunología, Fundación Valle del Lili, Cali, Colombia

* Corresponding author.

E-mail address: gtobon1@yahoo.com (G.J. Tobón). 0121-8123/

© 2020 Asociación Colombiana de Reumatología. Published by Elsevier España, S.L.U. All rights reserved. <https://doi.org/10.1016/j.rcreu.2019.10.008>