




# Enfermedades Infecciosas y Microbiología Clínica

www.elsevier.es/eimc



## Scientific letters

### Cutaneous infection due to *Mucor irregularis* (*Rhizomucor variabilis*) in a immunocompetent traveller



#### *Infeccion cutanea por Mucor irregularis en una viajera inmunocompetente*

Cutaneous mucormycosis is an uncommon disease characterized by acute onset, an angioinvasive character and rapid progression caused by saprophytic fungi of the order Mucorales. It is usually associated with immunosuppression and/or predisposing factors such as neutropenia, diabetes, organ transplantation, malignancies or traumatic injuries.<sup>1,2</sup> Zygomycosis caused by *Mucor irregularis* (formerly *Rhizomucor variabilis* var. *variabilis*) mainly affects immunocompetent patients<sup>1–3</sup> and it is a rare disease, characterized by inflammation, ulceration and destruction of surrounding tissue, leading to a deformation of the affected limb, and it is potentially fatal if left untreated.<sup>3</sup>

Few cases have been reported worldwide mainly in Asia,<sup>3–5</sup> and more recently outside.<sup>6</sup> We describe below the first reported case to our knowledge of *M. irregularis* isolated in an immunocompetent Spanish patient.

The patient was a Spanish 28-year-old female, resident in Spain, with no relevant clinical history. She was attended in Tropical Diseases Unit of Hospital Universitario Central de Asturias in April 2014. She reported that two months earlier, during a one-month stay in Guatemala, she observed bites on both lower limbs, whose size increased progressively, with cyclical occurrence of scab and itching skin sensation, and sometimes releasing purulent material. On physical examination, crusted skin lesions with well-defined edges and inflammatory halo were observed on both legs.

*M. irregularis* was isolated in microbiological culture, and identified by macroscopic and microscopic study of its morphology. It was a gray and fast-growing filamentous fungi in Sabouraud agar. In sample preparation for microscopic characterization, non-septate hyphae with rhizoids were observed. Sporangioophores were subspherical, over 100  $\mu\text{m}$  in maximum diameter. There was a subspheric columella and spores 10  $\mu\text{m}$  long. Fungi did not grow at 45 °C, allowing differentiation of *M. irregularis* from the other species.<sup>7</sup> The confirmation by molecular methods was not possible. Susceptibility testing was performed using E-test strips (bioMérieux) and showed only susceptibility to Amphotericin. Patient began receiving an initial dose of 300 mg of intravenous liposomal amphotericin B, followed by 200 mg/day during 4 days and 240 mg/day the following 15 days (a total dose of 4.7 g of liposomal amphotericin B), associated with 50 mg/day of caspofungin during 19 days. Due to her worsening renal function (rise of creatinine level from 0.71 mg/dl to 1.34 mg/dl) and the poor response to initial treatment, treatment with topical amphotericin B was added. The pharmacy department developed an oil-in-water gel for the topical delivery of amphotericin B (1.25%), resulting in

a significant improvement of skin lesions. For hospital discharge (length of stay: 20 days), systemic therapy was stopped, and the patient continued with local antifungal treatment. All microbiological tests showed no evidence of fungi. During the follow-up, there was a complete improvement of lesions.

Since *M. irregularis* was first isolated in 1991, skin infection caused by this fungus has been described as an endemic emerging mucormycosis in China.<sup>1,3,4</sup> Moreover, in recent years it has been spreading around the world: first to other Asian countries,<sup>2</sup> and later to the United States,<sup>6</sup> and Europe.<sup>8</sup> Nevertheless, the presence of *M. irregularis* had never been reported neither from Spain, nor from Central America, where the patient was infected. The diagnosis was made based on the characteristics of the fungus following Hoog et al algorithms.<sup>7</sup> Although it would have been advisable to be confirmed by molecular biology techniques, they were not available in the center.

First-line treatment of cutaneous mucormycosis consists of liposomal amphotericin B therapy and surgical resection.<sup>9</sup> In this case, a superficial debridement combined with medical therapy was carried out. Despite microbiological test results showing susceptibility only to amphotericin B, caspofungine was added to the therapeutic regimen since some *in vitro* studies have shown synergy between these two antifungal agents.<sup>10</sup> Furthermore, these findings were confirmed in clinical practice in some of the cases reported, in which a combination of caspofungin and liposomal amphotericin B or posaconazole was effective in treating *M. irregularis* infection.<sup>11</sup>

Regarding the additional administration of topical amphotericin, this strategy is similar to that used in the case reported by de Hemashettar et al. in 2011,<sup>11</sup> in which local fluconazole was added to systemic therapy in order to treat the infection. In this case, the gel formulation of amphotericin B enabled better contact with the infective agent, providing an increased pharmacological effect of the antifungal agent and limiting nephrotoxicity, making it possible to continue with treatment despite the renal function deterioration observed during the course of hospital treatment.

In conclusion *M. irregularis* is an endemic emerging mucormycosis, which has not been previously described in Spain, or in Central America, where the patient contracted the infection. The synergistic combination of amphotericin B with intravenous caspofungin and topical amphotericin B may be useful in the treatment of this mucormycosis.

## References

- Zhao Y, Zhang Q, Li L, Zhu J, Kang K, Chen L. Primary cutaneous mucormycosis caused by *Rhizomucor variabilis* in an immunocompetent patient. *Mycopathologia*. 2009;168:243–7.
- Tomita H, Muroi E, Takenaka M, Nishimoto K, Takeya H, Ohno H, et al. *Rhizomucor variabilis* infection in human cutaneous mucormycosis. *Clin Exp Dermatol*. 2011;36:312–4.
- Lu X, Liu Z, Shen Y, She X, Lu G, Zhan P, et al. Primary cutaneous zygomycosis caused by *Rhizomucor variabilis*: a new endemic zygomycosis? A case report and

- review of 6 cases reported from China. *Clin Infect Dis Off Publ Infect Dis Soc Am.* 2009;49:e39–43.
4. Li DM, Lun LD. *Mucor irregularis* infection and lethal midline granuloma: a case report and review of published literature. *Mycopathologia.* 2012;174:429–39.
  5. Matsudate Y, Murao K, Urano Y, Yarita K, Kamei K, Takeichi H, et al. Primary cutaneous mucormycosis caused by *Mucor irregularis* in an immunocompetent patient. *J Dermatol.* 2015;42:267–8.
  6. Schell WA, O'Donnell K, Alspaugh JA. Heterothallic mating in *Mucor irregularis* and first isolate of the species outside of Asia. *Med Mycol.* 2011;49:714–23.
  7. Hoog GS, Guarro J, Gene J, Figueras MJ. Atlas of clinical fungi. Reus, Spain: Centraalbureau voor Schimmelcultures/Universitat Rovira and Virgili; 2000.
  8. Rammaert B, Angebault C, Scemla A, Fraïtag S, Lerolle N, Lecuit M, et al. *Mucor irregularis*-associated cutaneous mucormycosis: case report and review. *Med Mycol Case Rep.* 2014;6:62–5.
  9. Tehmeena W, Hussain V, Zargar HR, Sheikh AR, Iqbal S. Primary cutaneous mucormycosis in an immunocompetent host. *Mycopathologia.* 2007;164:197–9.
  10. Zhang S, Li R, Yu J. Drug combinations against *Mucor irregularis* in vitro. *Antimicrob Agents Chemother.* 2013;57:3395–7.
  11. Hemashettar BM, Patil RN, O'Donnell K, Chaturvedi V, Ren P, Padhye AA. Chronic rhinofacial mucormycosis caused by *Mucor irregularis* (*Rhizomucor variabilis*) in India. *J Clin Microbiol.* 2011;49:2372–5.

Cristina Martínez-Mugica<sup>a</sup>, Susana Rojo Alba<sup>b</sup>, Jose A. Boga<sup>b</sup>, Azucena Rodríguez-Guardado<sup>c,\*</sup>

<sup>a</sup> Pharmacy Unit, Hospital Universitario Central de Asturias, Oviedo, Spain

<sup>b</sup> Microbiology Unit, Hospital Universitario Central de Asturias, Oviedo, Spain

<sup>c</sup> Tropical Diseases Unit, Hospital Universitario Central de Asturias, Oviedo, Spain

\* Corresponding author.

E-mail address: [azucenarodriguez@telecable.es](mailto:azucenarodriguez@telecable.es) (A. Rodríguez-Guardado).

<http://dx.doi.org/10.1016/j.eimce.2016.06.001>  
2529-993X/

© 2016 Elsevier España, S.L.U. and Sociedad Española de Enfermedades Infecciosas y Microbiología Clínica. All rights reserved.

## Keratitis due to *Nocardia nova* after cataract surgery



### Queratitis por *Nocardia nova* tras cirugía de cataratas

In the last few years, the genus *Nocardia* has undergone rapid taxonomic expansion due to the utilization of 16S sequencing<sup>1</sup> resulting in more than 100 recognized described species, although around two thirds of them are known as pathogen.<sup>2</sup>

*Nocardia* infections can be acquired by either inhalation, causing lung disease in immunocompromised patients<sup>3</sup> or traumatic inoculation. Ocular affection caused by these organisms is a rare location, being keratitis more frequent than scleritis or endophthalmitis infection.<sup>4</sup> Here we describe one case of side-port infection of a self-sealing corneal tunnel incision following an uneventful phacoemulsification as a complication of cataract surgery due to *Nocardia nova*.

The patient was a 59-year-old male who underwent an uneventful clear corneal temporal incision phacoemulsification with a foldable intraocular lens (day 0). He recovered uneventfully a month after surgery (day 30) being treated with a combination of tobramycin/dexamethasone and diclofenac eye drops.

In the 48 day, the patient came to the hospital with complaints of redness, tearing, photophobia, blurry vision and irritation in the right eye during two days. Visual acuity was recorded as 20/30. The cornea showed a small stromal infiltrate of 3 mm diameter in the superior temporal quadrant of the right cornea with a 1+ anterior chamber reaction but no hypopyon, being 1 mm from the limbus (in the self-sealing tunnel incision), with an epithelial defect of 2 mm diameter, an ill-defined border and mild surrounding corneal edema (Fig. 1). Corneal scraping was taken for microbiological processing and inoculated on tryptic soy 5% sheep blood agar and chocolate agar (bioMérieux®, Marcy-L'Étoile, France), being incubated at 37 °C in 5% CO<sub>2</sub> aerobic atmosphere. He was empirically treated with hourly fortified vancomycin and ceftazidime eye drops. On follow-up the infiltrate did not improve.

After 3 days of incubation (day 51), the culture revealed a significant growth of a microorganism. The Gram-stain of the colony showed gram positive branching filamentous rods. A Ziehl-Neelsen stain and a modified Ziehl-Neelsen stain (5% sulfuric acid) were performed, being negative and positive respectively. The organism was identified as *Nocardia* spp. according to the morphology of the colony and the stain characteristics. The patient had not any risk factors for this infection and he did not travel abroad. Then,

treatment was changed to oral trimethoprim-sulfamethoxazole (400/80 mg twice daily) and hourly fortified amikacin and moxifloxacin 0.5% eye drops. In the day 53 clinical improvement was obvious.

Due to partial resolution of the infiltrate, oral cotrimoxazole treatment was finished in day 61, and topical treatment with amikacin and moxifloxacin was finally stopped in day 77 because the lesion was finally cured.

An antimicrobial susceptibility test was performed (day 51) through broth microdilution test (Sensititre®, Trek Diagnostics Systems, West Sussex, England). Minimum inhibitory concentration (MIC) (μg/ml) values were obtained after 72 h of incubation (day 54) and they were as follows: susceptible to amikacin (<1) and cotrimoxazole (2); and resistant to ciprofloxacin (>4) and moxifloxacin (4).

Despite “in vitro” resistant to quinolones, topical moxifloxacin treatment was maintained due to the improvement of the patient.

The strain was then submitted to Instituto de Salud Carlos III (Majadahonda, Madrid, Spain) (day 55) for 16S rRNA gene sequencing, being identified as *Nocardia nova* (day 85).

Keratitis is an ocular infection affecting the cornea, with unusual reported cases due to *Nocardia* or *Mycobacterium*.<sup>5</sup>

The most effective agents toward most infections produced by *Nocardia* are cotrimoxazole and amikacin, being the latter the

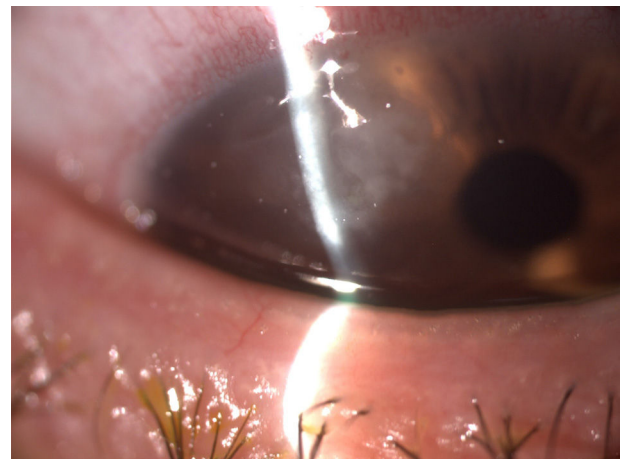


Fig. 1. Cornea infiltrate.