




# Enfermedades Infecciosas y Microbiología Clínica

www.elsevier.es/eimc



Brief report

## Lady Windermere syndrome in Castile and León<sup>☆</sup>

Sara Blanco-Conde<sup>a,\*</sup>, Teresa Nebreda-Mayoral<sup>b</sup>, Cristina Labayru-Echeverría<sup>c</sup>,  
M. Fe Brezmes-Valdivieso<sup>d</sup>, Ramiro López-Medrano<sup>e</sup>, Begoña Nogueira-González<sup>f</sup>

<sup>a</sup> Servicio de Análisis Clínicos, Complejo Asistencial Universitario de León, León, Spain

<sup>b</sup> Servicio de Microbiología, Complejo Asistencial Universitario de León, León, Spain

<sup>c</sup> Servicio de Microbiología, Complejo Asistencial Universitario de Burgos, Burgos, Spain

<sup>d</sup> Servicio de Microbiología, Complejo Asistencial de Zamora, Hospital Virgen de la Concha, Zamora, Spain

<sup>e</sup> Unidad de Microbiología, Hospital El Bierzo, Ponferrada, León, Spain

<sup>f</sup> Servicio de Microbiología, Hospital Clínico Universitario de Valladolid, Valladolid, Spain

### ARTICLE INFO

#### Article history:

Received 21 August 2017

Accepted 22 December 2017

Available online 22 September 2018

#### Keywords:

Non-tuberculous mycobacteria

*Mycobacterium avium* complex

Lady Windermere syndrome

### ABSTRACT

**Introduction:** Lady Windermere syndrome (LWS) is a pulmonary disease caused by *Mycobacterium avium* complex (MAC). The objective of this study is to ascertain its frequency and characteristics in the northern area of the autonomous community of Castile and León.

**Methods:** A retrospective study of patients with MAC isolates in respiratory samples from five public hospitals in the autonomous community over a 6-year period, following the ATS/IDSA criteria. The MAC strains were identified by GenoType Mycobacterium reverse hybridisation probes or PCR-RFLP analysis of the hsp65 gene.

**Results:** Of 183 cases of MAC identified, only five women (2.7%) aged  $68.8 \pm 10.7$  years met LWS criteria. In three cases, MAC was isolated jointly and intermittently with other pathogens. Only one patient was treated according to ATS/IDSA criteria.

**Discussion:** LWS remains underestimated, with affected patients representing a significant burden on healthcare resources over long periods of time. As a result, greater microbiological and therapeutic knowledge of the syndrome is needed.

© 2018 Elsevier España, S.L.U. and Sociedad Española de Enfermedades Infecciosas y Microbiología Clínica. All rights reserved.

## Síndrome de Lady Windermere en Castilla y León

### RESUMEN

**Introducción:** El síndrome de Lady Windermere (SLW) es una patología pulmonar causada por *Mycobacterium avium* complex (MAC). El objetivo es conocer su frecuencia y sus características en el área norte de la comunidad de Castilla y León.

**Métodos:** Estudio retrospectivo de pacientes con aislamientos de MAC en muestras respiratorias de cinco hospitales públicos de la comunidad a lo largo de seis años, siguiendo criterios de la ATS/IDSA. Las cepas de MAC se identificaron por sondas de hibridación inversa Genotype Mycobacterium o PCR-RFLP del gen hsp65.

**Resultados:** De 183 casos de MAC identificados, únicamente 5 (2,7%) mujeres de  $68,8 \pm 10,7$  años cumplían criterios de SLW. En tres casos se aisló MAC conjunta e intermitentemente con otros patógenos. Solo un paciente se trató siguiendo criterios de la ATS/IDSA.

**Discusión:** El SLW permanece infraestimado, y al ser los afectados muy demandantes de recursos sanitarios durante largos periodos, es necesario un mayor conocimiento microbiológico y terapéutico.

© 2018 Elsevier España, S.L.U. y Sociedad Española de Enfermedades Infecciosas y Microbiología Clínica. Todos los derechos reservados.

#### Palabras clave:

Micobacterias no tuberculosas

*Mycobacterium avium* complex

Síndrome de Lady Windermere

<sup>☆</sup> Please cite this article as: Blanco-Conde S, Nebreda-Mayoral T, Labayru-Echeverría C, Brezmes-Valdivieso MF, López-Medrano R, Nogueira-González B. Síndrome de Lady Windermere en Castilla y León. *Enferm Infecc Microbiol Clin.* 2018;36:644–647.

\* Corresponding author.

E-mail address: [sl.blanconde@gmail.com](mailto:sl.blanconde@gmail.com) (S. Blanco-Conde).

## Introduction

Infection with non-tuberculous mycobacteria (NTM) is an emerging disease in both immunosuppressed and immunocompetent patients.<sup>1,2</sup> Mycobacteria belonging to the *Mycobacterium avium* complex (MAC) are among the most frequently isolated NTM in patients with cystic fibrosis and AIDS. They generally cause chronic lung disease with variable, non-specific symptoms. One pattern caused by MAC is Lady Windermere syndrome (LWS).<sup>3</sup> This was first reported in 1989 by Prince et al.<sup>4</sup> and subsequently named by Reich and Johnson<sup>5</sup> based on the maxim “Ladies don’t spit” from the play *Lady Windermere’s Fan* by Oscar Wilde. It mainly affects immunocompetent elderly women with no history of smoking or lung disease. It essentially damages the middle lobe and the lingula.<sup>3</sup> One theory with respect to predisposition to this disease is based on the fact that voluntary cough inhibition hinders elimination of secretions and facilitates inflammation, appearance of bronchiectasis and ultimately infection with MAC. However, this theory has never been proved and few reported cases reflect this fact.<sup>1</sup> Another hypothesis that explains the marked predisposition to impairment of the middle lobe is based on an interaction between the lung/chest anatomy and personal habits.<sup>6</sup> Although the literature features few case series,<sup>4,5,7–11</sup> the disease is recognised in an official document from the American Thoracic Society/Infectious Disease Society of America (ATS/IDSA) establishing criteria for its diagnosis and treatment.<sup>3</sup>

The objective of this study was to determine the frequency of LWS in the northern area of the Autonomous Community of Castile and León in the last 6 years, as well as the clinical, microbiological and radiological characteristics of patients with LWS.

## Material and methods

This was a retrospective study of all cases of patients with MAC isolates in respiratory samples recorded in the microbiology information systems of five public hospitals in Castile and León (Complejo Asistencial Universitario de León, Complejo Asistencial Universitario de Burgos, Complejo Asistencial Universitario de Zamora, Hospital del Bierzo Ponferrada and Hospital Clínico Universitario de Valladolid) between January 2010 and December 2016. Patients who presented with mycobacteriosis according to the ATS/IDSA criteria (positive culture of at least two sputum series or one bronchoalveolar lavage/bronchial aspirate) fitting the pattern of LWS were selected.<sup>3</sup> Clinical and epidemiological data as well as information on treatment and clinical course in each case were collected by reviewing each patient’s medical history.

Bacterial and mycobacterial culture was performed on respiratory samples according to normal procedures.<sup>3</sup> At three of the healthcare centres, isolated MAC strains were identified using GenoType Mycobacterium CM reverse hybridisation probes (Hain Lifescience, Germany). At the other two, said strains were sent to the Spanish National Mycobacteria Centre (CNM) in Majadahonda, Spain, to be identified by means of PCR-RFLP of the *hsp65* gene using the *Bst*II and *Hae*III restriction enzymes.

## Results

In total, 183 cases of patients with MAC were identified in 6 years of follow-up. Their distribution by health area was as follows: 56 in León, 38 in Burgos, 34 in El Bierzo, 32 in Valladolid and 23 in Zamora. Just five (2.7%) met criteria for LWS: four recorded in León and one recorded in Burgos. These patients’ main clinical characteristics, radiological (Fig. 1) and microbiological characteristics and therapeutic actions are shown in Table 1.

All were women with a mean age of  $68.8 \pm 10.7$  years (range 59–87 years). Three of these women were notably naturally lean, and one of these three women had scoliosis as a predisposing factor.<sup>1,3,7–11</sup> In all cases, microbiological follow-up subsequent to diagnosis consisted of culture of 2–3 sputum series, sent every 4–6 months over a clinical course of years. These always showed growth of the initially isolated mycobacterium. In three cases, they also showed concomitant or intermittent growth of other pathogens (Table 1).

## Discussion

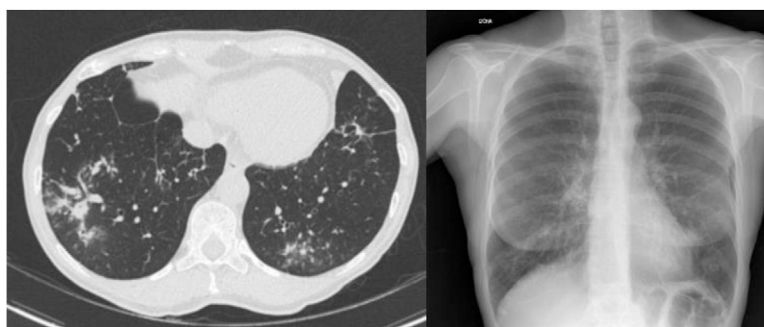
In the last 20 years, the incidence of pulmonary infection with MAC has been increasing<sup>2</sup>; however, LWS remains an uncommon and probably underestimated disease due to the complexity of the differential diagnosis of a colonisation versus an infection as well as the low sensitivity of sputum cultures (most often, the samples initially sent for diagnosis are sputum samples).<sup>8,9</sup>

Given the limited number of cases in our study, it could not be established that there was a real epidemiological difference in terms of LWS between the different areas studied. This may have been due to the frequency of distribution of this NTM in the different areas, the collection of clinical/radiological information or the selection of BAL and/or BAS as diagnostic samples.

A review of the Medline, Medical Key, Google Scholar and WoS databases revealed only seven reported case series.<sup>4,5,7–11</sup> Therefore, we believe that the five cases presented are a notable contribution to the knowledge of this disease. In our series, all patients were women, as in most reported cases of LWS,<sup>4,5,7–11</sup> although anecdotally at least one case has been published of a man who met the established inclusion criteria.<sup>12</sup> To date, no clear reason has been unearthed for this gender predilection. A wide range of hypotheses have been put forth, including the role of sex hormones and mediators such as leptin and adiponectin in the release of certain cytokines (TGF- $\beta$ ) and the expression of macrophage receptors (Fc $\gamma$ ).<sup>9,13</sup>

*M. avium* and *Mycobacterium intracellulare* are not usually differentiated in clinical practice. The pathogenic differences between the two species are debated in the literature. Some authors have insisted that there are no pathogenic differences between them<sup>14</sup>; others maintain that *M. intracellulare* is associated with a poorer clinical course and response to treatment.<sup>10</sup> Our study yielded no conclusive findings in this regard, although the patient with the poorest clinical course (recurrent episodes of haemoptysis for 30 years) was infected with *M. intracellulare* and intermittently presented co-infection with *Pseudomonas aeruginosa* in monitoring studies. This is a common combination throughout the literature. *P. aeruginosa* has been linked to greater pulmonary dysfunction. It is difficult to determine whether this decline was due to the type of isolates obtained or the long clinical course of that case compared to all the others. A total of three of the cases reported presented co-infections at different points in their disease. The pathogens isolated were *Haemophilus influenzae* and *Staphylococcus aureus*.<sup>3,6</sup>

Infection with MAC develops gradually and may take months or years to manifest, generally in a mild, non-specific form. Few patients develop a severe form.<sup>10</sup> As a result, it is difficult to decide on starting a therapeutic regimen. The risk–benefit ratio must be weighed up in each case in view of the therapeutic regimens and toxicities of the different options. At present, if there is no radiological worsening (progression of bronchiectasis or appearance of further cavities), close monitoring is done. The start of treatment consists of triple therapy for a year in which the use of a macrolide in monotherapy is avoided to prevent the development of resistance. In this series of cases, just one patient decided to



**Figure 1.** Patient 3. Computed tomography scan and chest X-ray: bronchiectasis in upper lobe, middle lobe and lingula; nodules in left lower lobe.

**Table 1**

Main characteristics in terms of diagnosis, signs and symptoms, and clinical course of patients with LWS.

Characteristics	Patient 1 (León)	Patient 2 (León)	Patient 3 (León)	Patient 4 (León)	Patient 5 (Burgos)
Age (years)	64	87	67	67	59
Signs and symptoms	Productive cough, asthenia	Non-productive cough, asthenia	Non-productive cough	Haemoptysis	Non-productive cough
Initial biological sample	1 BAL and 1 BAS	3 sputum series	1 BAL	1 BAS	1 BAS
Radiology	Bronchiectasis in UL, nodules	Bronchiectasis in lingula and ML, nodules, lymphadenopathy	Bronchiectasis in LL and ML, bilateral bronchopneumonia, lymphadenopathy	Bronchiectasis in UL, ML and lingula, nodules in LLL	Bronchiectasis in ML, UL and lingula, nodules, lymphadenopathy
NTM	<i>M. avium</i>	<i>M. intracellulare</i>	<i>M. avium</i>	<i>M. intracellulare</i>	<i>M. avium</i>
Co-infection	<i>S. aureus</i> and/or <i>H. influenzae</i>	—	<i>H. influenzae</i>	<i>P. aeruginosa</i>	—
Treatment	Clarithromycin 500 mg/12 h/8 months	None	None	None	Rifampicin, clarithromycin ethambutol (8 months)
Clinical course	Signs and symptoms persistent, X-ray stable (4 years)	Signs and symptoms chronic, X-ray stable (3 years)	Follow-up at another hospital	More recurrent episodes of haemoptysis in the last 10 years, X-ray stable (30 years)	Signs and symptoms stable, X-ray worse (4 years)

BAL, bronchoalveolar lavage; BAS, bronchial aspirate; LL, lower lobe; LLL, left lower lobe; ML, middle lobe; UL, upper lobe.

start the therapeutic treatment proposed by the ATS/IDSA<sup>3</sup>; after 8 months of treatment, this patient experienced clinical stability with radiological worsening. One patient started a macrolide in monotherapy due to intolerance to all the other antibiotics and remained radiologically stable but had marked signs and symptoms. This happened even though the patient did not develop resistance and this drug is the most important one in the therapeutic regimen. Administering it in monotherapy in cases of established infection proves inadequate, whereas administering it as prophylaxis may be considered.<sup>2,3</sup> Other studies of LWS have found the proportion of patients receiving treatment to be 20–50% (United States, Canada and South Korea) and have noted high rates of intolerance to antibiotic therapy and therapeutic failure due to persistent or recurrent symptoms.<sup>2,7–9</sup>

Our series contributed useful information to the knowledge of this disease which is so uncommon in our setting. It had the limitations inherent to retrospective studies and the small number of patients collected. LWS affects patients who require large amounts of healthcare resources for long periods of time. Therefore, greater knowledge of the strains of MAC that this disease produces must be acquired by means of their genotyping in order to develop new

strategies that are more efficient and effective than the current strategies.

### Conflicts of interest

The authors declare that they have no conflicts of interest.

### References

- Dhillon SS, Watanakunakorn C. Lady Windermere syndrome: middle lobe-bronchiectasis and *Mycobacterium avium* complex infection due to voluntary cough suppression. *Clin Infect Dis.* 2000;30:572–5.
- Park IK, Olivier KN. Nontuberculous mycobacteria in cystic fibrosis and non-cystic fibrosis bronchiectasis. *Semin Respir Crit Care Med.* 2015;36:217–24.
- Griffith DE, Aksamit T, Brown-Elliott BA, Catanzara A, Daley C, Gordin F, et al. An official ATS/IDSA statement: diagnosis, treatment and prevention of nontuberculous mycobacterial disease. *Am J Respir Crit Care Med.* 2007;175:367–416.
- Prince DS, Peterson DD, Steiner RM, Gottlieb JE, Scott R, Israel HL, et al. Infection with *Mycobacterium avium* complex in patient without predisposing conditions. *N Engl J Med.* 1989;321:863–8.

5. Reich JM, Johnson RE. *Mycobacterium avium* complex pulmonary disease presenting as an isolated lingular or middle lobe pattern: the Lady Windermere syndrome. *Chest*. 1992;101:1605–9.
6. Iseman MD, Bushman DL, Ackerson LM. Pectus excavatum and scoliosis: thoracic anomalies associated with pulmonary disease caused by *Mycobacterium avium* complex. *Am Rev Respir Dis*. 1991;144:914–6.
7. Wickremasinghe M, Ozerovitch LJ, Wodehouse T, Chadwick MV, Abdallah S, Shah P, et al. Non-tuberculous mycobacteria in patients with bronchiectasis. *Thorax*. 2005;60:1045–51.
8. Huang JH, Kao PN, Adi V, Ruoss SJ. *Mycobacterium avium-intracellulare* pulmonary infection in HIV-negative patients without preexisting lung disease. *Chest*. 1999;115:1033–40.
9. Chalermkulrat W, Gilbert JG, Donohue JF. Nontuberculous mycobacteria in women, young and old. *Clin Chest Med*. 2002;23:675–86.
10. Koh WJ, Jeong BH, Jeon K, Lee NY, Lee KS, Woo SY, et al. Clinical significance of the differentiation between *Mycobacterium avium* and *Mycobacterium intracellulare* in *M. avium* complex lung disease. *Chest*. 2012;142:1482–8.
11. Plotinsky RN, Talbot EA, von Reyn F. Proposed definitions for epidemiologic and clinical studies of *Mycobacterium avium* complex pulmonary disease. *PLoS ONE*. 2013;8:e77385.
12. Figueira Gonçalves JM, Rodríguez González J. Lady Windermere syndrome: does it occur only in women? *Arch Bronconeumol*. 2016;52:533–9.
13. Mirsaedi M, Sadiket RT. Gender susceptibility to mycobacterial infectious in patients with non-CF bronchiectasis. *Int J Mycobacterial*. 2015;4:92–6.
14. Tomioka H, Saito H, Sato K, Dawson DJ. Comparison of the virulence for mice of *Mycobacterium avium* and *Mycobacterium intracellulare* identified by DNA Probe Test. *Microbiol Immunol*. 1993;37:259–64.