

9. Saito S, Kawamura I, Tsukahara M, Uemura K, Ohkusu K, Kurai H. Cellulitis and bacteremia due to *Corynebacterium striatum* identified by matrix-assisted laser desorption ionization-time of flight mass spectrometry. *Intern Med.* 2016;55:2015–7.
10. Campanile F, Carretto E, Barbarini D, Grigis A, Falcone M, Goglio A, et al. Clonal multidrug-resistant *Corynebacterium striatum* strains Italy. *Emerg Infect Dis.* 2009;15:75–8.

Marta Fernández-Esgueva^{a,*}, Nuria Pérez-Jimeno^b,
Víctor Roda-Rojo^b, Isabel Ferrer-Cerón^a

^a *Servicio de Microbiología Clínica y Parasitología, Hospital Universitario Miguel Servet, Zaragoza, Spain*

^b *Servicio de Cirugía Ortopédica y Traumatología, Hospital Universitario Miguel Servet, Zaragoza, Spain*

* Corresponding author.

E-mail address: martafdzes@hotmail.com

(M. Fernández-Esgueva).

2529-993X/

© 2018 Elsevier España, S.L.U. and Sociedad Española de Enfermedades Infecciosas y Microbiología Clínica. All rights reserved.

Skin lesion and lymphangitis in an immunocompetent patient[☆]



Lesión cutánea y linfangitis en paciente inmunocompetente

This was a 42-year-old patient with no relevant medical history who came to the hospital with a skin lesion on the left leg and feeling shivery. He reported the appearance, two months earlier, of a non-pruritic, scaly erythematous plaque on his left knee. On examination, an infected rounded plaque with desquamating borders was found on the lateral aspect of the left knee with several abscessed points, as well as signs of cellulitis and lymphangitis in the thigh (Fig. 1). Several hard, mobile and painful enlarged lymph nodes were found in the left inguinal region. The patient lived in the country in contact with cows, goats and horses, and reported falling off a horse onto brambles. After prescribing IV treatment with amoxicillin-clavulanic acid, the patient was admitted to the

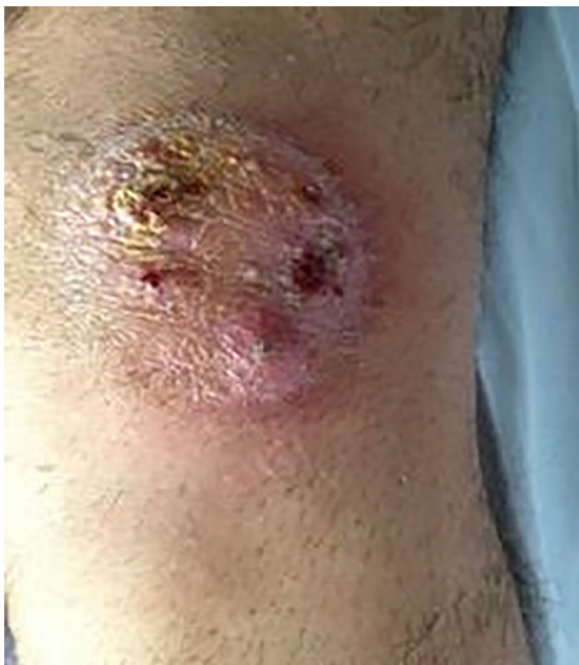

Fig. 1. Infected left knee lesion with desquamating borders.

infectious diseases unit with a differential diagnosis of mycobacterial infection vs nocardiosis. A biopsy of the lesion was taken for histological and microbiological study. A small desquamative erythematous lesion was also found in the right pretibial area, but without signs of infection. The patient was discharged 48 h after admission with amoxicillin-clavulanic acid and cotrimoxazole.

Outcome

After 7–10 days of incubation, the pure growth of a filamentous fungus forming creamy cerebriform colonies was observed in the cultures of exudate, abscess and biopsy from the patient's knee lesion in chocolate agar medium and blood agar at 37 °C (Fig. 2). The antibiotic treatment was therefore discontinued and treatment with oral terbinafine was prescribed. Days later, growth was observed in Sabouraud medium with chloramphenicol and gentamicin at 30 °C. Microscopic examination showed hyphae with chandelier appearance, absence of macroconidia and microconidia, and the presence of long chains of compacted chlamydoconidia suggestive of *Trichophyton verrucosum* (Fig. 3). The histological study showed an inflammatory process in the dermis with follicular destruction and presence of PAS-positive rounded structures, compatible with Majocchi granuloma. After six weeks of treatment, the lesion on the right tibia progressed to cellulitis with small pustular lesions and signs of lymphangitis. In the culture of one of the lesions, *T. verrucosum* was isolated again, with identification confirmed by the sequencing of the ITS region of the rRNA. Finally, after 12 weeks of treatment with terbinafine 250 mg/d, the lesions had

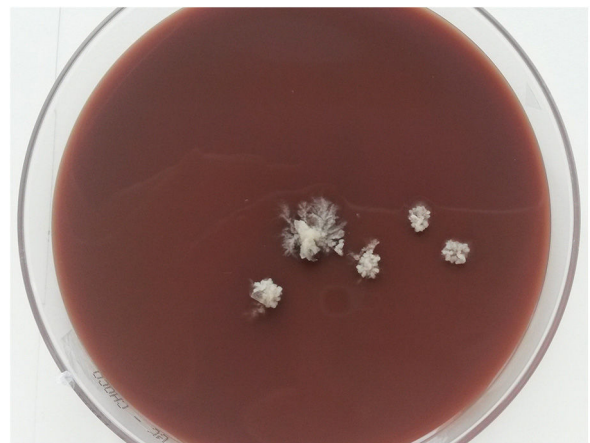

Fig. 2. Cerebriform colonies of *T. verrucosum* in chocolate agar after 10 days of incubation at 37 °C.

DOI of original article: <https://doi.org/10.1016/j.eimc.2018.12.012>.

[☆] Please cite this article as: López-Soria L, Aguirrebengoa Ibarguren K, Ratón Nieto JA, Barrios Andrés JL. Lesión cutánea y linfangitis en paciente inmunocompetente. *Enferm Infecc Microbiol Clin.* 2019;37:481–482.

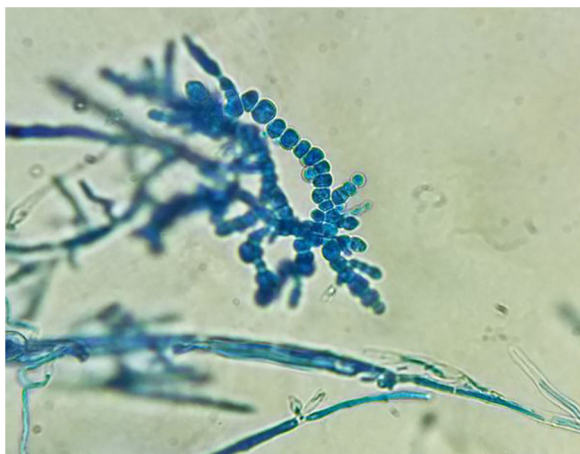


Fig. 3. Chlamydoconidia chains characteristic of *T. verrucosum* in the microscopic examination with lactophenol blue ($\times 40$).

completely disappeared and the patient was discharged with no abnormal laboratory test results.

Comments

Trichophyton verrucosum is a zoophilic dermatophyte fungus of cosmopolitan distribution which causes inflammatory tinea infections through direct or indirect exposure with cattle and less commonly with other animals. The prevalence of the infection in humans varies greatly depending on the geographic area studied^{1,2} and has been related to different milking practices, humidity, hygiene conditions and animal vaccination programmes in the area. The most common forms of clinical presentation are *tinea corporis*, *tinea capitis* and *tinea barbae* (kerion).^{3,4} Majocchi granuloma is a form of dermatophytosis in which the fungus invades the dermis and destroys the hair follicle. It is very uncommon and is usually seen in patients with either trauma or immunosuppression factors, and in these cases it can spread via the lymphatic or vascular systems or by contact.^{5–8} The differential diagnosis of this clinical condition includes infection by *Nocardia* spp., atypical mycobacteria or other mycoses, especially in patients with lesions in the extremities and who spend time in rural areas. The definitive diagnosis is determined by the requirements of the fungus, as the optimum temperature for growth is 37 °C, and it needs media enriched with thiamine or inositol. This means growth is slow and it is not uncommon to detect it in bacteriological media, such as blood, chocolate or BHI agar.⁹ The antifungals most often used for the treatment of these severe forms of dermatophytosis are terbinafine and triazoles, and the duration of treatment is determined by the clinical response and host factors.^{6,10}

In conclusion, we present a rare case of invasive dermatophytosis caused by *T. verrucosum* in an immunocompetent patient, probably acquired through direct contact with a sick animal or spores in the soil or fomites. The inflammatory reaction in mycosis caused by *T. verrucosum* and the difficulty the fungus has in recovering in mycological culture media can lead to the delayed diagnosis of this infection.

References

1. Seebacher C, Bouchara JP, Mignon B. Updates on the epidemiology of dermatophyte infections. *Mycopathologia*. 2008;16:335–52.
2. Chadeganipour M, Mohammadi R, Shadzi S. A 10-year study of dermatophytoses in Isfahan, Iran. *J Clin Lab Anal*. 2016;30:103–7.
3. Courtellemont L, Chevrier S, Degeilh B, Belaz S, Gangneux JP, Robert-Gangneux R. Epidemiology of *Trichophyton verrucosum* infection in Rennes University Hospital, France: a 12-year retrospective study. *Med Mycol*. 2017;55:720–4.
4. Néji S, Makni F, Cheikrouhou F, Sellami H, Trabelsi H, Marrakchi S, et al. Les dermatomycoses à *Trichophyton verrucosum* à Sfax-Tunisie. *J Mycol Med*. 2011;21:198–201.
5. Boral H, Durdu M, Ilkit M. Majocchi's granuloma: current perspectives. *Infect Drug Resist*. 2018;11:751–60.
6. Rouzaud C, Hay R, Chosidow O, Dupin N, Puel A, Lortholary O, et al. Severe dermatophytosis and acquired or innate immunodeficiency: a review. *J Fungi*. 2016;2, <http://dx.doi.org/10.3390/jof2010004>.
7. Lestringant GG, Lindley SK, Hillsdon-Smith J, Bouix G. Deep dermatophytosis to *Trichophyton rubrum* and *T. verrucosum* in an immunosuppressed patient. *Int J Dermatol*. 1988;27:707–9.
8. Tejasvi T, Sharma VK, Sethuraman G, Singh MK, Xess I. Invasive dermatophytosis with lymph node involvement in an immunocompetent patient. *Clin Exp Dermatol*. 2005;30:506–8.
9. Borman AM, Summerbell RC. *Trichophyton*, *Microsporum*, *Epidermophyton*, and agents of superficial mycoses. In Jorgensen JH, Pfaller MA, editors. *Manual of Clinical Microbiology*. Washington: 2015. p. 2128–2152.
10. Rouzaud C, Chosidow O, Brocard A, Fraitag S, Scemla A, Anglicheau D, et al., French Mycoses Study Group. Severe dermatophytosis in solid organ transplant recipients: a French retrospective series and literature review. *Transpl Infect Dis*. 2018;20, <http://dx.doi.org/10.1111/tid.12799>.

Leyre López-Soria^{a,*}, Koldo Aguirrebengoa Ibarguren^b,
Juan Antonio Ratón Nieto^c, José Luis Barrios Andrés^a

^a Servicio de Microbiología, Hospital Universitario Cruces, Barakaldo, Vizcaya, Spain

^b Unidad de Enfermedades Infecciosas, Hospital Universitario Cruces, Barakaldo, Vizcaya, Spain

^c Servicio de Dermatología, Hospital Universitario Cruces, Barakaldo, Vizcaya, Spain

* Corresponding author.

E-mail address: Leyremonica.lopezsoria@osakidetza.eus
(L. López-Soria).

2529-993X/

Published by Elsevier España, S.L.U.