

pathogens are *Staphylococcus* spp. (both *Staphylococcus aureus* and coagulase-negative staphylococci),⁵ cases caused by *Streptococcus bovis* are rare.

In 2016, García-País et al. published a review of cases of osteoarticular infection due to group B streptococci (GBS) reported to date in which they found 11 cases of periprosthetic joint infection due to GBS.³ In 2020, Mayo Clinic published a review of 2459 cases of periprosthetic joint infection and identified GBS as causal in just nine cases, amounting to 0.4% of the total.⁶ In most cases, the species could not be identified; *S. gallolyticus* subsp. *gallolyticus* was identified in four cases. In the majority of the patients, the antibiotic therapy administered consisted of ceftriaxone 2 g/24 h for four to eight weeks. Among those for whom surgery-related data were available, the average time elapsed between the first and the second stage of surgery was 48 weeks.⁶

Our case report corresponds to a late periprosthetic knee infection by *S. gallolyticus* subsp. *gallolyticus*, a very uncommon pathogen in infections of this nature. It was likely of haematogenous origin, given the patient's history of colonic disease with manipulation prior to the onset of her signs and symptoms, since there appears to be a relationship between abnormalities in the intestinal mucosa and periprosthetic joint infection with *S. gallolyticus* subsp. *gallolyticus*. Our patient had a colon tumour as a risk factor when her joint signs and symptoms developed.

Authors

All authors made intellectual contributions to the article and approved the final version thereof.

Conflicts of interest

The authors declare that they have no conflicts of interest.

References

- Corredoira Sánchez J, García Garrote F, Rabuñal R, López Roses L, García País MJ, Castro E, et al. Association between bacteremia due to *Streptococcus gallolyticus* subsp. *Gallolyticus* (*S. bovis* 1) and colorectal cancer: a case-control study. *Clin Infect Dis*. 2012;55:491–6.
- Dekker JP, Lau AF. An Update on the *Streptococcus bovis* group: classification, identification, and disease associations. *J Clin Microbiol*. 2016;54:1694–9.
- García-País MJ, Rabuñal R, Armesto V, López-Reboiro M, García-Garrote F, Coira A, et al. *Streptococcus bovis* septic arthritis and osteomyelitis: a report of 21 cases and a literatura review. *Semin Arthritis Rheum*. 2016;45:738–46.
- Phillips JE, Crane TP, Noy M, Elliot TS, Grimer RJ. The incidence of deep prosthetic infections in a specialist orthopaedic hospital: a 15-year prospective survey. *J Bone Joint Surg Br*. 2006;88:943–8.
- Stefánsdóttir A, Johansson D, Knutson K, Lidgren L, Robertsson O. Microbiology of the infected knee arthroplasty: report from Swedish Knee Arthroplasty Register 426 surgically revised cases. *Scand J Infect Dis*. 2009;41:831–40.
- Thompson JC, Goldman AH, Tande AJ, Osmon DR, Sierra RJ. *Streptococcus bovis* hip and knee periprosthetic joint infections: a series of 9 cases. *J Bone Joint Infect*. 2020;5:1–6.

Raquel Fernández-González^{a,*}, Juan Otero-Villar^b, Rodrigo Estévez-Vilar^b, María Dolores Díaz-López^c

^a Servicio de Medicina Interna, Hospital Universitario de Ourense, Ourense, Spain

^b Servicio de Traumatología, Hospital Universitario de Ourense, Ourense, Spain

^c Unidad de Infecciosas, Servicio de Medicina Interna, Hospital Universitario de Ourense, Ourense, Spain

* Corresponding author.

E-mail address: raquelferngonz@gmail.com

(R. Fernández-González).

<https://doi.org/10.1016/j.eimce.2022.03.008>

2529-993X/ © 2022 Published by Elsevier España, S.L.U.

on behalf of Sociedad Española de Enfermedades Infecciosas y Microbiología Clínica.

***Clostridium difficile* associated reactive arthritis: An unusual clinical case and review of the literature**[☆]



Artritis reactiva asociada a Clostridioides difficile: un caso clínico inusual y revisión de la literatura

We report the case of a 65-year-old man with a history of hypertension, dyslipidaemia and ischaemic cardiomyopathy who visited the accident and emergency department due to diarrhoea for the past three weeks, with 10–12 liquid bowel movements per day with no pathological products or abdominal pain. This was associated with peripheral polyarthritis in the past two weeks, initially in the left knee and ankle and subsequently in the right carpus and first metacarpal bone; fever spikes at 38 °C; and 6 kg of weight loss. Prior to the onset of his signs and symptoms, he had suffered from two urinary tract infections secondary to *Escherichia coli*. These infections had been treated with trimethoprim/sulfamethoxazole for five days. The latter infection had occurred approximately a month earlier. Initial laboratory testing revealed elevated acute-phase reactants with a C-reactive protein level of 19 mg/dl. As inflammatory bowel disease was clinically suspected, the patient was given

corticosteroid therapy (inappropriately, in the absence of an aetiological diagnosis), with initial but only temporary improvement. An outpatient colonoscopy showed areas of erythematous mucosa covered in whitish formations throughout the colon, indicative of infectious disease rather than inflammatory bowel disease (Fig. 1A). Colon biopsy was inconclusive, although it did point to an infectious origin. Given the patient's poor clinical course, with increased numbers of bowel movements and affected joints, and in the absence of an aetiological diagnosis, a decision was made to admit him to hospital.

At the beginning of his hospital stay, laboratory testing showed elevated C-reactive protein (31 mg/dl), an erythrocyte sedimentation rate of 120 mm/h, 17,700 leukocytes/mm³ (75% neutrophils) and normocytic normochromic anaemia of 9.8 g/dl. Abdominal computed tomography was ordered and revealed concentric wall thickening 5 cm long in the sigmoid colon (Fig. 1B). A stool analysis testing for *Clostridioides difficile* found antigen and toxin positivity by means of enzyme immunoassay (glutamate dehydrogenase [GDH], C. Diff Quik Chek Complete[®], Alere). Thus a diagnosis of colitis due to *C. difficile* was confirmed. The rheumatology department was consulted for joint assessment of articular disease. Rheumatology reported symmetric polyarthritis in both elbow, carpal, metacarpophalangeal, proximal interphalangeal, knee, ankle, tarsal and metatarsophalangeal joints. Arthrocentesis of the patient's left knee, in which clear synovial fluid was extracted, with laboratory testing revealing 12,112 leukocytes/mm³ and negative cultures, was consistent with arthritis with inflammatory characteristics. A rheumatoid factor test and serologies for human

DOI of original article: <https://doi.org/10.1016/j.eimc.2021.09.006>.

[☆] Please cite this article as: de los Mozos-Ruano A, Casas-Deza D, Calvo-Galindo R, García-López S. Artritis reactiva asociada a *Clostridioides difficile*: un caso clínico inusual y revisión de la literatura. *Enferm Infecc Microbiol Clin*. 2022;40:338–339.

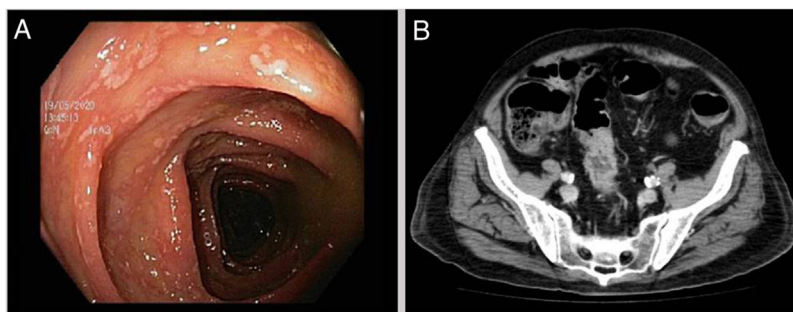


Figure 1. A) Areas of erythematous mucosa covered in whitish formations seen in the colonoscopy prior to admission. B) Concentric wall thickening 5 cm long in the sigmoid colon with signs of mild involvement of perisigmoid fat.

immunodeficiency virus (HIV), syphilis and hepatotropic viruses were negative, and stool culture and urethral discharge both showed no microbiological growth. With other causes having been ruled out, the patient was diagnosed with *C. difficile*-associated reactive arthritis secondary to colitis. After the patient started oral vancomycin 125 mg every six hours for 10 days, non-steroidal anti-inflammatory drugs and corticosteroids (both intra-articular and ultimately systemic, for lack of initial improvement), he followed a satisfactory course in terms of both diarrhoea and joint disease.

Reactive arthritis is commonly associated with genitourinary and gastrointestinal infections caused by *Chlamydia*, *Salmonella*, *Shigella*, *Campylobacter* or *Yersinia*. *C. difficile* is a less recognised cause of colitis, with 50 case reports since the first of them in 1976. Its pathogenesis is probably due to an autoimmune response to bacterial antigens that gain access to the bloodstream through the intestinal mucosa and affect joints and other tissues in genetically predisposed patients.¹ The lapse of time between diarrhoea and arthritis varies (from one to four weeks). It presents as acute migratory polyarthritis of medium and large joints, especially in the legs. The diagnosis is a diagnosis of exclusion, after diseases such as gout, rheumatoid arthritis and other infections that tend to precede reactive arthritis have been ruled out.² The diagnostic criteria proposed by Putterman and Rubinow in 1993 consist of sterile inflammatory arthritis with preceding diarrhoea following prior antibiotic exposure, a positive *C. difficile* test in faeces and the absence of other causes of colitis and arthritis that might account for the process.³ Treatment is based on antibiotic therapy for *C. difficile* infection and analgesics, intra-articular or even systemic corticosteroids, and disease-modifying antirheumatic drugs. In general, the prognosis is good, with complete resolution of symptoms in four to six weeks, and no relapses of joint disease documented to date.⁴

C. difficile-associated reactive arthritis is thought to be potentially underdiagnosed. In conclusion, this case illustrates the importance of including it as a possible causal agent in the evaluation of inflammatory arthritis associated with diarrhoea.

References

1. Marwat A, Mehmood H, Hussain A, Khan M, Ullah A, Joshi M. *Clostridium difficile* colitis leading to reactive arthritis: A rare complication associated with a common disease. *J Investig Med High Impact Case Reports*. 2018;6, 2324709618767689.
2. Legendre P, Lalonde V, Eckert C, Barbut F, Fardet L, Meynard JL, et al. *Clostridium difficile* associated reactive arthritis: Case report and literature review. *Anaerobe*. 2016;38:76–80.
3. Essenmacher AC, Khurram N, Bismack GT. A case of reactive arthritis due to *Clostridium difficile* colitis. *J Community Hosp Intern Med Perspect*. 2016;6:30151.
4. Birnbaum J, Bartlett JG, Gelber AC. *Clostridium difficile*: An under-recognized cause of reactive arthritis? *Clin Rheumatol*. 2008;27:253–5.

Andrea de los Mozos-Ruano^{a,*}, Diego Casas-Deza^b,
Roberto Calvo-Galindo^a, Santiago García-López^c

^a Servicio de Medicina Interna, Hospital Universitario Miguel Servet, Zaragoza, Spain

^b Grupo de investigación Biología del tejido adiposo y complicaciones metabólicas de la obesidad (ADIPOFAT), Servicio de Aparato Digestivo, Hospital Ernest Lluch Martín, Instituto de Investigación Sanitaria (IIS), Calatayud, Zaragoza, Spain

^c Servicio de Aparato Digestivo, Hospital Universitario Miguel Servet, Instituto de Investigación Sanitaria (IIS), Zaragoza, Spain

* Corresponding author.

E-mail address: andri.9495@hotmail.com (A. de los Mozos-Ruano).

<https://doi.org/10.1016/j.eimce.2022.03.004>

2529-993X/ © 2022 Published by Elsevier España, S.L.U.

on behalf of Sociedad Española de Enfermedades Infecciosas y Microbiología Clínica.

Fusarium spp. infection: The importance of an early diagnosis[☆]



Infeción por *Fusarium* spp.: importancia de un diagnóstico temprano

Fusarium spp. is one of the most ubiquitous filamentous fungal pathogens in the world¹. In humans, *Fusarium* species cause localised, locally invasive or disseminated infections. The

main clinical signs include skin compromise, onychomycosis and eye infections such as keratitis and endophthalmitis; the latter may be post-traumatic, due to contamination of contact lenses or due to mould-contaminated ophthalmic solutions, or they may occur in patients with underlying corneal disease who apply topical corticosteroids or use antibiotics². The most susceptible patients are those with severe neutropenia, in particular severe neutropenia caused by haematologic neoplasms or medicines³.

We report a case of *Fusarium* spp. fungal infection with skin lesions in a patient with a history of promyelocytic leukaemia with severe neutropenia. The diagnosis and treatment of this infection prevented the dissemination thereof, despite the presence of risk factors.

[☆] Please cite this article as: Guerrero Arias CA, Marulanda Nieto CJ, Díaz Gómez CJ. Infeción por *Fusarium* spp.: importancia de un diagnóstico temprano. *Enferm Infecc Microbiol Clin*. 2022;40:339–341.