

Laurence Salle<sup>a,\*</sup>, Julie Usseglio<sup>b</sup>, Henri Salle<sup>c</sup>

<sup>a</sup> Department of Endocrinology, Diabetology and Nutrition, University Hospital of Limoges, 2, Avenue Martin Luther King, 87042 Limoges, France

<sup>b</sup> Department of Maxillo-Facial Surgery, University Hospital of Limoges, 2, Avenue Martin Luther King, 87042 Limoges, France

<sup>c</sup> Department of Neurosurgery, University Hospital of Limoges, 2, Avenue Martin Luther King, 87042 Limoges, France

\* Corresponding author.

E-mail address: [laurence.teyssieres@orange.fr](mailto:laurence.teyssieres@orange.fr) (L. Salle).

<https://doi.org/10.1016/j.endinu.2021.01.012>  
2530-0164/ © 2021 SEEN y SED. Published by Elsevier España, S.L.U. All rights reserved.

## Parasitic thyroid nodules: The differential diagnosis



## Nódulos tiroideos parasitarios: diagnóstico diferencial

### Introduction

Ectopic thyroid is a rare entity defined as any thyroid tissue not located in its usual position anterior to the laryngeal cartilages. Most frequent ectopic thyroid is due to the absence of regression from the thyroglossal duct. However, others ectopic thyroid tissues can be found during differential diagnosis of neck nodules.<sup>1</sup> Parasitic thyroid nodules, also called sequestered, detached or accessory thyroid nodule are separated thyroid nodules from the main thyroid gland located in the lateral neck area.<sup>2</sup> Therefore, differential diagnosis of thyroid tissue outside the thyroid gland may involve a complex process.<sup>3</sup> Here, we present a patient with parasitic thyroid nodule.

### Case presentation

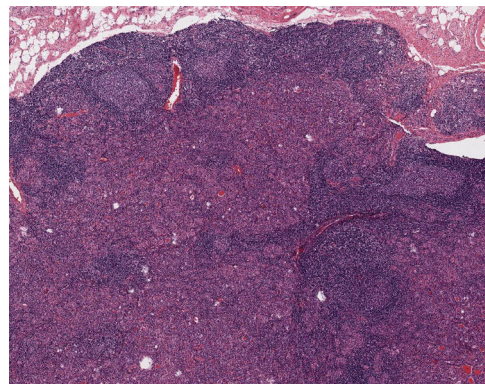
A 49-year-old woman was referred to our department in 2016 due to a goitre detected during a dysphagia differential diagnosis. Cervical ultrasonography discovered a multinodular goitre with a predominant hypervascularised 30 mm isthmus thyroid nodule. Subsequent fine needle aspiration biopsy (FNAB) showed follicular proliferation. Finally, she underwent a total thyroidectomy with histopathological results of lymphocytic thyroiditis and nodular hyperplasia. A single 3 mm papillary thyroid microcarcinoma was discovered incidentally in the right thyroid lobe. During the follow-up, a clinically thyroglobulin (Tg) rise was detected (suppressed Tg from 4.6 to 18 ng/mL) with persistently high anti-Tg antibodies (levels close to 300 U/mL). Consequently, Tg was measured following TSHr stimulation showing a rising to 43 ng/mL. Cervical ultrasonography showed three concurring suspicious bilateral level-IV lymphadenopathies. Patient did not undergo a lymph node FNAB washout for Tg because it was not yet a widely established technique in our hospital. Thus, extended bilateral lymphadenectomy was performed one year later. Histopathology demonstrated no features of malignancy. In the neck dissection, there were sixteen normal lymph nodes and two bilateral nodules (12 mm and 15 mm) of hyperplastic thyroid tissue not related to lymph

nodes. These nodules showed benign histological features with lymphocytic thyroiditis (Fig. 1). There were no nuclear features of papillary thyroid carcinoma. Galectin 3, CK19 and HBME1 immunohistochemistry was negative. Hence, the nodules were classified as benign parasitic nodules.

### Discussion

Our case entailed a complex differential diagnosis of thyroid tissue outside the thyroid gland, finally due to parasitic nodules. The parasitic thyroid nodule occurs when thyroid tissue located in the lateral neck has no relationship or association with the lymph nodes, and may be defined as a thyroid nodule entirely separate from the thyroid or attached to it by a narrow pedicle, presenting the same histology and in the same facial plane as the thyroid, and should not be associated with lymph nodes.<sup>3</sup> About one hundred cases of parasitic thyroid nodules have been described, most of them are single subcentimetric isolated nodules.<sup>4</sup> Patient parasitic thyroid nodules were not associated with lymph nodes or the thyroid gland. Similar histology (lymphocytic thyroiditis) to main thyroid tissue was also confirmed.

The differential diagnosis of the case with two parasitic thyroid nodules proved to be complex and next possible diseases were considered: thyroid rests from embryological origin, metastatic thyroid cancer lymphadenopathies, seeding from prior thyroid surgery and thyroid tissue clefting. Firstly, thyroid rests from embryological origin are often located in the neck midline, whereas our suspicious images were detected in cervical level IV, laterally to



**Figure 1** Thyroid tissue in a lymphoid reactive background with germinal centres (H&E, 40×).

the theoretical line of the thyrothymic tract.<sup>5</sup> Secondly, metastatic thyroid cancer was considered a potential differential diagnosis due to patient previous medical history. When prominent lymphocytic infiltration is observed in a parasitic nodule pathologist must be aware of this rare condition and differentiate from a condition more frequent, a metastatic carcinoma in a lymph node. On occasion this can be very difficult and immunohistochemical techniques can be necessary to solve the problem. In our case, no association of the hyperplastic nodules with lymph node tissue or nuclear features of papillary thyroid carcinoma were observed. Both parasitic thyroid nodules of the same patient showed benign histopathological features and immunohistochemistry for Galactin 3, CK19 and HBME1 were negative.<sup>6</sup> Unfortunately, BRAF and other thyroid cancer gen-mutation studies were not available in our centre at that moment, these techniques would have helped in the patient's clinical management. Another differential diagnosis included thyroid seeding from previous surgery. "Thyroidosis" usually happens in the subcutaneous tissue or in the field of a previous surgery.<sup>7</sup> However, in our case the bilateral neck thyroid nodules were not within the operative field of the original total thyroidectomy which did not include any neck lateral adenopathy dissection. Finally, thyroid tissue scission is a well-known phenomenon accompanying lymphocytic thyroiditis in patients with multinodular goitre. In fact, tissue clefting was found in a recent detailed description of a parasitic thyroid nodule series. It is proposed that the mechanical action of the neck muscles is the main mechanism of these parasitic thyroid nodule's origin, which may separate a portion of the goitre through the muscular fascia.<sup>3</sup> Therefore, our diagnosis considering all the clinical and pathological features, was of two parasitic thyroid nodules probably due to tissue clefting, although thyroidosis origin could not be utterly rejected.

We concluded that parasitic thyroid nodules should be included in the differential diagnosis of lateral neck masses. This rare entity may be the cause of a serious clinical dilemma if an important medical decision is to be made due to a malignant thyroid suspicion.

### Patient consent

Patient signed the informed consent.

### Funding

No funding was received for this work

### Conflict of interest

The authors wish to confirm that there are no known conflicts of interest.

### References

1. Abu-Khudir R, Larrivé-Vanier S, Wasserman JD, Deladoëy J. Disorders of thyroid morphogenesis. *Best Pract Res Clin Endocrinol Metab.* 2017;31:143–59.
2. Rosai J, Kuhn E, Carcangiu ML. Pitfalls in thyroid tumour pathology. *Histopathology.* 2006;49(August):107–20.
3. Barbieri A, Prasad ML, Gilani SM. Thyroid tissue outside the thyroid gland: differential diagnosis and associated diagnostic challenges. *Ann Diagn Pathol.* 2020;48(October):151584.
4. Bychkov A. Parasitic nodules of thyroid: some insights into the origin and early evolution. *Pathology (Phila).* 2019;51(January):125–7.
5. Sackett WR, Reeve TS, Barraclough B, Delbridge L. Thyrothymic thyroid rests: incidence and relationship to the thyroid gland. *J Am Coll Surg.* 2002;195(November):635–40.
6. Baker LJ, Gill AJ, Chan C, Lin BPC, Crawford BA. Parasitic thyroid nodules: cancer or not? *Endocrinol Diabetes Metab Case Rep.* 2014;2014:140027.
7. Harach HR, Cabrera JA, Williams ED. Thyroid implants after surgery and blunt trauma. *Ann Diagn Pathol.* 2004;8(April):61–8.

Jesús Moreno-Fernández<sup>a,\*</sup>, Violeta Herrera Montoro<sup>b</sup>, Rita Virlobo Cebrian<sup>a</sup>, Francisco José Martín Davila<sup>b</sup>

<sup>a</sup> *Endocrinology and Nutrition Department, Ciudad Real General University Hospital, Ciudad Real, Spain*

<sup>b</sup> *Anatomical Pathology Department, Ciudad Real General University Hospital, Ciudad Real, Spain*

\* Corresponding author.

E-mail address: [jmorenof@sescam.jccm.es](mailto:jmorenof@sescam.jccm.es)

(J. Moreno-Fernández).

<https://doi.org/10.1016/j.endinu.2021.02.004>

2530-0164/ © 2021 SEEN y SED. Published by Elsevier España, S.L.U. All rights reserved.

## Presentación clínica inusual y nueva mutación en un caso de síndrome triple A



### Unusual clinical presentation and new mutation in a case of triple A syndrome

El síndrome triple A es un trastorno multisistémico, de herencia autosómica recesiva, originado por mutaciones en el gen AAAS localizado en el cromosoma 12q13 que codifica la proteína ALADIN. Se caracteriza por alacrimia, acalasia e

insuficiencia suprarrenal secundaria a resistencia a hormona adrenocorticotrópica (ACTH).

Presentamos el caso de una mujer de 39 años, que acudió a consultas de Neurología por dificultad para la marcha, presente desde la infancia pero con empeoramiento progresivo en los últimos años. Entre sus antecedentes familiares destaca una hermana con acalasia. Como antecedentes personales presentaba bronquiectasias desde la infancia y cirugía por pies cavos. Su tratamiento consistía en colecalciferol 25.000 UI/mes.

Desde la infancia refería dificultad en la marcha, debilidad de las extremidades, disfagia, diaforesis sin causa