

^a Servicio de Endocrinología y Nutrición, Hospital de Sant Pau, Barcelona, Spain

^b Servicio de Endocrinología y Nutrición, Hospital Clinic i Provincial de Barcelona, Spain

^c Servicio de Endocrinología y Nutrición, Hospital Universitario Ramón y Cajal, Madrid, Spain

^d Servicio de Endocrinología y Nutrición, Hospital Universitari Parc Taulí, Sabadell, Spain

^e Servicio de Endocrinología y Nutrición, Hospital Universitario de Burgos, Spain

^f Servicio de Endocrinología y Nutrición, Hospital Montecelo, Pontevedra, Spain

^g Servicio de Endocrinología y Nutrición, Hospital Clínico Universitario, Valencia, Spain

^h Servicio de Endocrinología y Nutrición, Hospital Universitario Virgen de la Victoria, Málaga, Spain

ⁱ Servicio de Endocrinología y Nutrición, Hospital Universitario Central de Asturias, Oviedo, Spain

^j Servicio de Endocrinología y Nutrición, Hospital Universitari Son Espases, Palma de Mallorca, Spain

^k Departamento Médico, Departamento Médico, Amgen, S.A., Spain

* Corresponding author.

E-mail address: aperez@santpau.cat (A. Pérez Pérez).

<https://doi.org/10.1016/j.endien.2021.07.002>
2530-0180/ © 2021 Published by Elsevier España, S.L.U. on behalf of SEEN and SED.

Likely impact of COVID-19 on referrals to pediatric endocrinology: Increased incidence of precocious puberty in a third-level hospital



Probable impacto de la COVID-19 sobre las derivaciones a endocrinología infantil: aumento de incidencia de pubertad precoz en un hospital de tercer nivel

The first case of coronavirus disease 2019 (COVID-19) was detected in Wuhan (China) in December 2019; from then, it started to spread throughout the world. Confirmed cases and deaths shot up rapidly,¹ taking an emotional toll on the population, with symptoms of anxiety, stress and depression.²

In Spain, schools shut down between 9 March and 13 March 2020. On 14 March, a state of alarm was declared, and on 16 March, the population was put in lockdown. On 5 April 2020, 130,759 cases of COVID-19 had been recorded in Spain, 1,200,000 cases had been confirmed worldwide and more than 68,000 people had died.¹ Spain became the country with the third largest number of people affected by this pandemic in the world.

For many citizens, this was their first social and health-care emergency, caused by a viral agent, giving rise to a great deal of uncertainty and adverse health consequences.¹

The pandemic might have prompted a change in the type and number of referrals to different specialisations; therefore, we set out to determine whether there was a decrease or delay in referrals to paediatric endocrinology at a tertiary hospital, as well as their distribution. To this was added a subjective impression among paediatric endocrinology staff of an increase in the number of referrals for precocious puberty, which made it necessary to confirm whether the pandemic was influencing the time of onset of puberty, as a third objective.

We conducted a retrospective case-control study with non-probability consecutive sampling of children under 14 years of age first referred from primary and specialised care to the paediatric endocrinology department of a ter-

tiary hospital between March 2019 and December 2019 or March 2020 to December 2020, recorded in the consultation software program.

Data were collected on all primary and secondary diagnoses from the first visit, as well as the month of referral.

The criteria used for patient selection were:

- Inclusion criteria: children under 14 years of age first referred to the paediatric endocrinology department at our hospital during an 18-month period.
- Exclusion criteria: age over 14 years, false first visits and duplicate referrals for a single patient.

Statistical analysis consisting of comparison of independent means was carried out using R software. The inferential test of normality using the Shapiro-Wilk test was applied in advance.

In 2019, there were a total of 598 referrals to the paediatric endocrinology department meeting the established criteria (control group), whereas in 2020, there were a total of 471 referrals in the same time period.

The most common reasons for referral during the control period were: short stature 37.5% (224/598), obesity 17.4% (104/598) and hypothyroidism 15.4% (92/598); the most common reasons for referral in the 2020 case group were: short stature 27.8% (131/471), precocious puberty 18.5% (87/471) and hypothyroidism 14% (66/471) (Fig. 1).

Given that these were normal samples, the differences between all the reasons for referral were analysed using Student's t test, yielding statistical significance for short stature ($p=0.0019$), obesity ($p=0.0002$), precocious puberty ($p=0.0092$) and bone mineral density abnormalities ($p=0.0328$).

A homogeneous distribution in referrals in 2019 was seen, with a decrease during the holiday months, whereas in 2020 there was a predominance of referrals in the final three months of the year.

Lockdowns, school closures and the need for social distancing led to less exercise, less healthy eating and longer periods of time at home and in front of screens.³ In addition, anxiety and financial concerns among parents, along with fears of becoming ill, might have caused stress in children.⁴

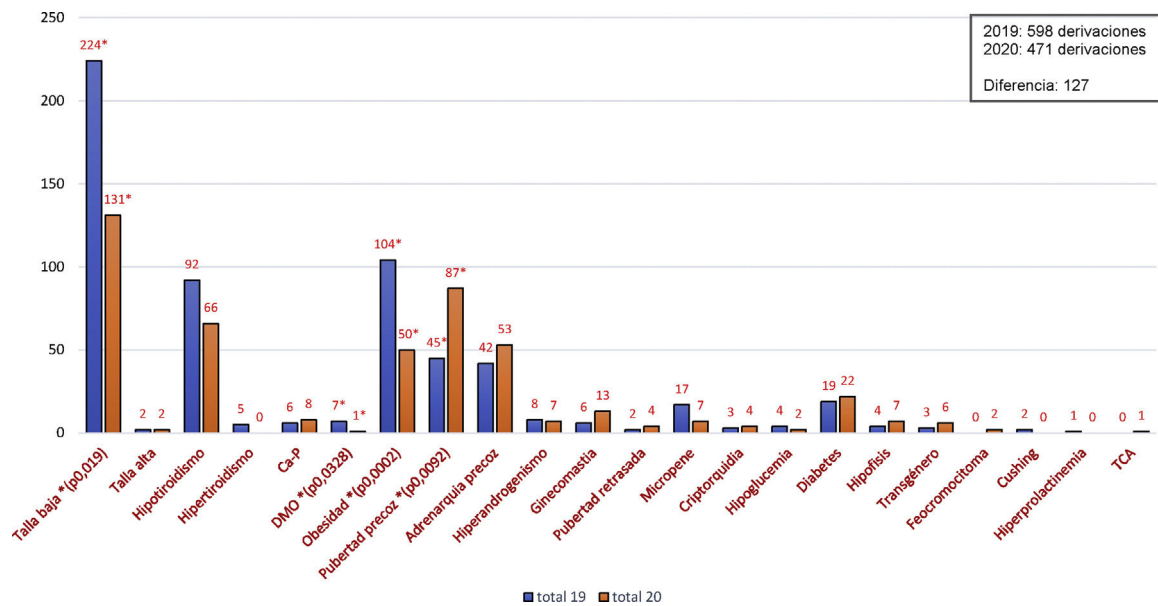


Figure 1 Reasons for consultation in the paediatric endocrinology department at a tertiary hospital expressed in terms of percentages. BMD: bone mineral density; Ca-P: calcium-phosphorus metabolism; ED: eating disorder. * $p < 0.05$.

These psychological and environmental factors stimulate insulin-like growth factor, glucose and leptin, and inhibit melatonin, which can stimulate gonadotropin-releasing hormone (GnRH), a hormone released by hypothalamic neurons.^{5,6} In addition, increased sedentary behaviours are correlated with elevated body mass index, which in turn induces puberty.^{7,8} In our case, although referrals for obesity decreased, there was a subjective sense of an increase in weight of the patients seen.

Backing this theory was the finding in our practice of an increase in referrals for precocious puberty, as in Italian groups.^{9,10} Verzani et al. presented a sample of both sexes larger than our own ($n=224$), but arrived at the same conclusions,⁹ while Stagi et al. had a smaller sample than ours ($n=37$) consisting of females only.¹⁰ However, Stagi et al. found that the new cases of precocious puberty occurred at a younger age with a higher luteinising hormone and oestradiol peak, a higher ovarian volume, a larger uterus and a more advanced Tanner stage at diagnosis than in the control group. They also reported a more rapid course of puberty in cases that were premature, already known and diagnosed prior to the pandemic.⁹ Finally, they indicated an increased body mass index and greater use of technological devices in the control group; this would support our hypothesis on the impact of these things during the pandemic as a trigger of puberty.¹⁰ This was part of one of the limitations of our study, since we were unable to verify an increase in body mass index in the entirety of our control group due to information bias.

In conclusion, our sample showed a significant increase in new cases of precocious puberty during the COVID-19 pandemic. In addition, referrals for short stature, obesity and osteoporosis decreased in our department in 2020, and the distribution of referrals during 2020 varied, with an increase in the final months of the year.

Authorship

Ana B. Ariza Jimenez designed and drafted the article. Francisco J. Aguilar Gomez Cardenas helped with data collection. Carmen de la Camara Moraño supervised the article. All the authors reviewed this manuscript, assume full responsibility for it and approve its publication.

Conflicts of interest

The authors declare that they have no conflicts of interest.

References

1. Odriozola-González P, Planchuelo-Gómez Á, Iurrtia MJ, de Luis-García R. Psychological effects of the COVID-19 outbreak and lockdown among students and workers of a Spanish university. *Psychiatry Res.* 2020;290:113108, <http://dx.doi.org/10.1016/j.psychres.2020.113108>.
2. Wang C, Pan R, Wan X, Tan Y, Xu L, Ho CS, Ho RC. Immediate psychological responses and associated factors during the initial stage of the 2019 coronavirus disease (COVID-19) epidemic among the general population in China. *Int J Environ Res Public Health.* 2020;17:1729, <http://dx.doi.org/10.3390/ijerph17051729>.
3. Gallè F, Sabella EA, Ferracuti S, De Giglio O, Caggiano G, Protano C, et al. Sedentary behaviors and physical activity of Italian undergraduate students during lockdown at the time of CoViD-19 pandemic. *Int J Environ Res Public Health.* 2020;17:6171, <http://dx.doi.org/10.3390/ijerph17176171>.
4. Xie X, Xue Q, Zhou Y, Zhu K, Liu Q, Zhang J, et al. Mental health status among children in home confinement during the coronavirus disease 2019 outbreak in Hubei Province, China. *JAMA Pediatr.* 2020:e201619, <http://dx.doi.org/10.1001/jamapediatrics.2020.1619>.

5. Hadinia SH, Carneiro PRO, Fitzsimmons CJ, Bédécarrats GY, Zuidhof MJ. Post-photostimulation energy intake accelerated pubertal development in broiler breeder pullets. *Poult Sci*. 2020;99:2215–29.
6. Zhang L, Zhang D, Sun Y. Adverse childhood experiences and early pubertal timing among girls: a meta-analysis. *Int J Environ Res Public Health*. 2019;16:2887, <http://dx.doi.org/10.3390/ijerph16162887>.
7. Gaveta-Pérez T, Garcés C, Navarro-Sánchez P, López Villanueva L, Soriano-Guillén L. Earlier menarcheal age in Spanish girls is related with an increase in body mass index between pre-pubertal school age and adolescence. *Pediatr Obes*. 2015;10:410–5.
8. Brix N, Ernst A, Lauridsen LLB, Parner ET, Arah OA, Olsen J, et al. Childhood overweight and obesity and timing of puberty in boys and girls: cohort and sibling-matched analyses. *Int J Epidemiol*. 2020;49:834–44.
9. Verzani M, Bizzarri C, Chioma L, Bottaro G, Pedicelli S, Cappa M. Impact of COVID-19 pandemic lockdown on early onset of puberty: experience of an Italian tertiary center. *Ital J Pediatr*. 2021;47:52.
10. Stagi S, De Masi S, Bencini E, Losi S, Paci S, Parpagnoli M, et al. Increased incidence of precocious and accelerated puberty in females during and after the Italian lockdown for the coronavirus 2019 (COVID-19) pandemic. *Ital J Pediatr*. 2020;46:165, <http://dx.doi.org/10.1186/s13052-020-00931-3>.

Ana Belén Ariza Jimenez*, Francisco Javier Aguilar Gomez-Cardenas, Carmen de la Camara Moraño

Sección de Endocrinología Infantil, Unidad de Gestión Clínica de Pediatría, Hospital Universitario Reina Sofía, Córdoba, Spain

*Corresponding author.

E-mail address: micodemasa@hotmail.com (A.B. Ariza Jimenez).

<https://doi.org/10.1016/j.endien.2022.07.002>
2530-0180/ © 2021 Published by Elsevier España, S.L.U. on behalf of SEEN and SED.

Symptomatic salivary gland choristoma of the pituitary gland



Coristoma de glándula salival sintomático de la hipófisis

Dear Editor,

Choristoma or heteropia is a congenital anomaly consisting of a heterotopic remnant of cells or microscopically normal tissues, i.e., a growth of normal tissue in an abnormal location. This heterotopic remnants can contain different types of cells or tissues in different tissues or organs of the body. Heterotopic remnants are usually of little importance, but can be confused clinically with neoplasms.

Pituitary choristoma is rare. Heterotopic remnants in the pituitary gland have been reported in both anterior and posterior pituitary.¹ Foci of ganglionic cells have been found in the neurohypophysis.² On the other hand, focal squamous epithelia in the anterior pituitary is a common finding but it is rather metaplastic from parenchymal cells than ectopic tissue.³ Lastly, small foci of ectopic salivary gland tissue have been demonstrated in the posterior lobe of pituitary glands.⁴

Intrasellar symptomatic salivary gland is very rare although it could be considered in the differential diagnosis of intrasellar masses.⁵ We report a new case of symptomatic pituitary salivary gland choristoma and discuss the most relevant aspects of this pathology in relation to the prevalence, clinical diagnosis and therapeutic outcomes.

A 71-year-old man underwent surgery for a sellar-suprasellar lesion after consulting for severe headache for 7 days and binocular diplopia of several hours of evolution. Visual campimetry was consistent with chronic bilateral glaucoma and less likely with incongruous right homonymous hemianopia. Bitemporal hemianopia

was ruled out. The fundus was normal. Preoperative hormonal evaluation showed the presence of hypopituitarism (gonadotropins, GH, TSH and ACTH deficiency). PRL was normal (5.8 ng/ml). Pituitary MRI showed a large expansive mass (26 mm × 28 mm × 17 mm) in sellar region suggestive of macroadenoma with extension mainly to the right cavernous sinus and to the left suprasellar region with significant compression of the optic tract and hypothalamic structures (Fig. 1A and B). The postoperative period was favorable with an improvement in headache and previous diplopia. No cerebrospinal fluid fistula or diabetes insipidus was developed. The patient was discharged on replacement hormonal treatment with hydrocortisone, levothyroxine and testosterone. The histopathological study was compatible with sellar choristoma of salivary gland (Fig. 1B-D).

Salivary gland ectopy has been documented in multiple organs and body tissues. The intrasellar location of the salivary glands generally occurs asymptomatic, having been reported in up to 3.4% in autopsy studies.⁴ In exceptional cases, these ectopic embryonic remnants can present symptomatically. To date, fewer than 15 cases have been described.⁵

Two possible explanations have been considered to explain the development of salivary gland tissue in the pituitary.⁵ On the one hand, during embryogenesis, the salivary gland developed from the primitive epithelium of the oral cavity would be transferred to the sellar region within the wall of Rathke's pouch, which migrates from the primitive oral cavity toward the base of the brain and fuses with an extension of the third ventricle to form the pituitary gland. Another possible explanation would be the transformation of the primitive epithelium of the hypophysis into salivary gland tissue during human embryogenesis.

The clinical course of pituitary salivary ectopia is generally benign, although these remnants may show progressive growth due to active mucous secretion within the ectopic glands. In addition, there is the possibility of a neoplastic