



## Original article

# Relationship of nerve diameter using S-100 immunohistochemistry with Hirschsprung-associated enterocolitis degrees<sup>☆</sup>



Yelisa Tanete Patandianan<sup>a</sup>, Farid Nurmantu<sup>b</sup>, Nita Mariana<sup>b,\*</sup>, Upik Andriani Miskad<sup>c</sup>, Andi Alfian Zainuddin<sup>d</sup>, Ahmadwirawan<sup>b</sup>, Sulmiati<sup>b</sup>, Tommy Rubiyanto Habar<sup>b</sup>, M. Ihwan Kusuma<sup>a</sup>, Prihantono<sup>a</sup>, Muhammad Faruk<sup>a</sup>

<sup>a</sup> Department of Surgery, Faculty of Medicine, Hasanuddin University, Makassar, Indonesia

<sup>b</sup> Division of Pediatric Surgery, Department of Surgery, Faculty of Medicine, Hasanuddin University, Makassar, Indonesia

<sup>c</sup> Department of Pathology Anatomy, Faculty of Medicine, Hasanuddin University, Makassar, Indonesia

<sup>d</sup> Department of Public Health, Faculty of Medicine, Hasanuddin University, Makassar, Indonesia

## ARTICLE INFO

## Article history:

Received 24 September 2020

Accepted 15 October 2020

## Keywords:

Hirschsprung disease

Hirschsprung-associated enterocolitis

Histopathology

Nerve diameter

## ABSTRACT

**Introduction:** Hirschsprung-associated enterocolitis (HAEC) is a complication with a multifactorial etiology that can cause morbidity and mortality in patients with Hirschsprung disease (HSCR). The histopathological degree of HAEC according to Teitelbaum's criteria can be used to predict the clinical development of HAEC. S-100 immunohistochemistry identifies enteric ganglion cells and nerve cell proliferation, the absence of ganglion cells, and hypertrophy of nerve fibers – all features of HSCR.

**Methods:** Patients were children with HSCR who underwent leveling colostomy or a pull-through procedure; this sample came from the ganglionic segment of dilatation in the distal zone. The histopathological grade of HAEC was examined, and the size of the nerve diameter was measured by immunohistochemical S-100. Data were analyzed with the Spearman rank test and the Fisher's exact test.

**Results:** This study had 26 samples, dominated by boys (73.1%) and the age group 2–3 years (38.5%). The histopathological class distribution was reasonably fair except for class V, where no sample was found in this group. Measurement of the dominant nerve diameter was a size of  $\geq 40 \mu\text{m}$  (84.6%). Statistically, the *p*-value was not significant to confirm the relationship between histopathological class size and size of nerve diameter ( $r=0.067$ ).

**Conclusion:** If the diameter of the nerve experiencing hypertrophy is higher, the risk of HAEC is greater, but this relationship is not statistically significant.

© 2021 The Authors. Published by Elsevier España, S.L.U. This is an open access article under the CC BY-NC-ND license (<http://creativecommons.org/licenses/by-nc-nd/4.0/>).

## Introduction

Hirschsprung disease (HSCR), or congenital aganglionic megacolon, is a condition that involves functional intestinal obstruction in part or all of the colon at the aganglion level. HSCR occurs due to the failure of cephalocaudal migration of ganglion cells in the 12th week of pregnancy. The development of intrinsic components in the enteric nervous system is abnormal and characterized by the absence of ganglion cells in the myenteric plexus and the submucosa in the distal intestine. These cells are

responsible for normal peristalsis.<sup>1</sup> A fatal complication of HSCR is Hirschsprung-associated enterocolitis (HAEC), the most significant and potentially life-threatening cause of morbidity and mortality due to HSCR. Due to the difficulty in diagnosis, a high level of wariness is required when dealing with HSCR, as it is currently still a significant challenge for pediatric surgeons and paediatricians.<sup>2</sup>

HAEC is a complication of HSCR, with clinical manifestations ranging from mild symptoms – such as mild abdominal distension, watery stools with perianal excision, and fever – to severe symptoms – which include explosive diarrhea, foul-smelling diarrhea, and loose stools accompanied by blood, vomiting, lethargy, and shock due to the life-threatening toxic megacolon characterizing HSCR.<sup>3</sup> HAEC incidence was found to vary, from 6 to 26% before and 5 to 42% after diversion or definitive resection of the aganglionic bowel; this variance might be due to an overlap of symptoms with other pathological conditions, as well as differences in standards for diagnosing HAEC.<sup>4</sup>

<sup>☆</sup> Peer-review under responsibility of the scientific committee of the Technology Enhanced Medical Education International Conference (THEME 2019). Full-text and the content of it is under responsibility of authors of the article.

\* Corresponding author.

E-mail address: [nita.el.suhel@gmail.com](mailto:nita.el.suhel@gmail.com) (N. Mariana).

**Table 1**  
Patient characteristics.

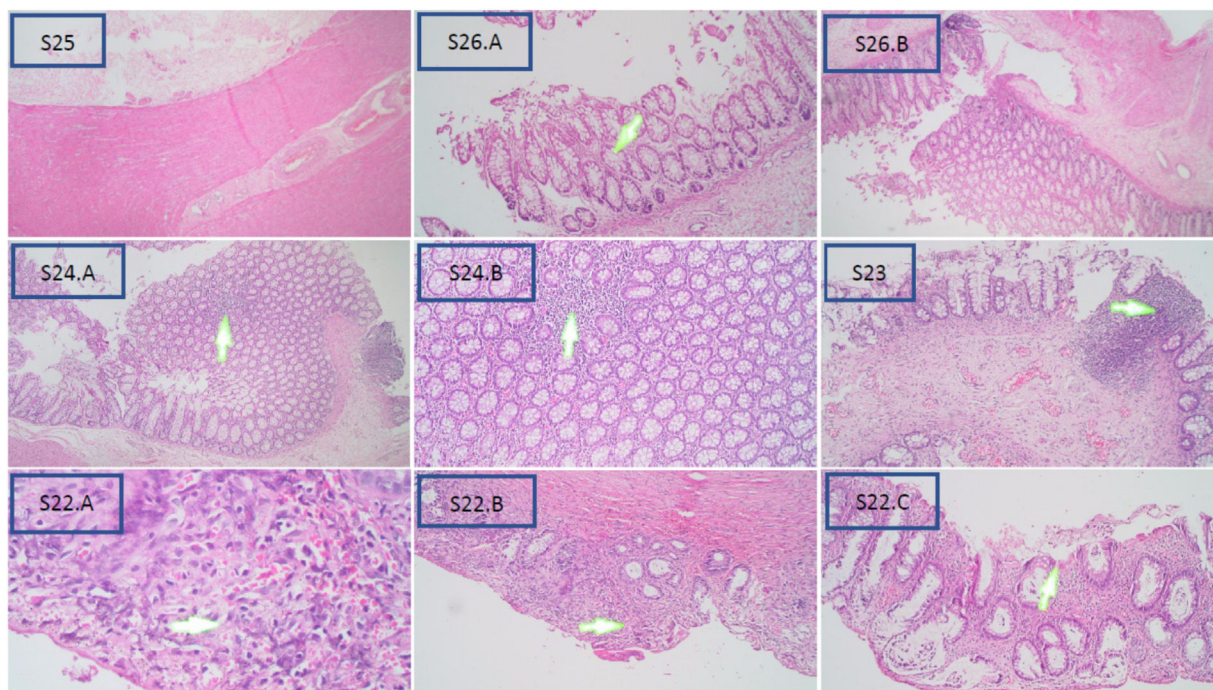
Variable	Number (n=26)	Percentage (%)
<i>Gender</i>		
Boy	19	73.1
Girl	7	26.9
<i>Age (years)</i>		
≤1	8	30.8
2-3	10	38.5
4-5	5	19.2
>5	3	11.5
<i>HAEC histopathology grade</i>		
0	3	11.5
I	7	26.9
II	6	23.1
III	4	15.4
IV	6	23.1
V	0	0.0
<i>Type of operation</i>		
Leveling colostomy	6	23.0
Pull-through procedure	20	77.0
<i>Nerve diameter</i>		
Hypertrophy (≥40 μm)	22	84.6
Non-hypertrophy (<40 μm)	4	15.4

Although several hypotheses have been posited as to its etiopathogenesis, HAEC's biological mechanism is still unknown. Various biomechanisms have been described, ranging from the level of gene expression to a biochemical imbalance in the digestive tract that causes complex disorders. Colon obstruction appears as histopathologic changes in the structure of the intestinal wall. Another supported theory is that changes in the mucin ratio in the colonic mucosa can predispose it to microorganism infection, increasing the incidence of infection.<sup>5,6</sup> Teitelbaum et al. propose that patients with HAEC will experience significant changes in their intestinal tissue, which is characterized by mucin retention and dilatation of crypts that become the basis of the classification of a histopathologic HAEC.<sup>5</sup>

Speedy, accurate diagnosis is the primary key in handling this disease. With the right diagnosis obtained quickly, young patients can get the therapy they need to prevent further complications.<sup>1</sup> However, until now, an examination of the primary essential pathology is used to diagnose this disease. Unfortunately, the examination of enteric ganglion cells is a separate problem faced by pathologists<sup>7</sup>; therefore, a much simpler method of identification is needed. Immunohistochemical examination is an alternative approach with strong potential for diagnosing this disease. In the S-100 immunohistochemical method, the ganglion cells are negatively colored, and the size of the nerve diameter is  $\mu$  40 μm.<sup>8</sup> Nerve cells undergoing proliferation are colored using this method. An absence of ganglion cells and a discovery of hypertrophy from nerve fibers indicates HSCR. It has been previously reported that 90% of patients with HSCR showed a nerve diameter  $\geq$ 40 μm.<sup>9</sup> We hypothesize that there is a relationship between the severity of the histopathological grade and the size of nerve diameters. To evaluate this hypothesis, we conducted a study to identify a correlation between the histopathological level of enterocolitis and the size of nerve fiber diameters.

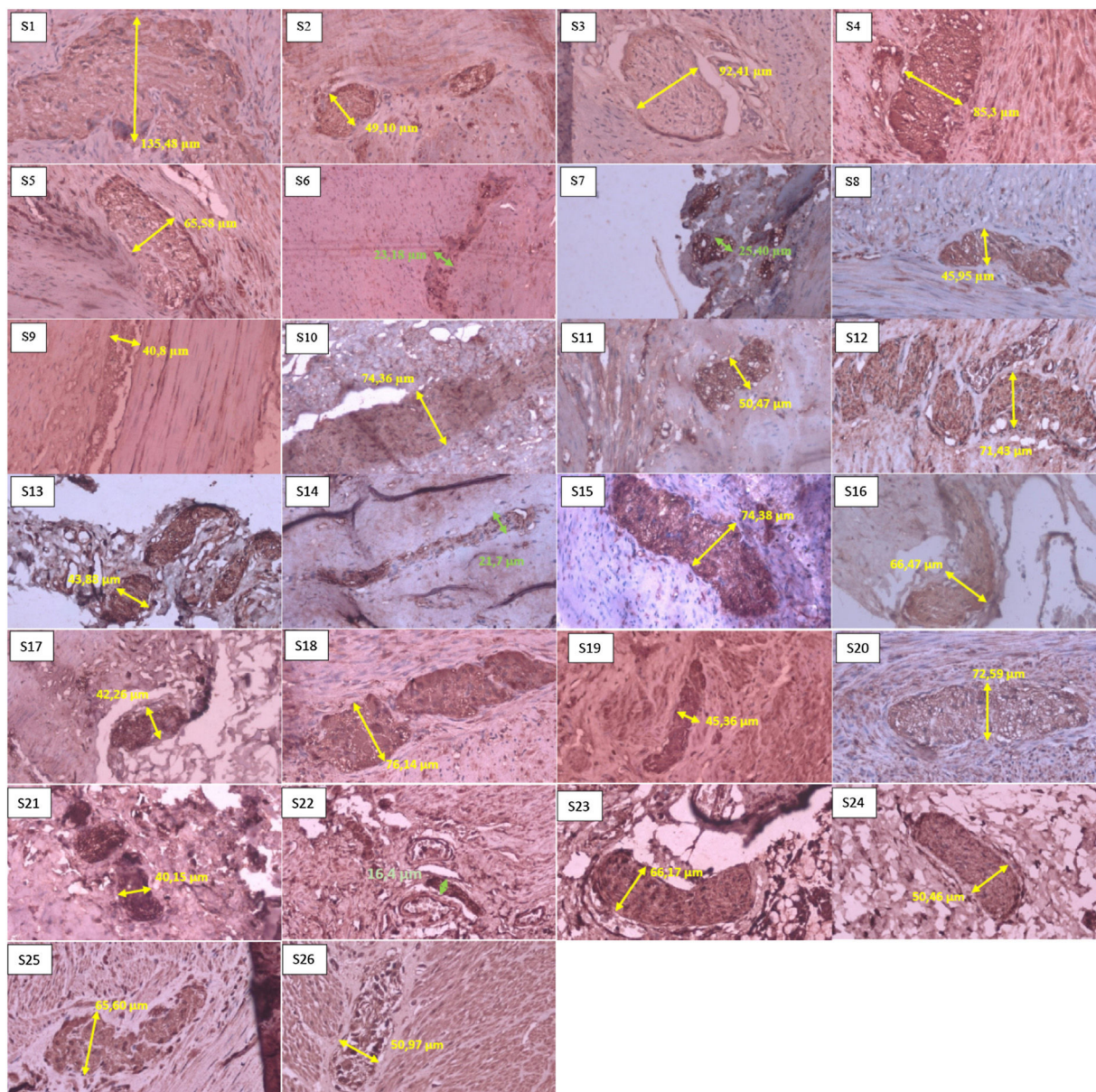
**Methods**

We conducted a cross-sectional study with consecutive sampling using children with HSCR who were confirmed by histopathological examination to have HAEC. The study took place in the Dr. Wahidin Sudirohusodo Hospital in Makassar, Indonesia from December 2019 to April 2020. The HSCR diagnosis was confirmed by the results of a rectal biopsy before a leveling colostomy or pull-through procedure was performed. Intestinal samples were collected intraoperatively and were histopathologically assessed based on Teitelbaum's HAEC classification (hematoxylin and eosin staining under a light microscope). Our sample was taken in the distal zone of the dilatation. The inclusion criteria for the study consisted of all pediatric HSCR patients age  $\leq$ 18 years whose diagnoses were proven based on the results of biopsy pathology of full-thickness rectal anatomy and whose HAEC were confirmed with colonic histopathology based on the Teitelbaum criteria (grade



**Fig. 1.** Representative of a sample with histopathological HAEC rank (hematoxylin–eosin staining, 4×).





**Fig. 2.** Sample of neural hypertrophy diameter measurement using S-100 immunohistochemistry, with 40× magnification. The green line shows the diameter of a nerve that does not experience hypertrophy (nerve diameter < 40 μm). In comparison, the yellow line shows the diameter of a nerve that experiences hypertrophy (nerve diameter ≥ 40 μm).

IV) and with size of nerve diameter (determined by immunohistochemistry S-100) when a leveling colostomy or pull-through procedure was performed. The exclusion criteria consisted of an HSCR patient only undergoing barium enema examination, and an examination of damaged histopathological tissue. For this study, the HAEC degree was established through histopathological diagnosis and then related to the results of the nerve diameter measurements. The Institutional Ethics Committee approved this study. The collected data were compared using the Spearman rank test and the Fisher's exact test. Statistical analysis was performed using SPSS version 24.0 for Windows, and a *p*-value of ≤0.05 was considered statistically significant.

**Results**

Twenty-eight colon tissue samples were taken from patients undergoing leveling colostomy diversion or definitive pull-through surgery at our institution and were used for histopathological

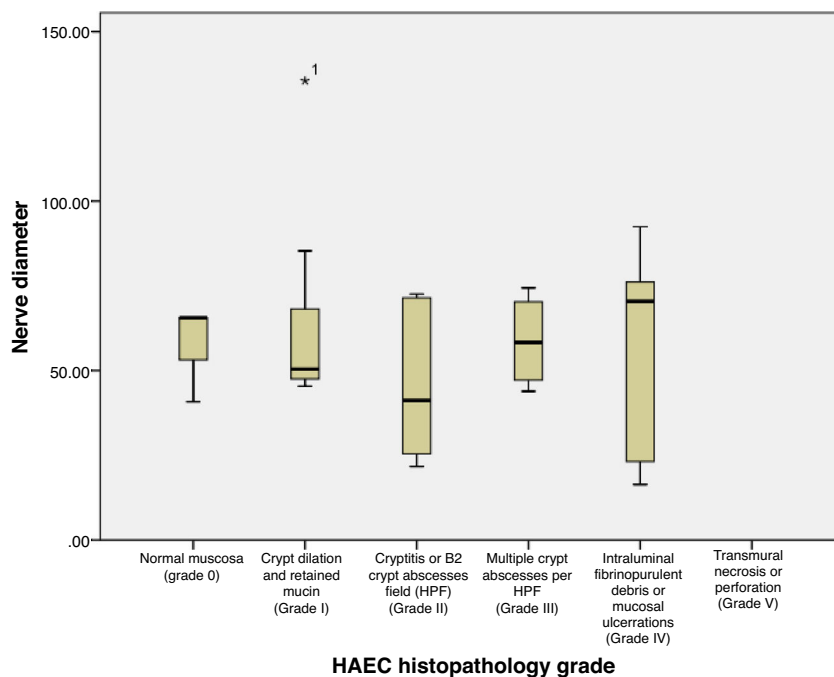
examination. The diameter of nerve hypertrophy was measured using S-100 immunohistochemistry in order to analyze the relationship with the severity of HAEC. During the measurement of nerve diameter with S-100 immunohistochemistry, two obtained samples were damaged during the measurement process; these were excluded from this study, leading to a total sample population of 26 tissue samples. The majority of the sample population were boys (*n* = 19) (73.1%); the ages of the population ranged from 5 months to 14 years, although the dominant age at the time of the surgical procedure was 2–3 years. The sample population is categorized into four age groups. Demographic details and characteristics of the study population are provided in [Table 1](#).

Based on the Teitelbaum classification ([Fig. 1](#)), S25 is grade 0 and shows no abnormalities; S26 is class I and represents a widening crypt (A) and retention of mucin (B); S24 is class II and is characterized by cryptitis, or two crypt abscesses at enlargement 4× (A) and 10× (B); S23 is grade III and is considered as womb multiple crypt abscesses; and S22 is grade IV, with fibrinopurulent debris (A) and

**Table 2**  
The relationship of nerve diameter to the degree of histopathology of HAEC.

Measurement	Histopathology grade					Total	p*	r
	0	1	2	3	4			
Mean	57.32	68.69	45.58	57.07	58.16	57.38	0.745	0.067
Standard deviation	14.31	36.04	21.98	12.68	30.96	25.58		
Median	65.58	50.03	41.20	50.47	70.41	50.72		
Minimum	40.80	45.36	21.70	43.88	16.40	16.40		
Maximum	65.60	135.48	72.59	74.38	92.41	135.48		

\* Spearman's rank test.



**Fig. 3.** Relationships between diameter nerve and degree of histopathological HAEC.

4× (B) and 10× (C) enlarged mucosal ulcerations. Grade V was not obtained in this study, which would process transluminal necrosis or perforation in this sample.

In the histopathological examination results, the most samples in one grader were in grade I with seven samples (26.9%), then in grades II and IV with six samples (23.1%); we had no samples in grade V, based on the Teitelbaum classification. In the results of measuring nerve diameter with immunohistochemical S-100, using a cut-off value of ≥40 μm as a reference value for nerve enlargement. We found that 22 patients (84.6%) experienced neurological hypertrophy, while four patients (15.4%) did not have an enlarged nerve diameter (Fig. 2).

Based on Table 2 and Fig. 3, the mean ±SD of nerve diameter measurements was 57.38 ± 25.58, with the smallest nerve diameter at 16.40 μm and the largest at 135.48 μm. The above results indicate that there is no significant relationship between the size of the nerve diameter and the histopathological grade, with a correlation coefficient of r = 0.067. Furthermore, when nerve diameters and HAEC grade were divided into two groups and a Fisher's exact test was conducted, no significant relationship was seen (p = 0.136) (Table 3).

**Discussion**

Hypertrophic nerve fibers have long been known as a additional way to confirm HSCR. Several previous studies have proven that a confirmed hypertrophic submucosal nerve diameter is highly

**Table 3**  
The relationship of nerve diameter to the degree of histopathology of HAEC.

	Histopathology HAEC score		p*
	Grade < III	Grade ≥ III	
<i>Nerve fiber diameter</i>			0.136
Hypertrophy	0 (0%)	4 (100%)	
Non-hypertrophy	10 (45.5%)	12 (54.5%)	
<b>Total</b>	<b>10 (38.5%)</b>	<b>16 (61.5%)</b>	

\* Fisher's exact test.

correlated with HSCR. Measurement of nerve diameter can be used in conjunction with clinical symptoms when diagnosing a transition zone pull-through.<sup>10,11</sup> In our study, using ≥40 μm as the cut-off value for enlargement of the nerve (Fig. 3), we found that 84.6% of samples had neuronal hypertrophy, either in the distal zone of the dilatation or more proximal to the transition zone during pull-through or leveling colostomy, which we considered ganglionic.

According to Kapur, standard ≥40 μm nerve fibers are normal in the distal rectum after one year of age<sup>12</sup>; therefore, diagnosing transition zone pull-throughs based on nerve fibers of > 40 μm is unreliable among children older than one year,<sup>13,14</sup> the submucosal nerve becomes larger and moves more into the distal rectum as children age, as well as move higher in the rectum than in the colon (which is more proximal at any age).<sup>13,15</sup>



We had two patients with high degrees of HAEC but with a nerve diameter of  $<40 \mu\text{m}$ . These results may be due to how nerve size cut-off values are determined (based on an age of three years) along with the biopsy's location in the colon, or possibly due to histopathological changes in HAEC. It has been reported that the cut-off value is only  $40 \mu\text{m}$  in the submucosal plexus,<sup>16</sup> which has a smaller ganglion than the myenteric plexus.<sup>17</sup> One explanation could be that myenteric nerve bonds are more related to intestinal motility, while submucosal nerves mainly have a secretory function. Therefore, it is expected that if this ( $40 \mu\text{m}$ ) is limit value for the submucosal plexus, a higher limit value is expected for myenteric plexus ( $68 \mu\text{m}$ ).<sup>16</sup> However, some previous studies have used a cut-off value of  $>40 \mu\text{m}$  to explain neural hypertrophy in both the submucosal and myenteric plexuses, as these ganglion cells are often obtained together and overlap in both plexuses.<sup>18</sup>

Although pathologists around the world agree that the basis for establishing an HSCR diagnosis depends on the presence or absence of ganglion cells and on hypertrophy of the nerve, the results of our study indicate that the presence or absence of hypertrophy from the nerve stem is not significant to determine on its own a correlation to varying degrees of HAEC scores. This is likely because the diameter of nerve fibers seems to change with age.<sup>14</sup> Another study has found that histopathological changes in HAEC can not only occur in the aganglionic and transitional segments, but also affect the intestinal ganglionic segments in HSCR. This abnormality can last for a long time or can be permanent and susceptible to the incidence of postoperative enterocolitis, so that ongoing management of long-term prevention and observational action must still be conducted to combat the risk of enterocolitis.<sup>19,20</sup>

## Conclusion

In our study, we found that a higher diameter of a nerve experiencing hypertrophy is correlated with a greater risk of having HAEC, but this correlation is not sufficiently significant, showing a feeble level of strength.

## Ethical approval

All procedure for this study has been approved by Ethics Commission Faculty of Medicine, Hasanuddin University Number: 265/UN4.6.4.5.31/PP36/2020.

## Consent

The research was conducted ethically in accordance with the World Medical Association Declaration of Helsinki. The patients have given their written informed consent on admission to use their data base and files for research work.

## Authors' contributions

YTP, NM, FNM, UAM, AAZ, UM, TH and MF wrote the manuscript and participated in the study design. YTP, NM, AAZ, UM, TH, and MF drafted and revised the manuscript. YTP, FNM, AW, NM, UM and TH performed the treatment and surgery. YTP, AAZ, MIK, Pri, and MF

performed bioinformatics analyses and revised the manuscript. All authors read and approved the final manuscript.

## Funding

The authors declared that this study has received no financial support.

## Conflicts of interest

The authors declare that they have no conflict of interests.

## References

1. Kessmann J. Hirschsprung's disease: diagnosis and management. *Am Fam Physician* 2006;74:1319–22.
2. Sellers M, Udaondo C, Moreno B, Martínez-Alés G, Díez J, Martínez L, et al. Hirschsprung-associated enterocolitis: observational study in a paediatric emergency care unit. *An Pediatr (English Ed.)* 2018;88:329–34.
3. Gosain A, Frykman PK, Cowles RA, Horton J, Levitt M, Rothstein DH, et al. Guidelines for the diagnosis and management of Hirschsprung-associated enterocolitis. *Pediatr Surg Int* 2017;33:517–21.
4. Dore M, Vilanova Sanchez A, Triana Junco P, Barrena S, De Ceano-Vivas M, Jimenez Gomez J, et al. Reliability of the Hirschsprung-associated enterocolitis score in clinical practice. *Eur J Pediatr Surg* 2019;29:132–7.
5. Demehri FR, Halaweish IF, Coran AG, Teitelbaum DH. Hirschsprung-associated enterocolitis: pathogenesis, treatment and prevention. *Pediatr Surg Int* 2013;29:873–81.
6. Rossi V, Avanzini S, Mosconi M, Mattioli G, Buffa P, Jasonni V, et al. Gastrointestinal digestive system Hirschsprung associated enterocolitis. *Dastrointestinal Dig Syst* 2014;4:1–4.
7. Szyllberg L, Marszałek A. Diagnosis of Hirschsprung's disease with particular emphasis on histopathology. A systematic review of current literature. *Prz Gastroenterol* 2014;9:264–9. <http://dx.doi.org/10.5114/pg.2014.46160>.
8. Zuikova V, Franckevica I, Strumfa I, Melderis I. Immunohistochemical diagnosis of Hirschsprung's disease and allied disorders. *Acta Chir Latv* 2016;15:50–7.
9. Jiang M, Children LY, Tang CS. Immunostaining of rectal suction biopsies in the diagnosis of Hirschsprung. *Am J Transl Res* 2016;8:3159–68.
10. Lawal TA, Chatoorgoon K, Collins MH, Coe A, Peña A, Levitt MA. Redo pull-through in Hirschsprung's disease for obstructive symptoms due to residual aganglionosis and transition zone bowel. *J Pediatr Surg* 2011;46:342–7.
11. Coe A, Collins MH, Lawal T, Loudon E, Levitt MA, Peña A. Reoperation for Hirschsprung disease: pathology of the resected problematic distal pull-through. *Pediatr Dev Pathol* 2012;15:30–8.
12. Kapur RP, Smith C, Ambartsumyan L. Postoperative pullthrough obstruction in Hirschsprung disease: etiologies and diagnosis. *Pediatr Dev Pathol* 2020;23:40–59.
13. Kapur RP. Submucosal nerve diameter of greater than  $40 \mu\text{m}$  is not a valid diagnostic index of transition zone pull-through. *J Pediatr Surg* 2016;51:1585–91.
14. Janssen Lok M, Rassouli-Kirchmeier R, Köster N, Kusters B, De Blaauw I. Development of nerve fibre diameter in young infants with Hirschsprung disease. *J Pediatr Gastroenterol Nutr* 2018;66:253–6.
15. Kapur RP, Arnold MA, Conces MR, Ambartsumyan L, Avansino J, Levitt M, et al. Remodeling of rectal innervation after pullthrough surgery for Hirschsprung disease: relevance to criteria for the determination of retained transition zone. *Pediatr Dev Pathol* 2019;22:292–303.
16. Saad SA, Elseed MMG, AbouZeid AA, Ibrahim EAS, Radwan AB, Hay SA, et al. Histopathological perspective of the pulled-through colon in Hirschsprung disease: impact on clinical outcome. *J Pediatr Surg* 2020;55:1829–33. <http://dx.doi.org/10.1016/j.jpedsurg.2020.01.007>.
17. Serio R, Zizzo MG, Mastropaolo M. The enteric nervous system: new developments and emerging concepts. *Malta Med J* 2011;23:23.
18. Polydorides AD. Hirschsprung disease. In: Greenson JK, Lauwers GY, Polydorides AD, Montgomery EA, Srivastava A, Owens SR, editors. *Diagnostic pathology gastrointestinal*. second ed. Elsevier: Philadelphia; 2016. p. 334–9.
19. Jiao CL, Chen XY, Feng JX. Novel insights into the pathogenesis of Hirschsprung's associated enterocolitis. *Chin Med J (Engl)* 2016;129:1491–7.
20. Cheng S, Wang J, Pan W, Yan W, Shi J, Guan W, et al. Pathologically assessed grade of Hirschsprung-associated enterocolitis in resected colon in children with Hirschsprung's disease predicts postoperative bowel function. *J Pediatr Surg* 2017;52:1776–81.